

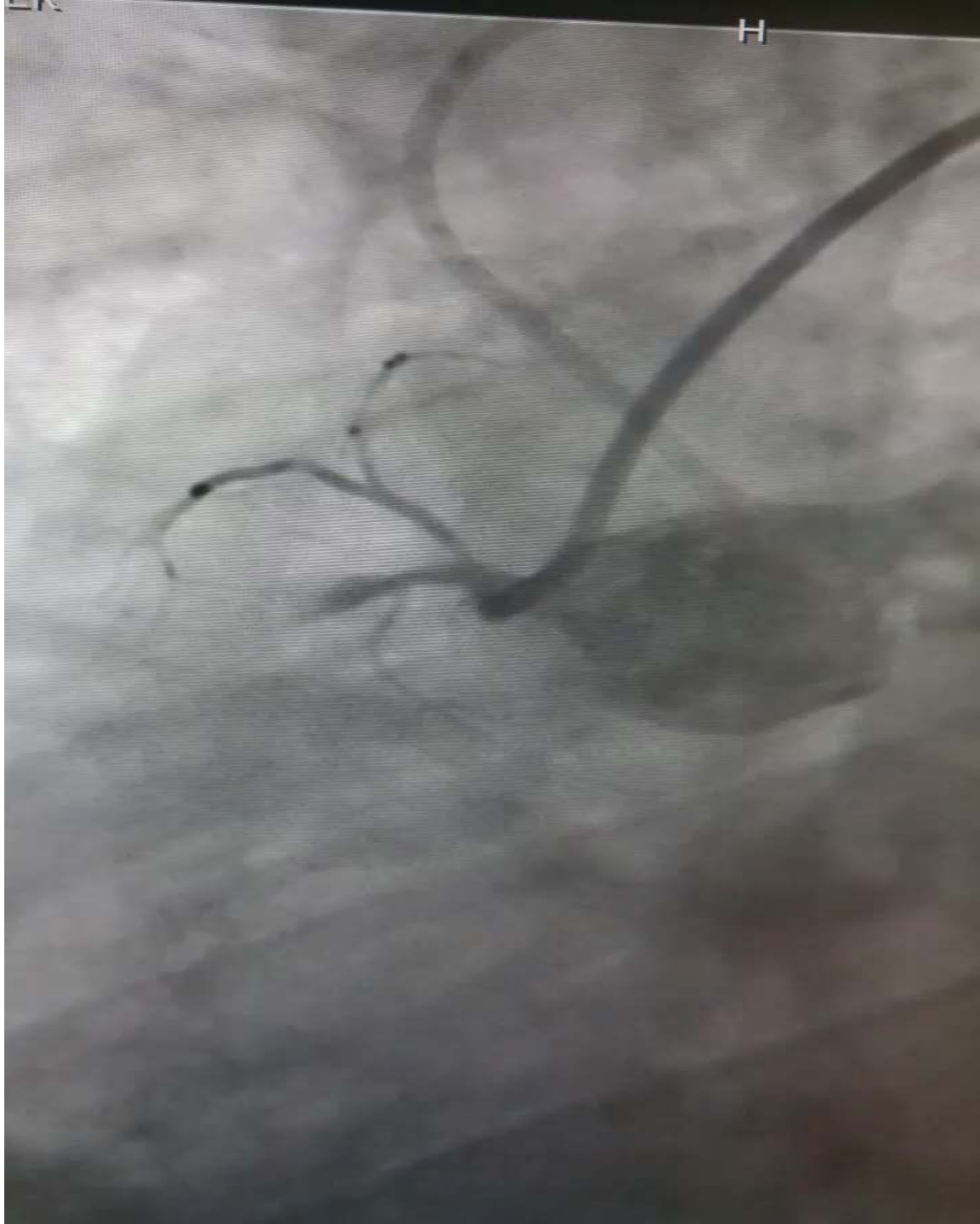KTO 2016

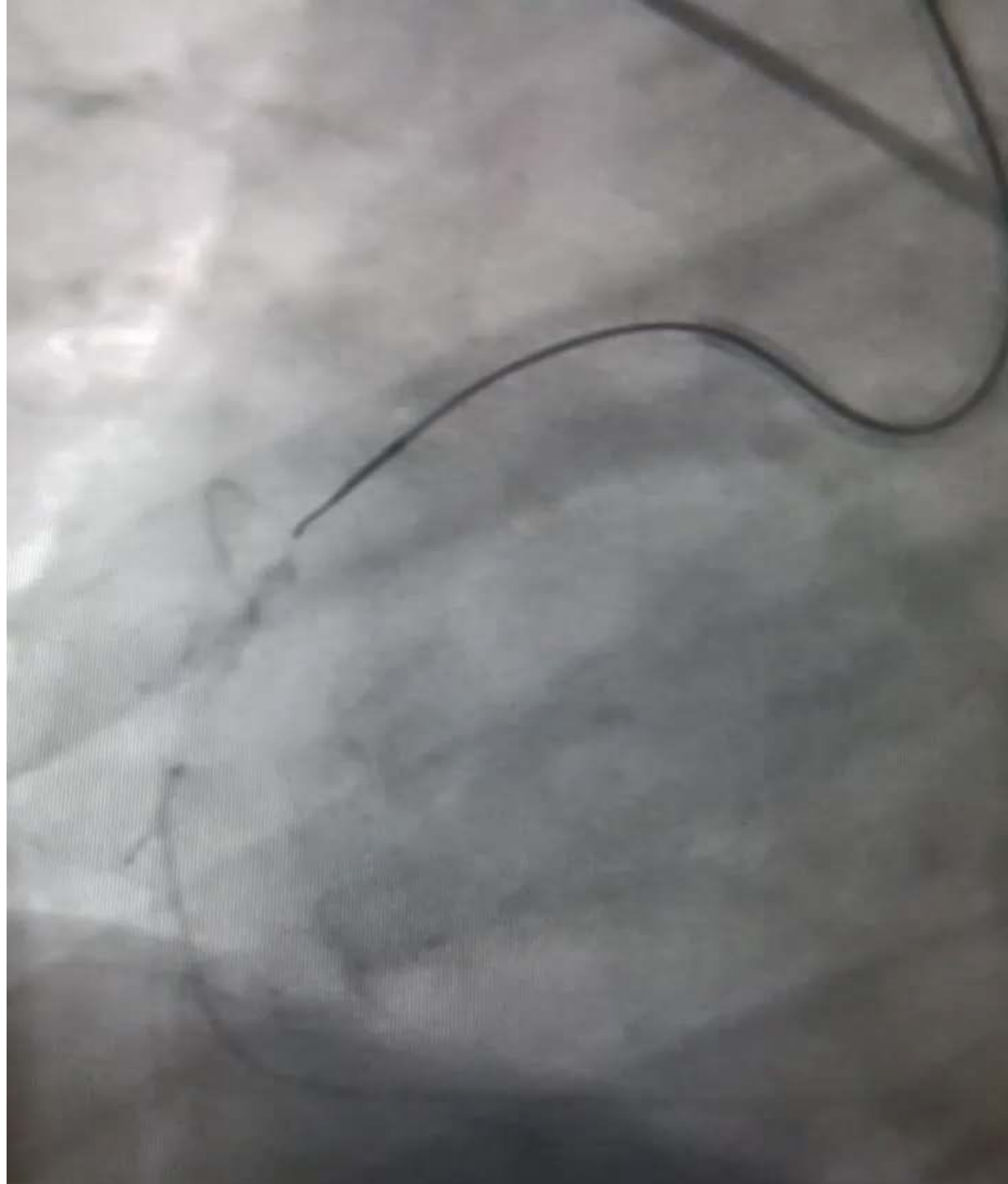


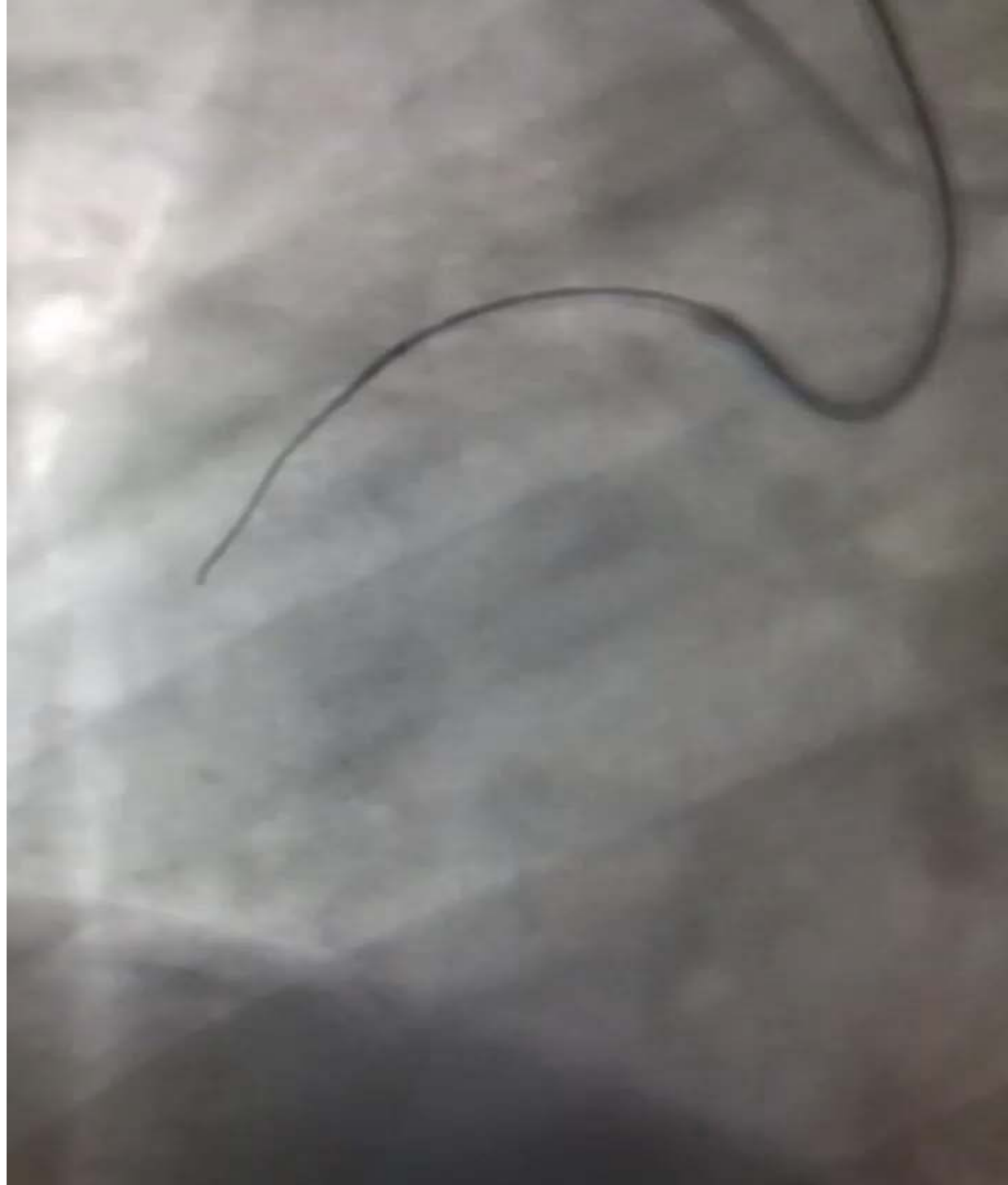ERZİNCAN MENGÜCEK GAZİ EĞİTİM VE ARAŞTIRMA HASTANESİ

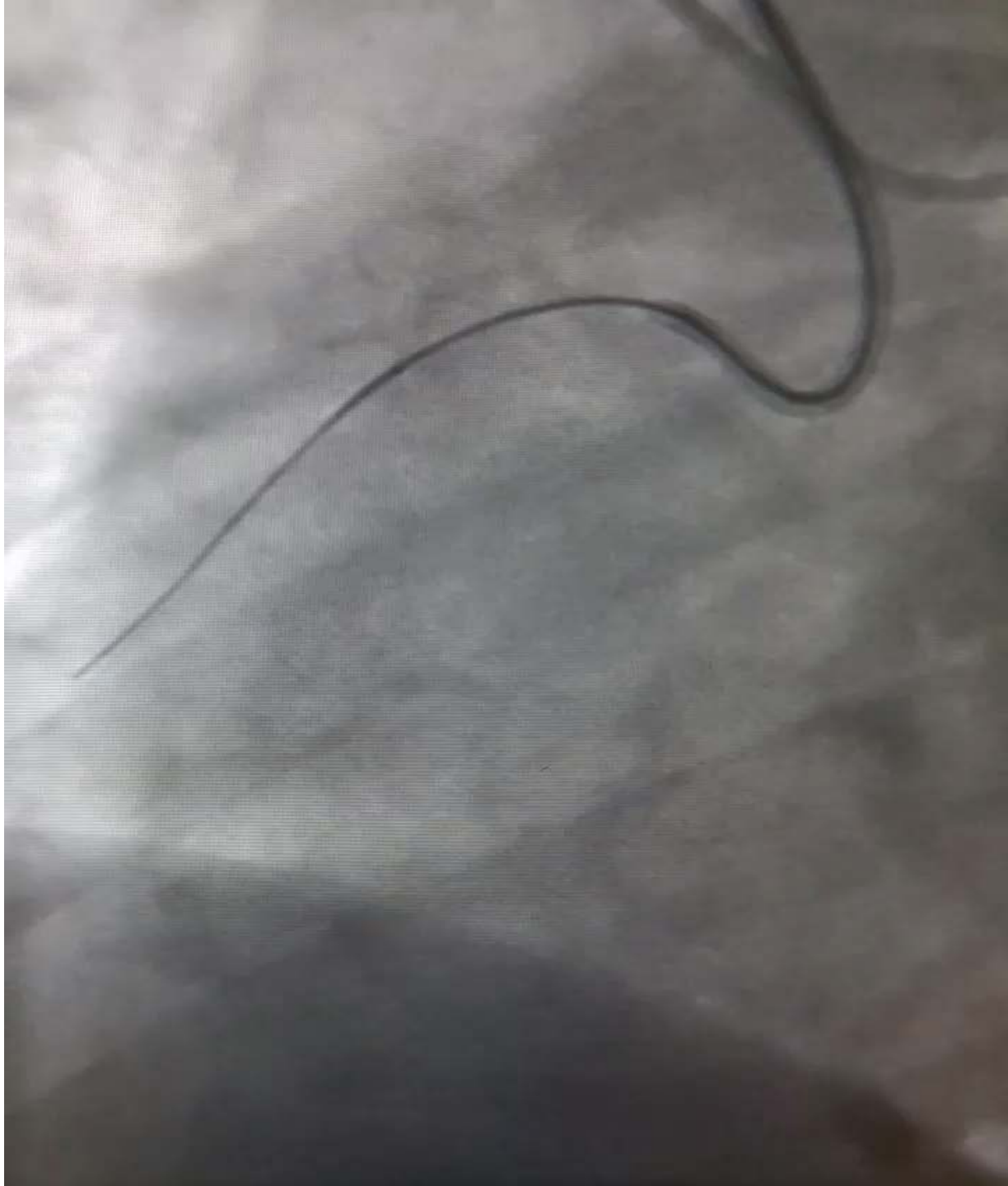
DR ZAFER KÜÇÜKSU

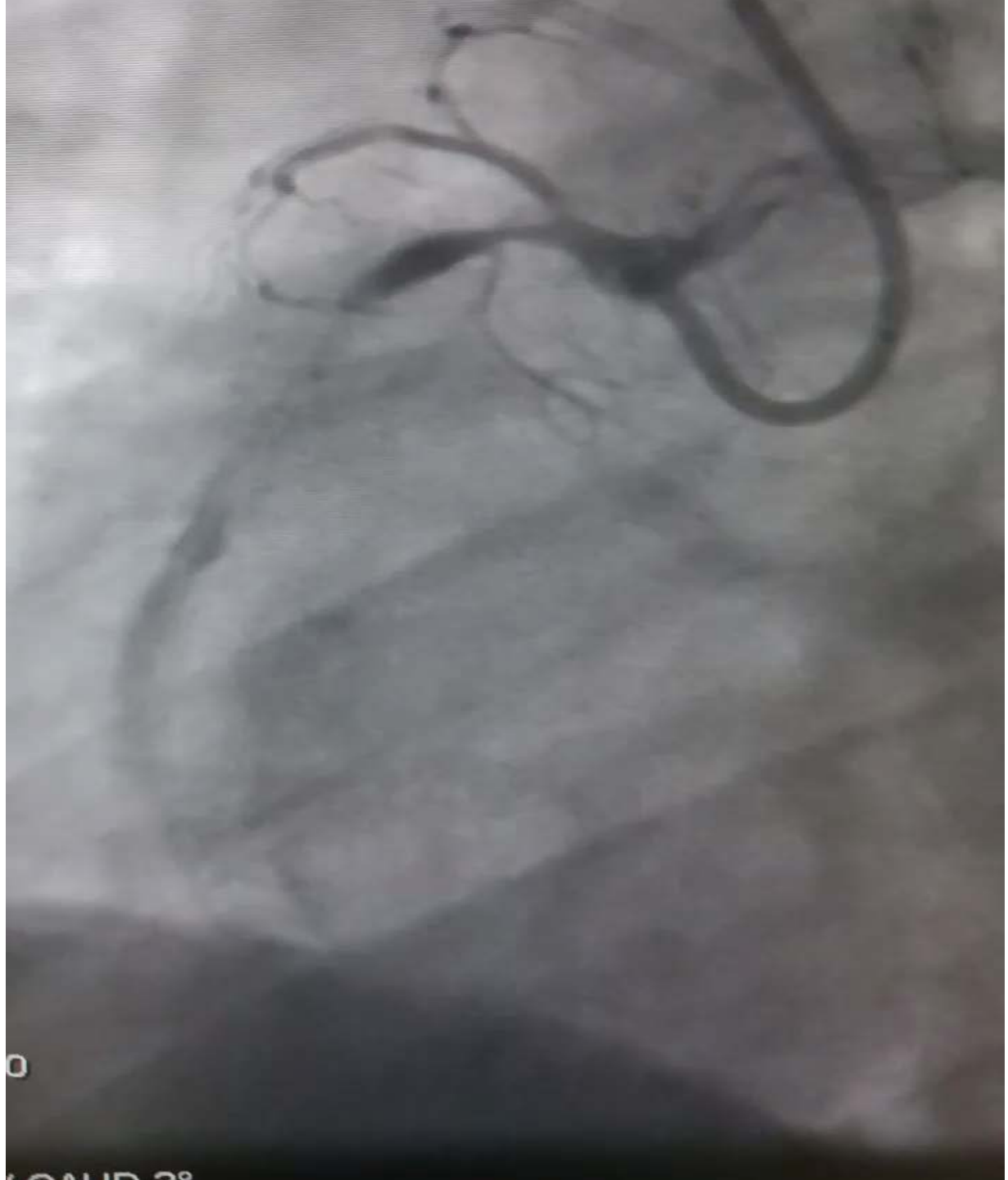
-
- 60 yaşında erkek hasta
 - Hipertansiyon, sigara
 - Cx stentli
 - Stabil angina
 - KAG de LAD plak CX stent açık RCA kronik total ve retrograd doluşu mevcut





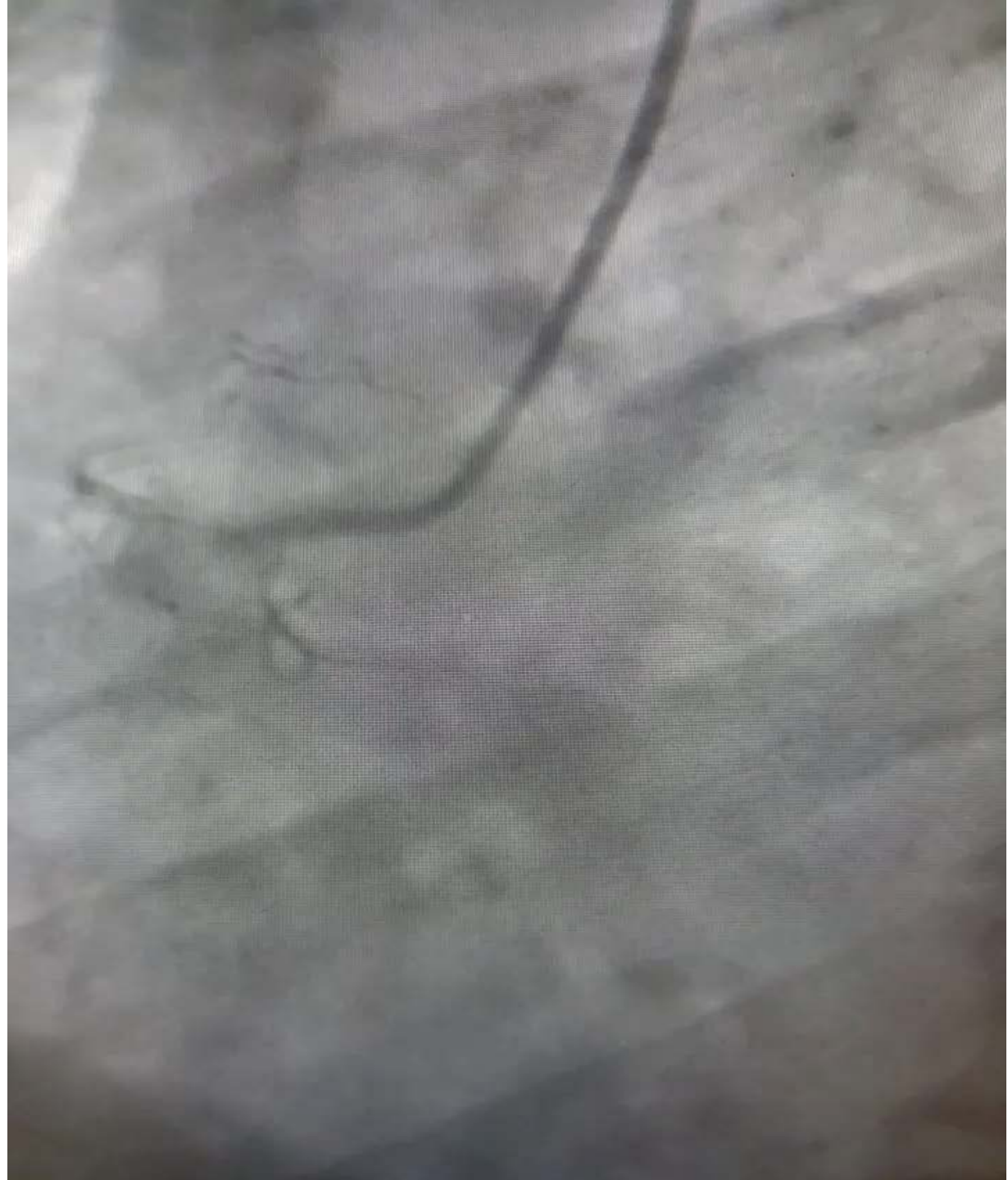


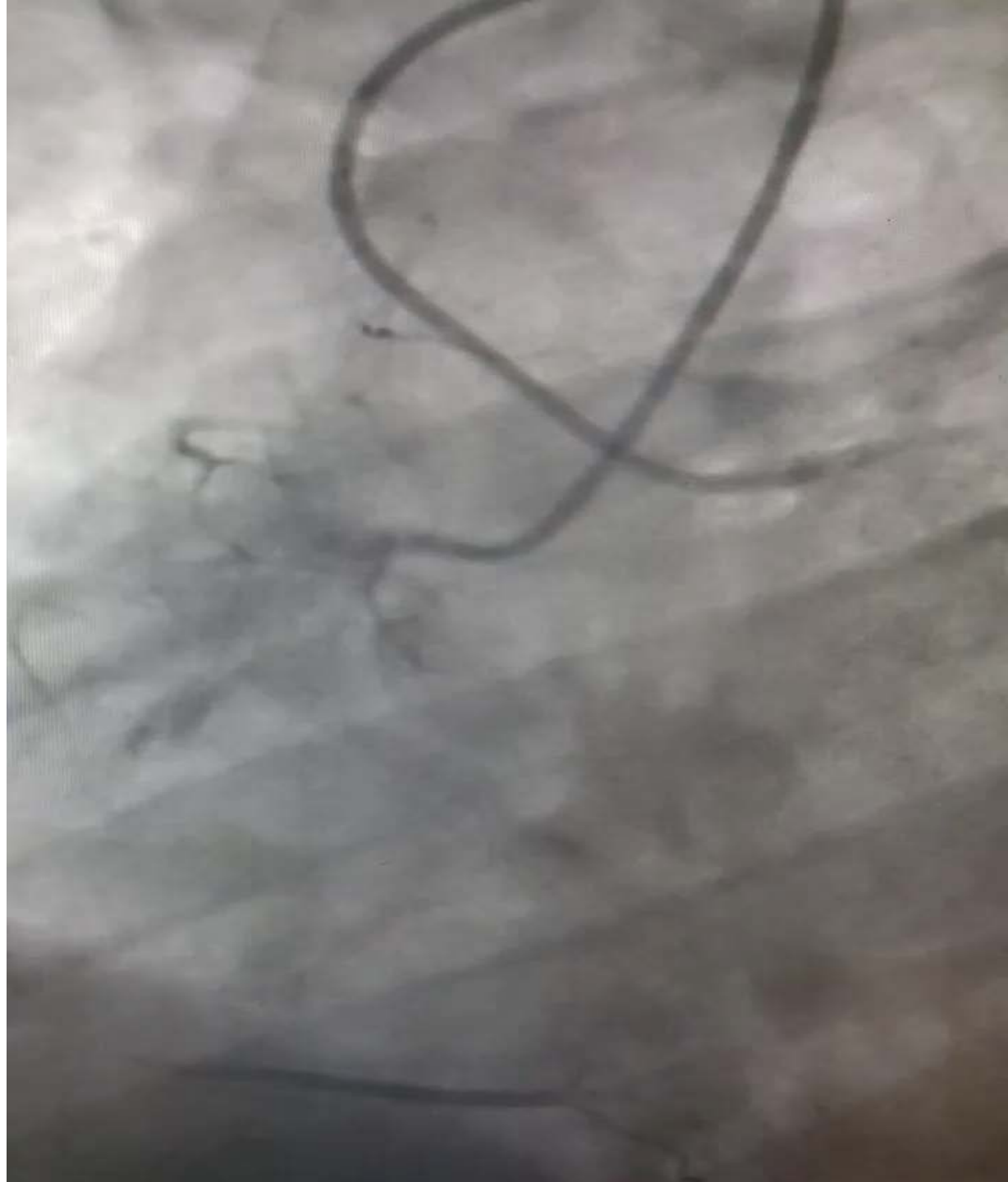


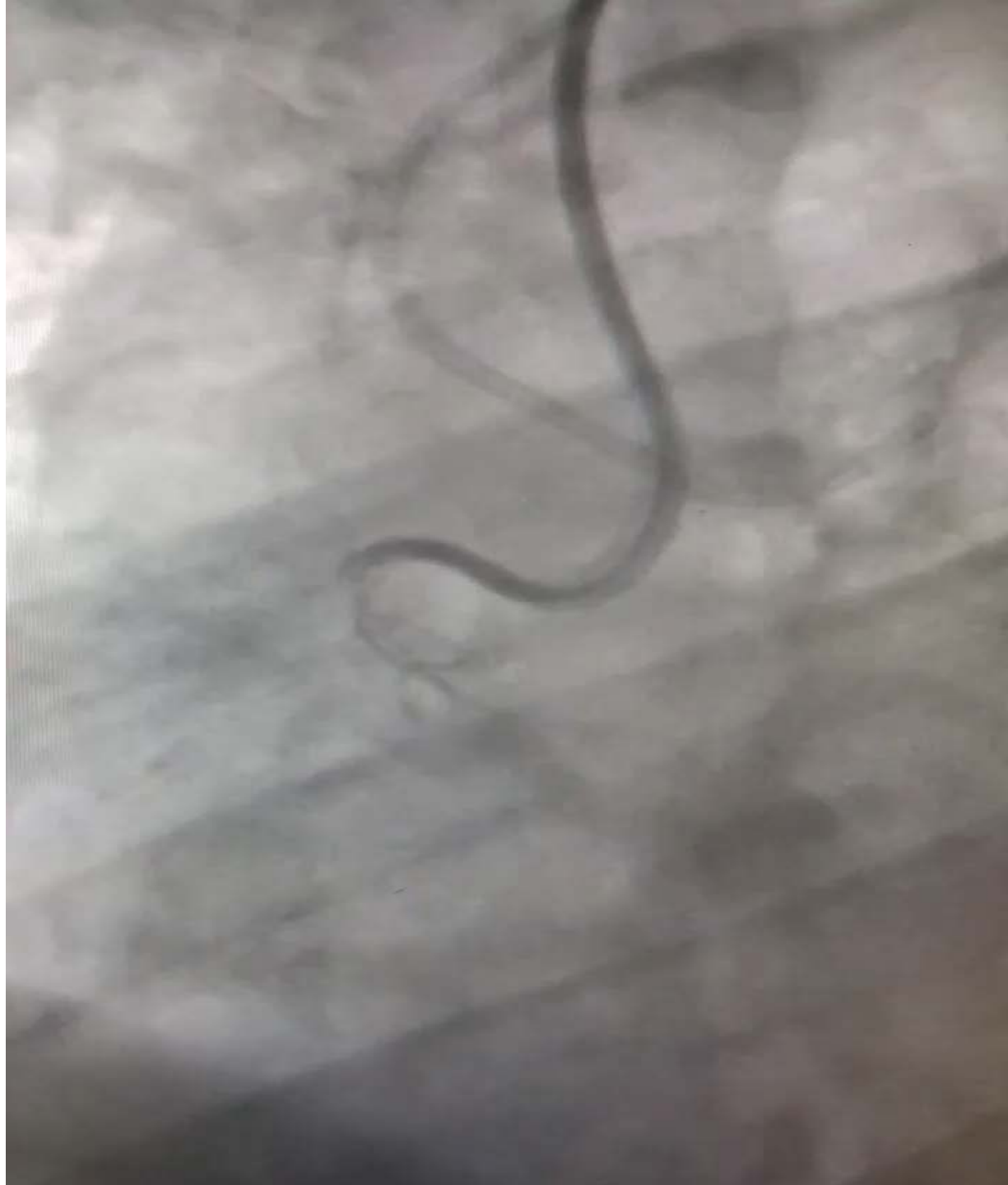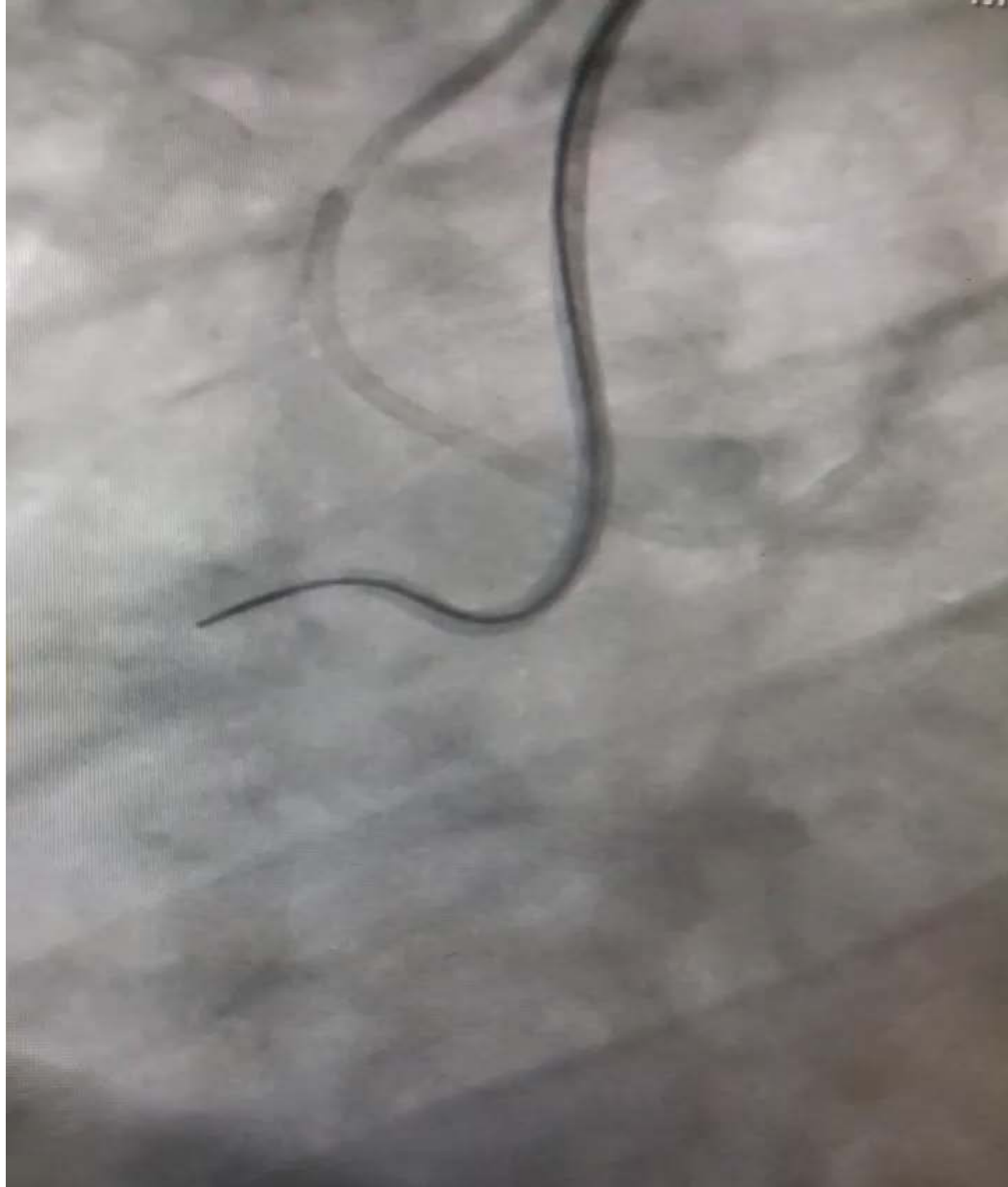0

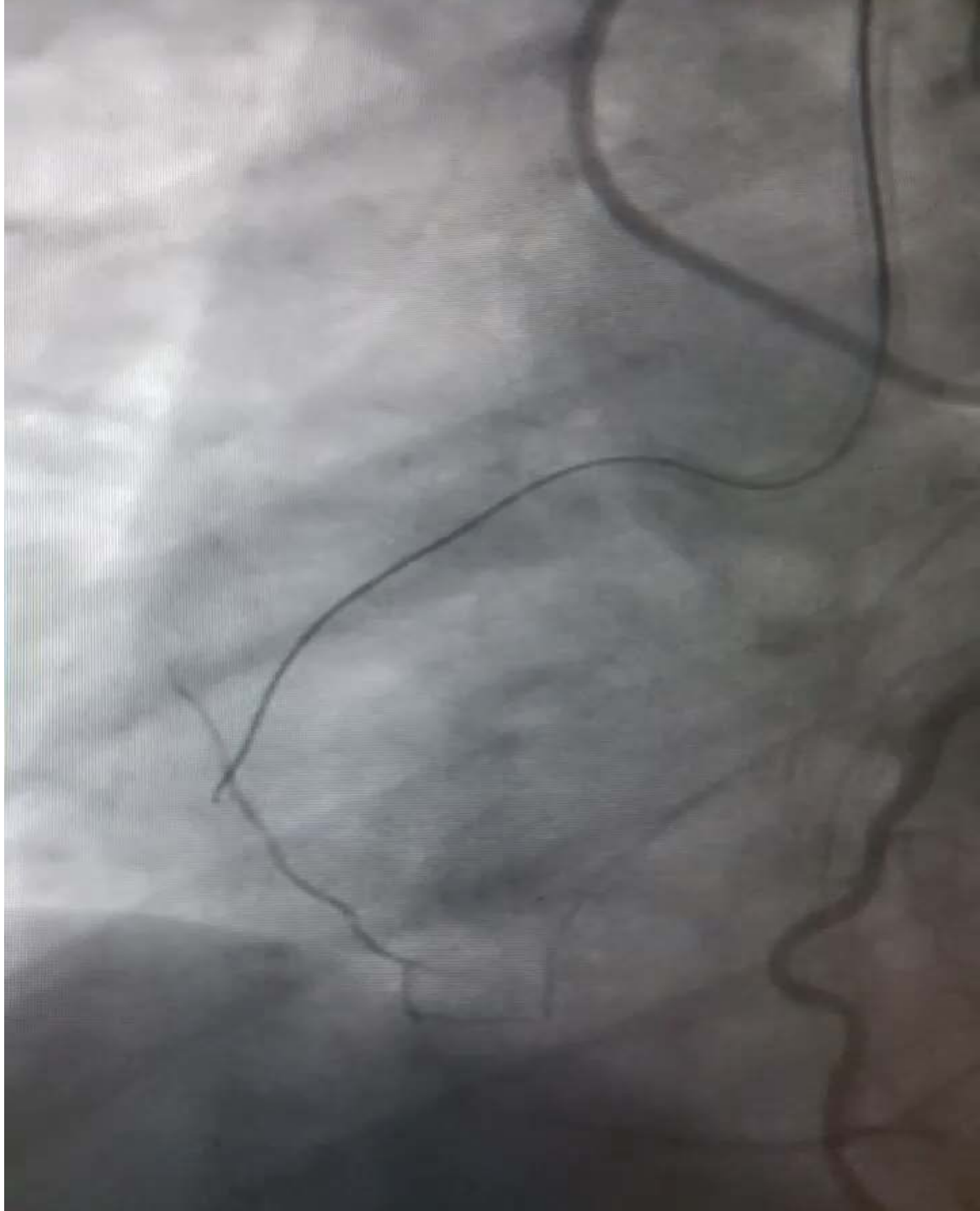
LOAD 38

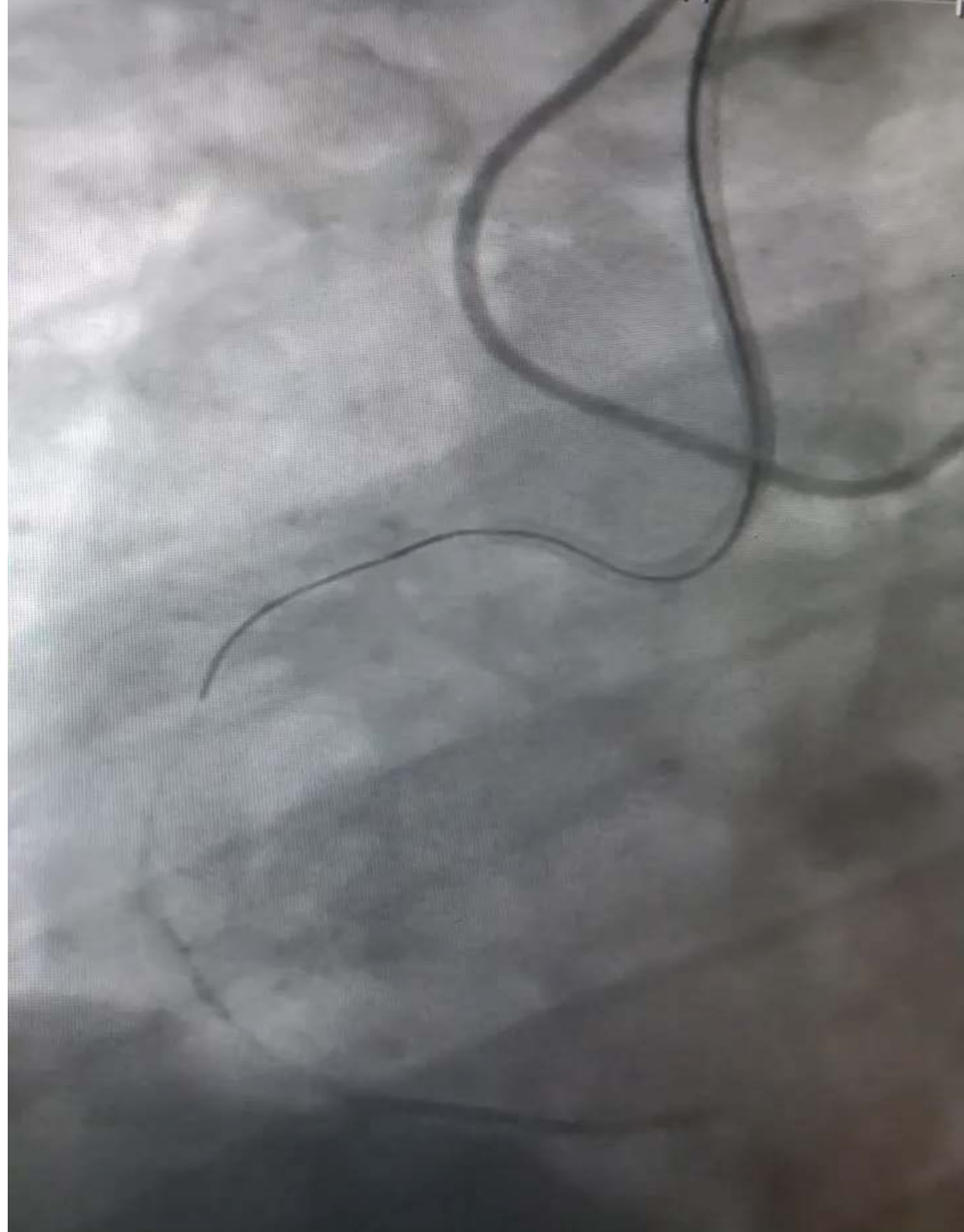


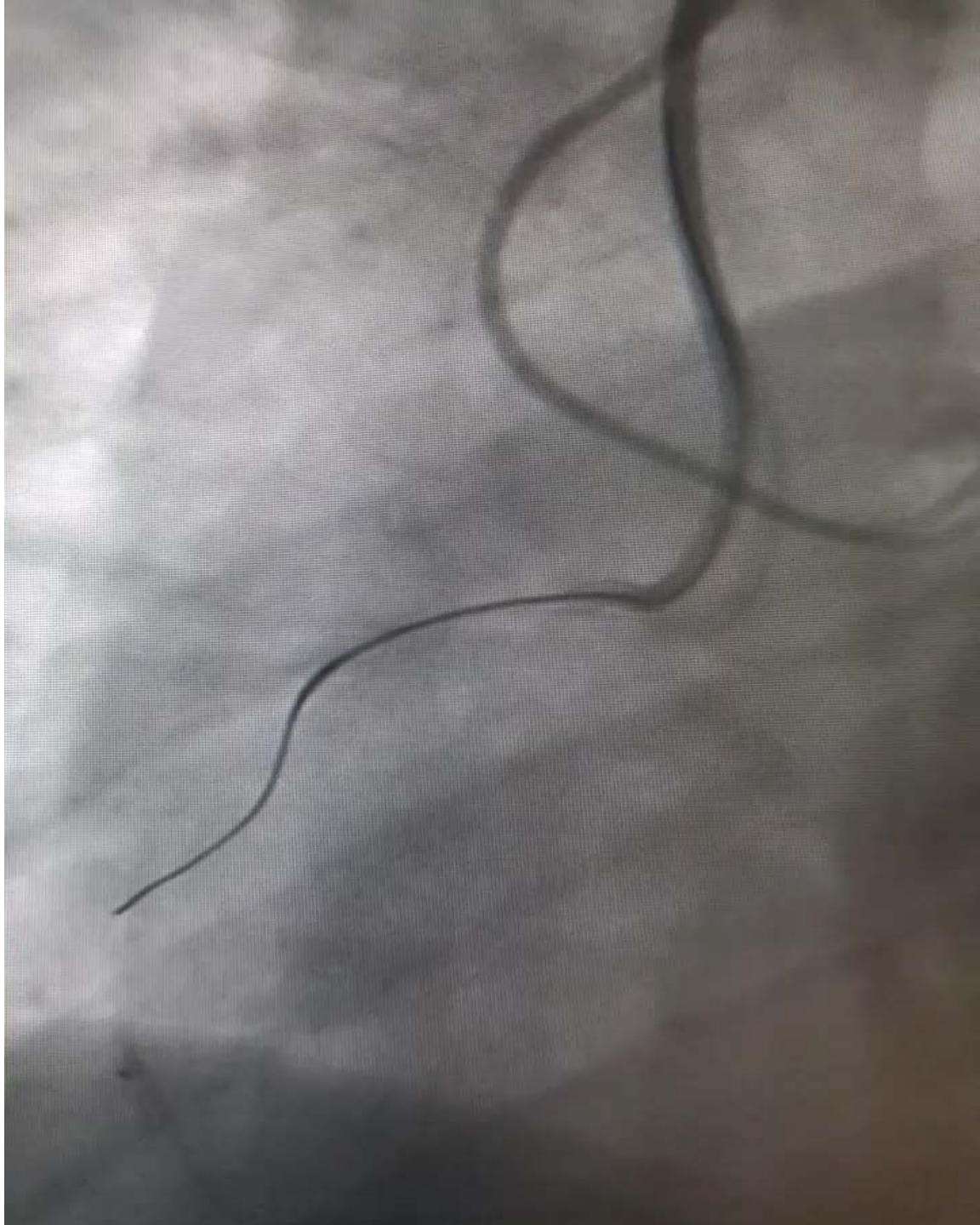


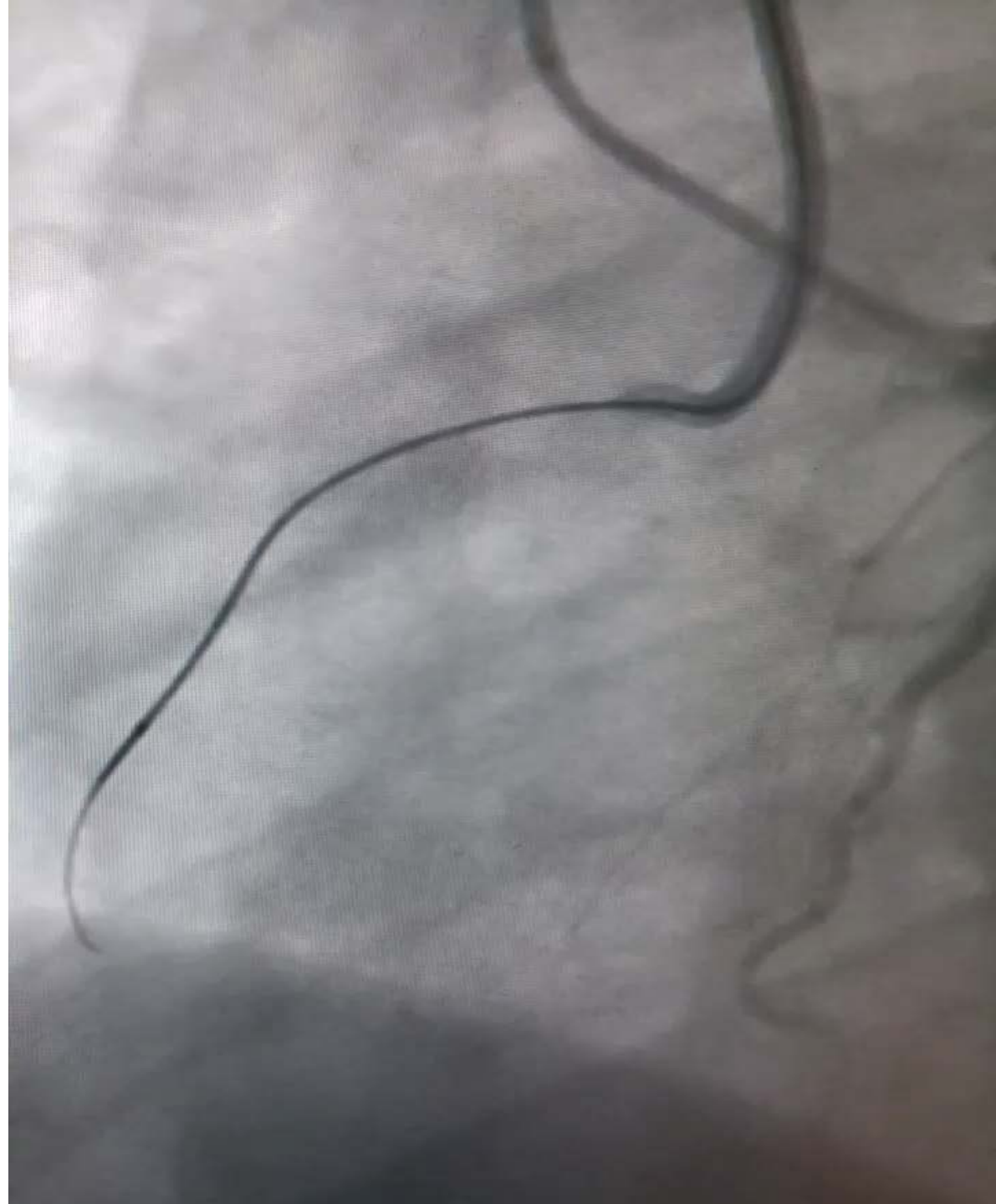












STAR TEKNIĞI



L. SIMSEK

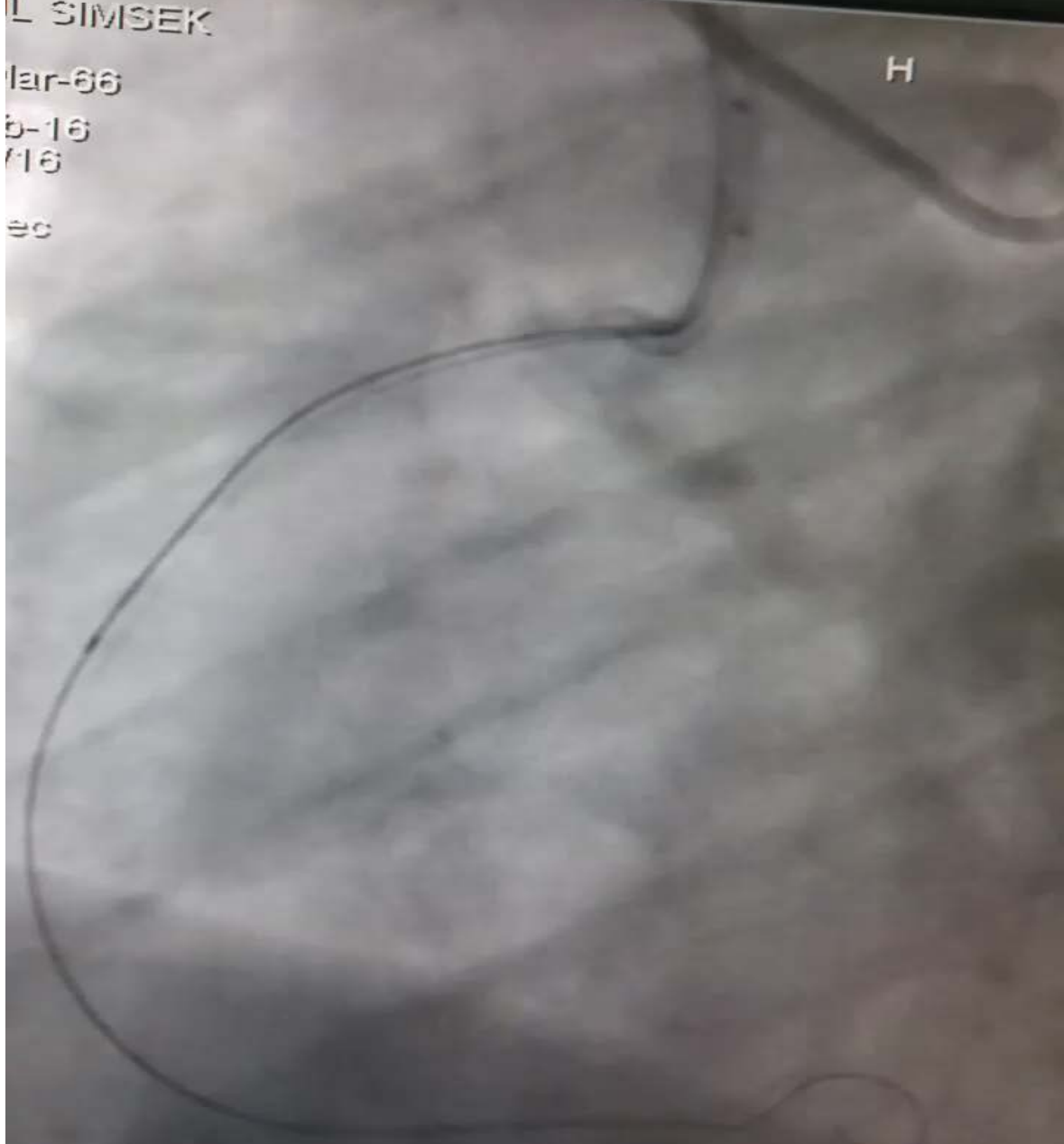
lar-66

6-16

16

ec

H



7201
* 01-Mar-86
22-Feb-16
15 - 3/3
0.13 sec

H

0000

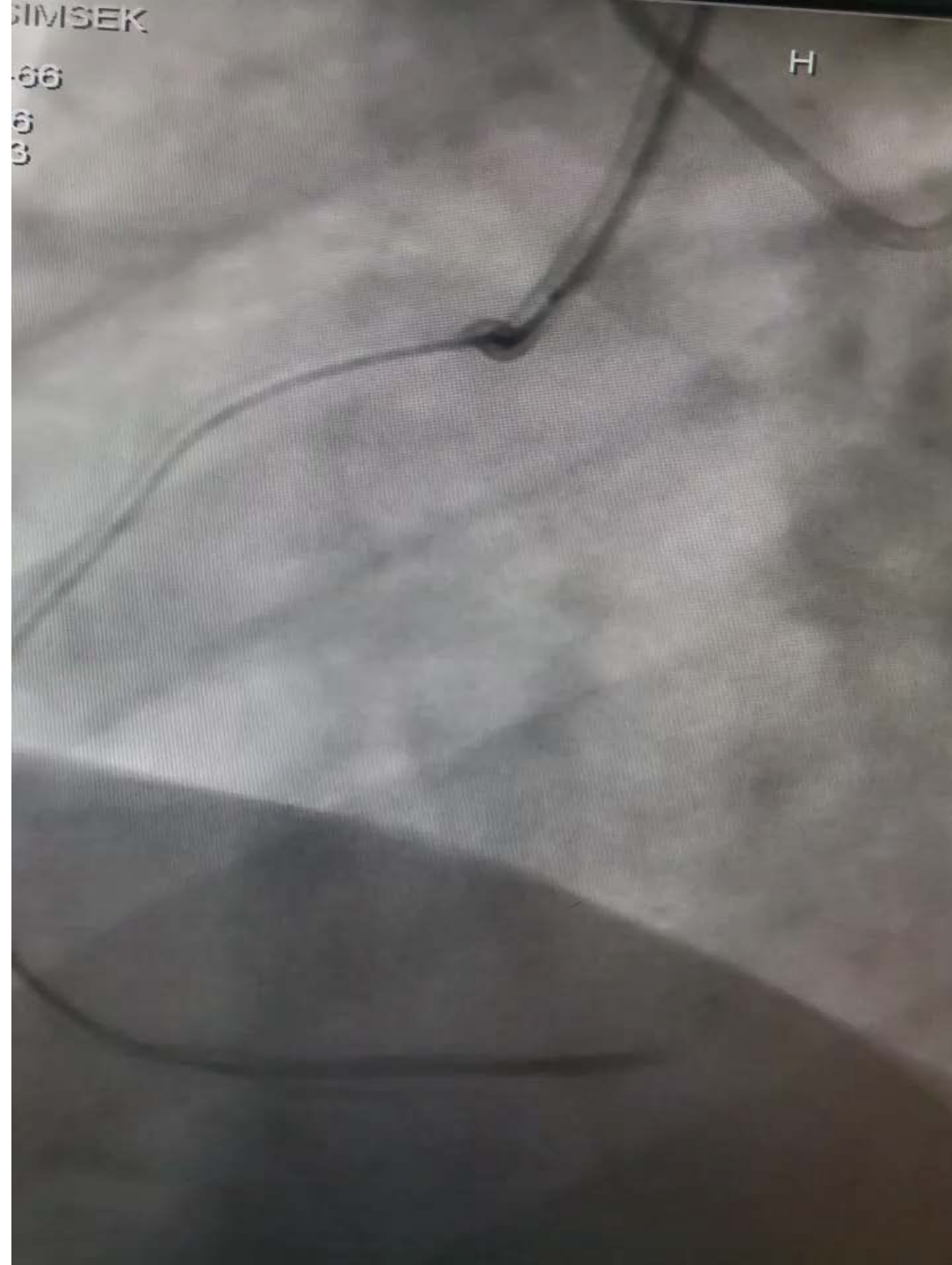
SIMSEK

66

6

6

H



Mar-66

eb-16

1/12

sec

2020

MUL SIMSEK

Mar-66

Feb-16
15/21

sec

H

020

1-Mar-66

Feb-16

- 4/15

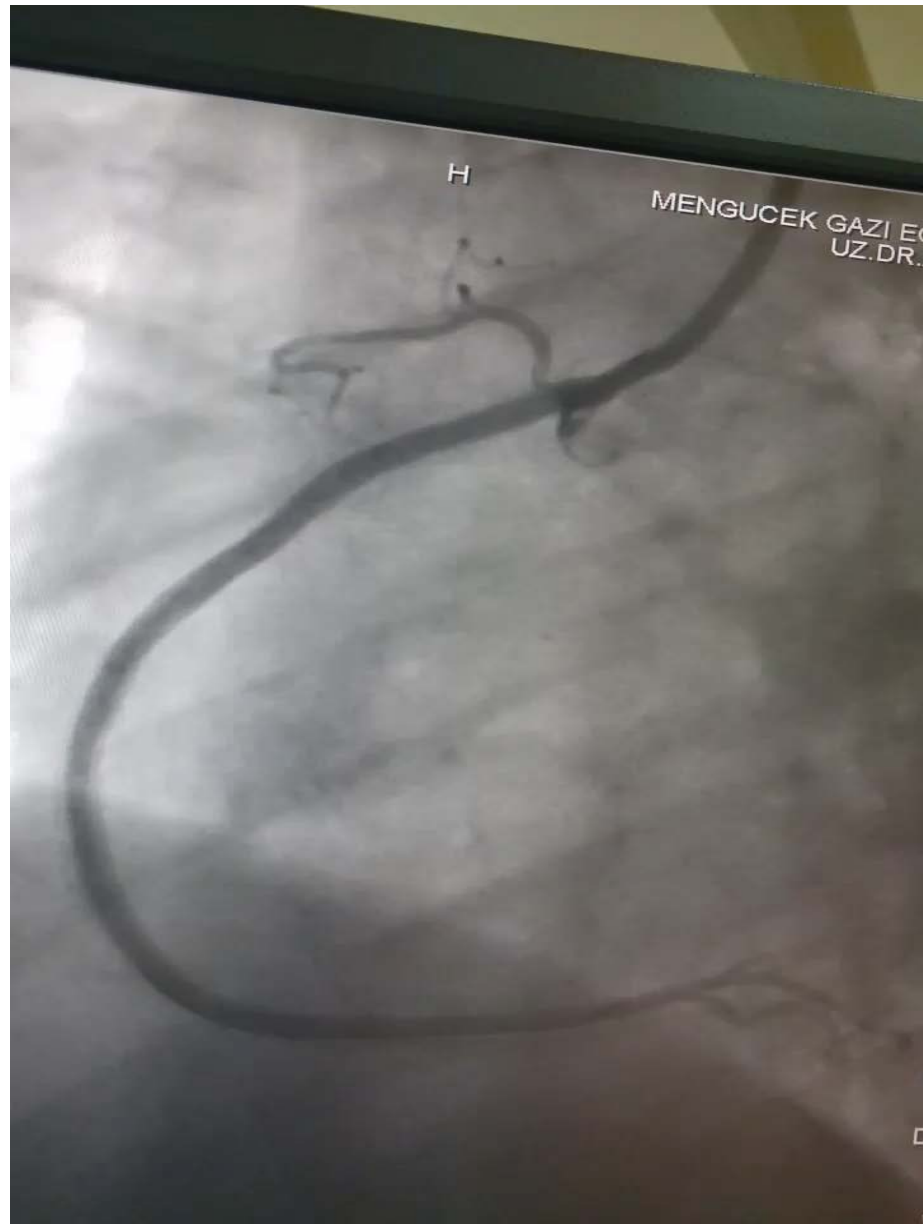0 sec

2020

H

MENGUCEK G

L



L SIMSEK

lar-66

6-16

5/43

ec

H

20

