

Olgu Sunu-1

AKS'li ve Koroner Bypass'lı hastada koroner girişim

Doç Dr Nihat Kalay
Erciyes Üniversitesi Tıp Fakültesi
Kardiyoloji ABD

D.S

77 Yaşında erkek hasta

15 yıl önce CABG +

AKS ile üniversite hastanesinde KYBÜ takip edilmiş

KAG de SAFEN- RCA anostomuzunda yaygın trombus ve stenozlar tespit edilmiş

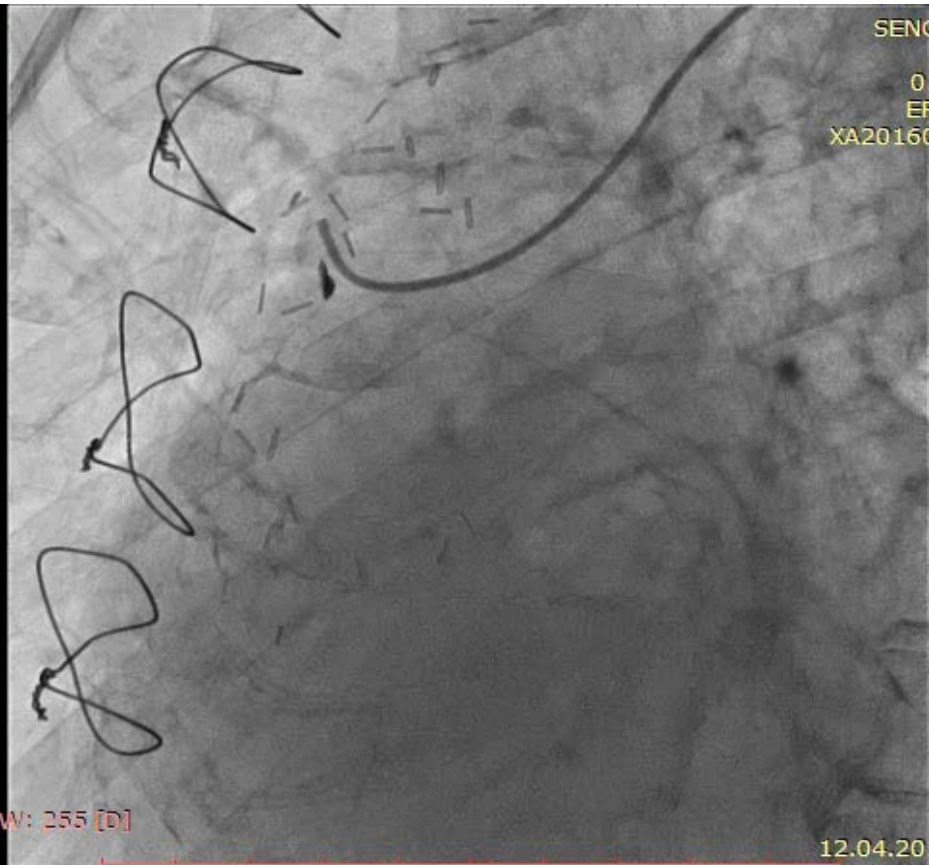
Gpllb IIIa infuzyon

Hastanemize Safen-RCA anostomoz PCI için gönderildi

- Sınıf 3 angina +
- EF % 45
- Troponin +
- Kreatin: 0:66
- GFR: 93 ml/dk

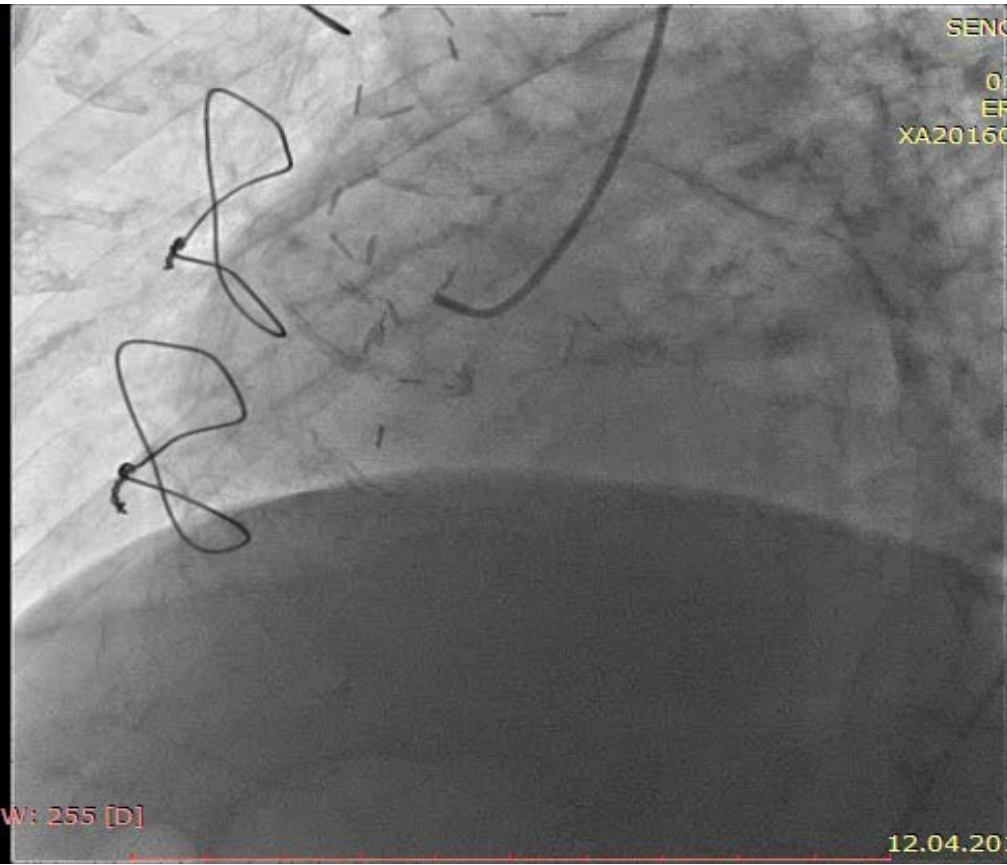
PCI

Im: 1/105
Se: 1



SENGEL DURSUN
16/8421
01.01.1957 M
ERCIYES Univ.
XA20160412133405

Im: 1/101
Se: 3



SENGEL DURSUN
16/8421
01.01.1957 M
ERCIYES Univ.
XA20160412133405

WL: 128 WW: 255 [D]
LAO: 60

12.04.2016 13:44:13

WL: 128 WW: 255 [D]
LAO: 60

12.04.2016 13:47:19

PCI

Safen-RCA

Teknik kolay

Risk ↑↑↑↑

RCA CTO

Teknik zor

Risk ↑

m: 1/69
e: 4

SENGEL DURSUN
16/8421
01.01.1957 M
ERCIYES Univ.
XA20160412133405

Im: 1/69
Se: 4

SENGEL DURSUN
16/8421
01.01.1957 M
ERCIYES Univ.
XA20160412133405

WL: 128 WW: 255 [D]
LAO: 60

12.04.2016 14:07:58

WL: 128 WW: 255 [D]
LAO: 60

12.04.2016 14:07:58

m: 1/89
e: 5

SENGEL DURSUN
16/8421
01.01.1957 M
ERCIYES Univ.
XA20160412133405

Im: 1/60
Se: 8

SENGEL DURSUN
16/8421
01.01.1957 M
ERCIYES Univ.
XA20160412133405

WL: 128 WW: 255 [D]
LAO: 60

12.04.2016 14:11:36

WL: 128 WW: 255 [D]
LAO: 60

12.04.2016 14:23:13

Se: 9

16/8421
01.01.1957 M
ERCIYES Univ.
XA20160412133405

Se: 11

16/8421
01.01.1957 M
ERCIYES Univ.
XA20160412133405

WL: 128 WW: 255 [D]
LAO: 60

12.04.2016 14:25:23

WL: 128 WW: 255 [D]
LAO: 60

12.04.2016 14:26:41

Im: 1/44
Se: 14

SENGEL DURSUN
16/8421
01.01.1957 M
ERCIYES Univ.
XA20160412133405

Im: 1/26
Se: 16

SENGEL DURSUN
16/8421
01.01.1957 M
ERCIYES Univ.
XA20160412133405

WL: 128 WW: 255 [D]
LAO: 60

12.04.2016 14:29:16

WL: 128 WW: 255 [D]
LAO: 60

12.04.2016 14:32:54

Se: 16

16/8421
01.01.1957 M
ERCIYES Univ.
XA20160412133405

Se: 19

16/8421
01.01.1957 M
ERCIYES Univ.
XA20160412133405

WL: 128 WW: 255 [D]
LAO: 60

12.04.2016 14:32:54

WL: 128 WW: 255 [D]
LAO: 60

12.04.2016 14:45:11

Im: 1/48
Se: 21

SENGEL DURSUN
16/8421
01.01.1957 M
ERCIYES Univ.
XA20160412133405

Im: 1/17
Se: 27

SENGEL DURSUN
16/8421
01.01.1957 M
ERCIYES Univ.
XA20160412133405

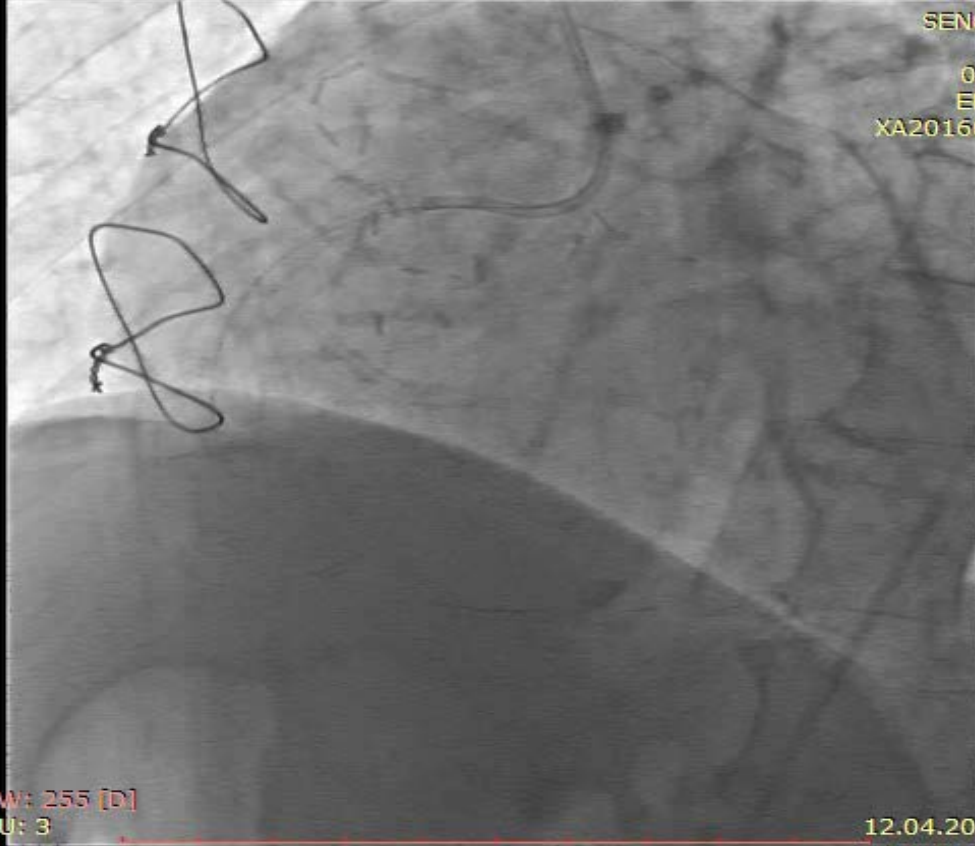
WL: 128 WW: 255 [D]
LAO: 60

12.04.2016 14:47:2

WL: 128 WW: 255 [D]
LAO: 47 CAU: 3

12.04.2016 15:13:08

Im: 1/65
Se: 28

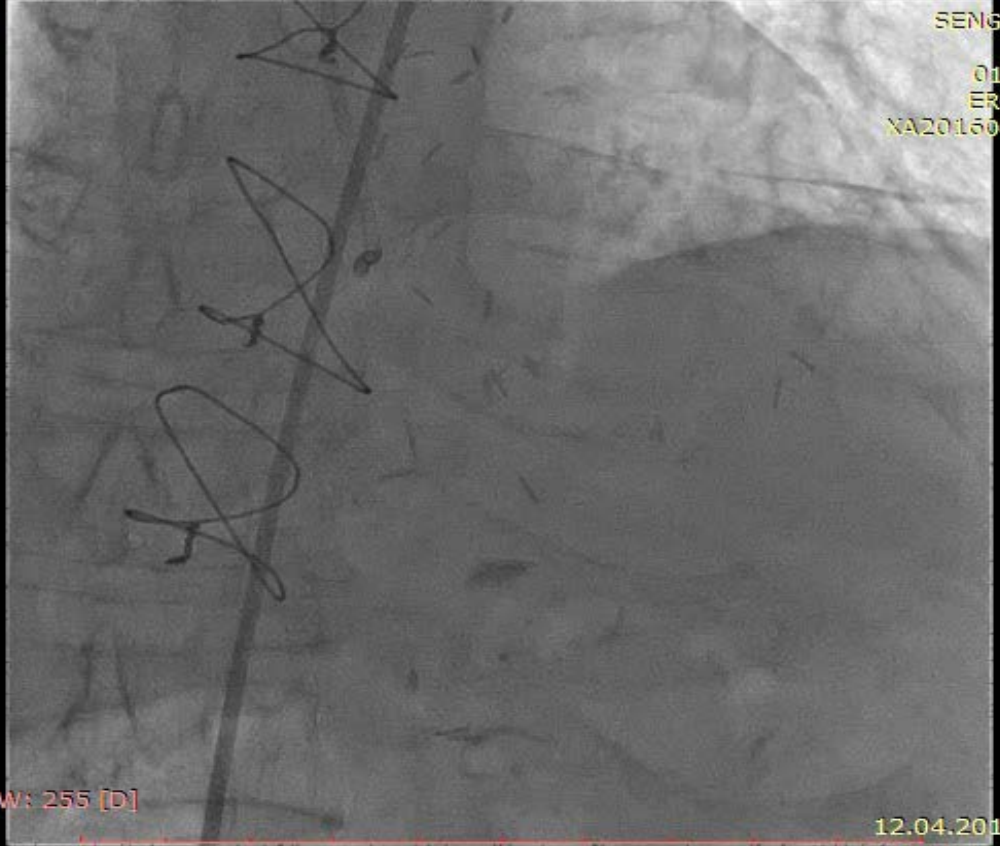


WL: 128 WW: 255 [D]
LAO: 47 CAU: 3

SENGEL DUR: Im: 1/111
16/8 Se: 29
01.01.195
ERCIYES U
XA20160412133

12.04.2016 15:16:26

WL: 128 WW: 255 [D]



SENGEL DURSUN
16/8421
01.01.1957 M
ERCIYES Univ.
XA20160412133405

12.04.2016 15:16:42

2. işlem

Im: 1/50
Se: 4

SEGGEL DURSUN
16/8447
01.01.1939 M
ERCIYES Univ.
XA20160415120304

Im: 1/9
Se: 8

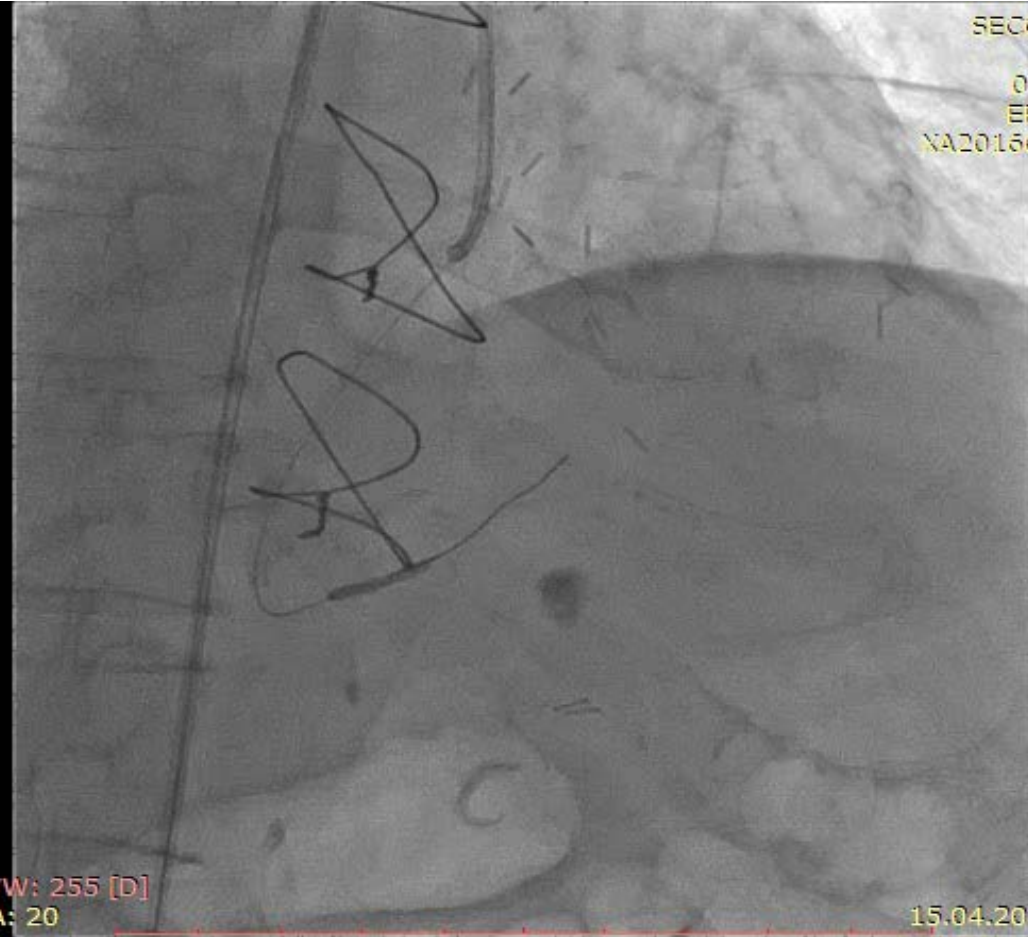
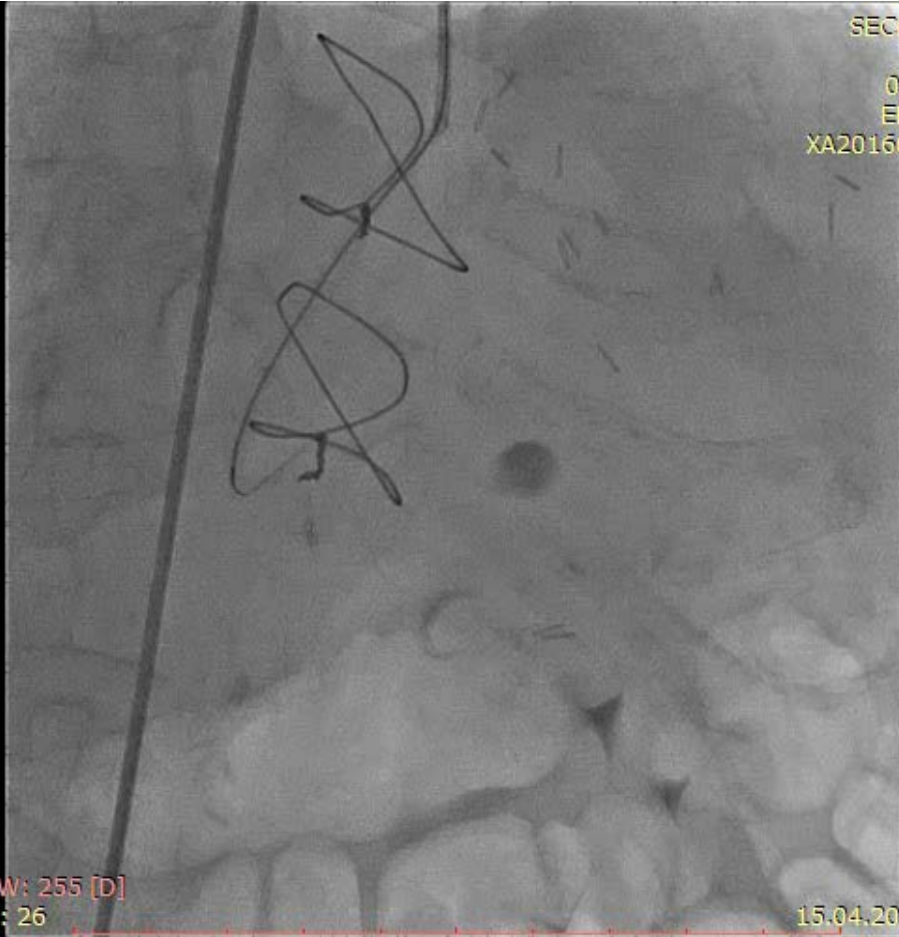
WL: 128 WW: 255 [D]
RAO: 8 CRA: 26

15.04.2016 13:20:28

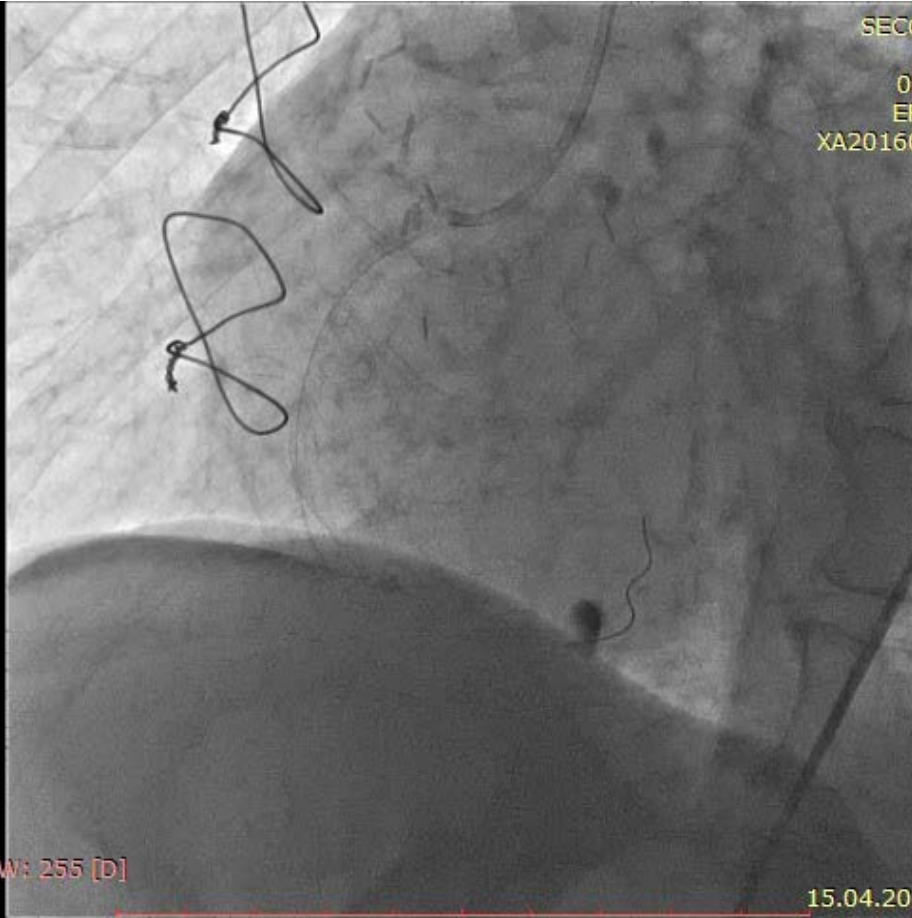WL: 128 WW: 255 [D]
RAO: 5 CRA: 20

15.04.2016 13:34:59

SEGGEL DURSUN
16/8447
01.01.1939 M
ERCIYES Univ.
XA20160415120304



Im: 1/40
Se: 12

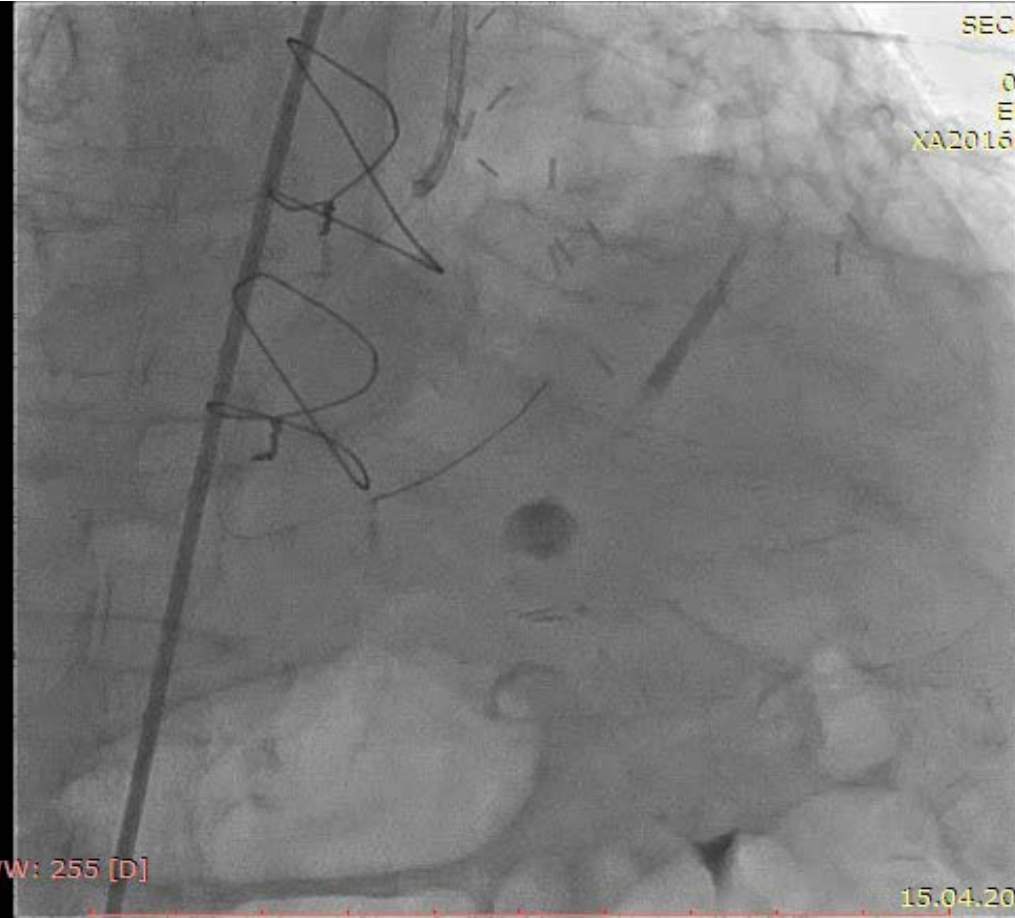


SEGGEL DURSUN
16/8447
01.01.1939 M
ERCIYES Univ.
XA20160415120304

WL: 128 WW: 255 [D]
LAO: 54

15.04.2016 13:39:00

Im: 1/65
Se: 13



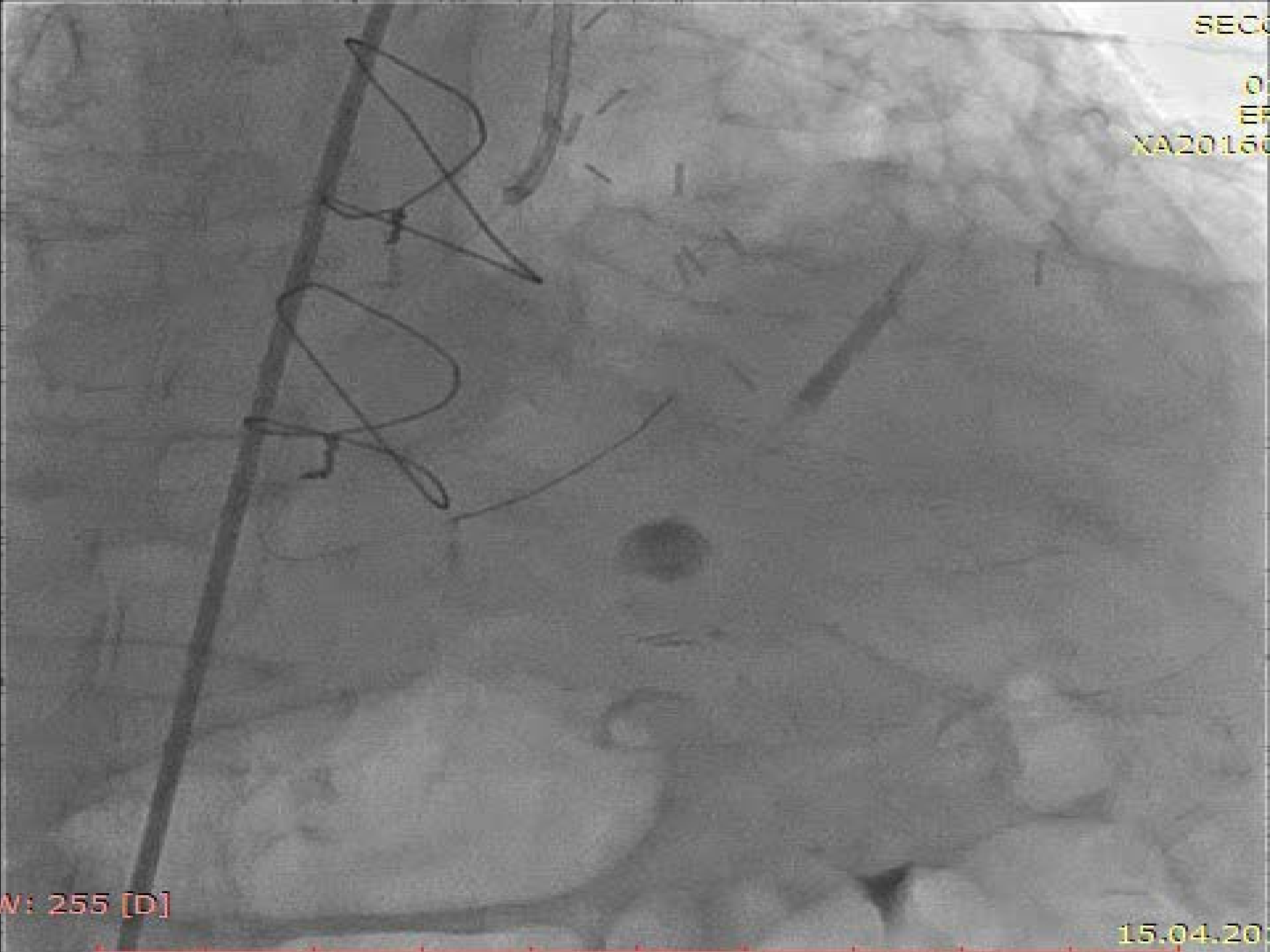
SEGGEL DURSUN
16/8447
01.01.1939 M
ERCIYES Univ.
XA20160415120304

WL: 128 WW: 255 [D]
CRA: 26

15.04.2016 13:39:16

Im: 1/65
Se: 13

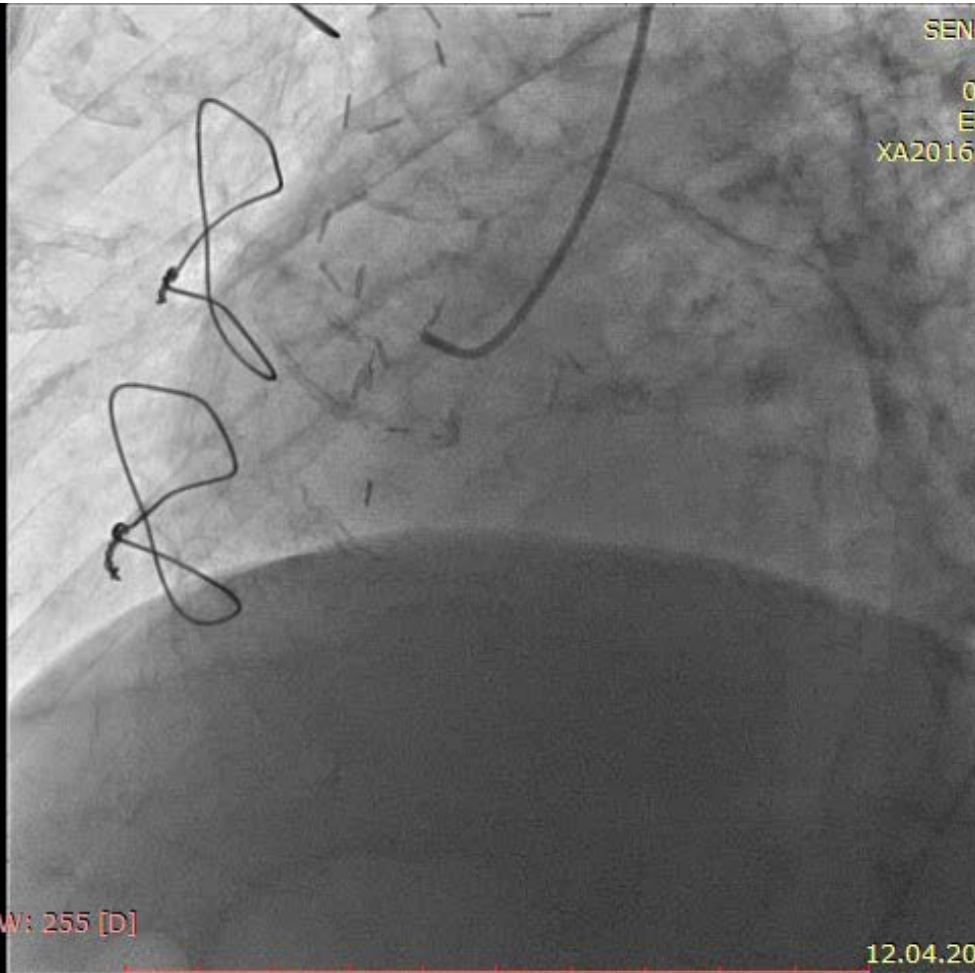
SEGGEL DURSUN
16/8447
01.01.1939 M
ERCIYES Univ.
XA20160415120304



WL: 128 WW: 255 [D]
CRA: 26

15.04.2016 13:39:16

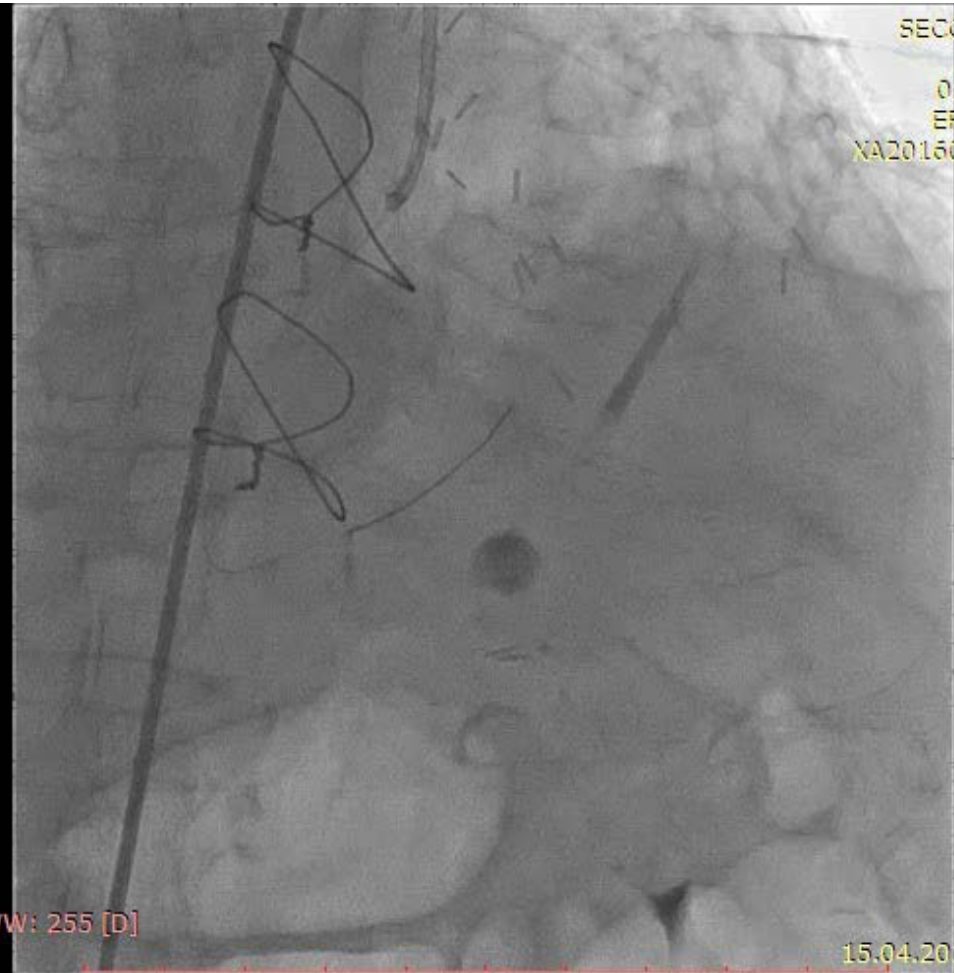
Im: 1/101
Se: 3



WL: 128 WW: 255 [D]
LAO: 60

SENGEL DURSUN Im: 1/65
16/8421 Se: 13
01.01.1957 M
ERCIYES Univ.
XA20160412133405

12.04.2016 13:47:19 CRA: 26



SEGGEL DURSUN
16/8447
01.01.1939 M
ERCIYES Univ.
XA20160415120304

WL: 128 WW: 255 [D]
CRA: 26

15.04.2016 13:39:16

Çok eski CTO müdahale

Nativ damar & Bypass

2. lezyona müdahale

Distal lezyona stent



Teşekkürler...