

# Başarılı LAD Retrograd KTO

---

DR.MUSTAFA YAZICI

DR.GÖKSEL DAĞAŞAN

---

S K

50 yaşıında erkek hasta.

4 yıldır hipertansiyon, 2 yıldır diabet sebebi ile takipli,

60 paket/ yıl sigara kullanım öyküsü mevcut.

2012 yılında CX mid bölgeye stent implantasyonu yapılmış.



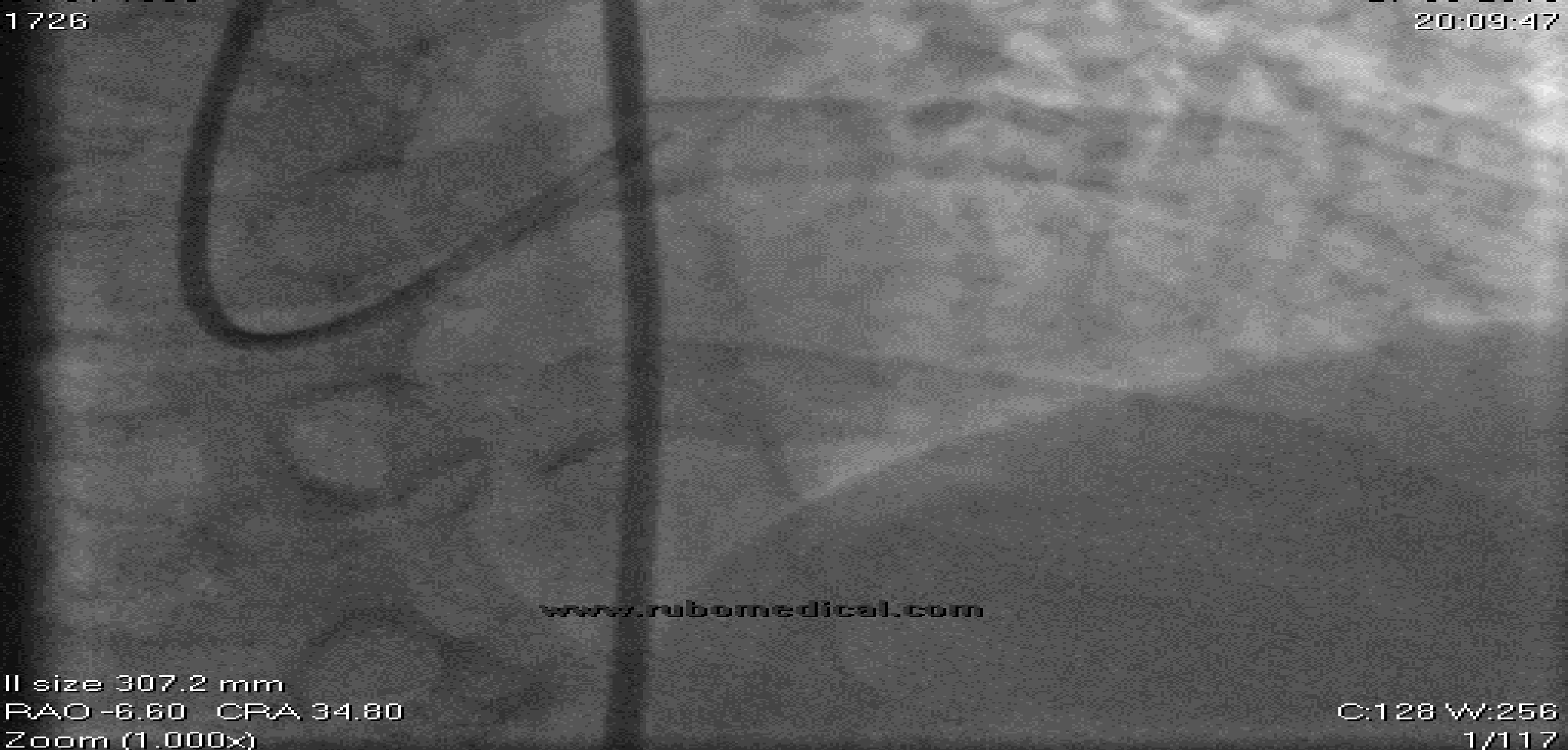---

Son 3 aydır istirahat halinde eforla ilişkisiz göğüs ağrısı şikayeti mevcut.

2 ay ve 2 hafta önce antegrad yol kullanılarak başarısız CTO girişimi denenmiş.

Hasta mevcut şikayetler ile kliniğimize başvurdu.

Retrograd CTO girişimi yapılmak üzere katater laboratuvarına alındı.



[www.rubomedical.com](http://www.rubomedical.com)

Il size 307.2 mm  
RAO -6.60 CRA 34.80  
Zoom (1.000x)

C:128 W:256  
1/117

01-01-1986  
1726

27-05-2018  
20:11:17

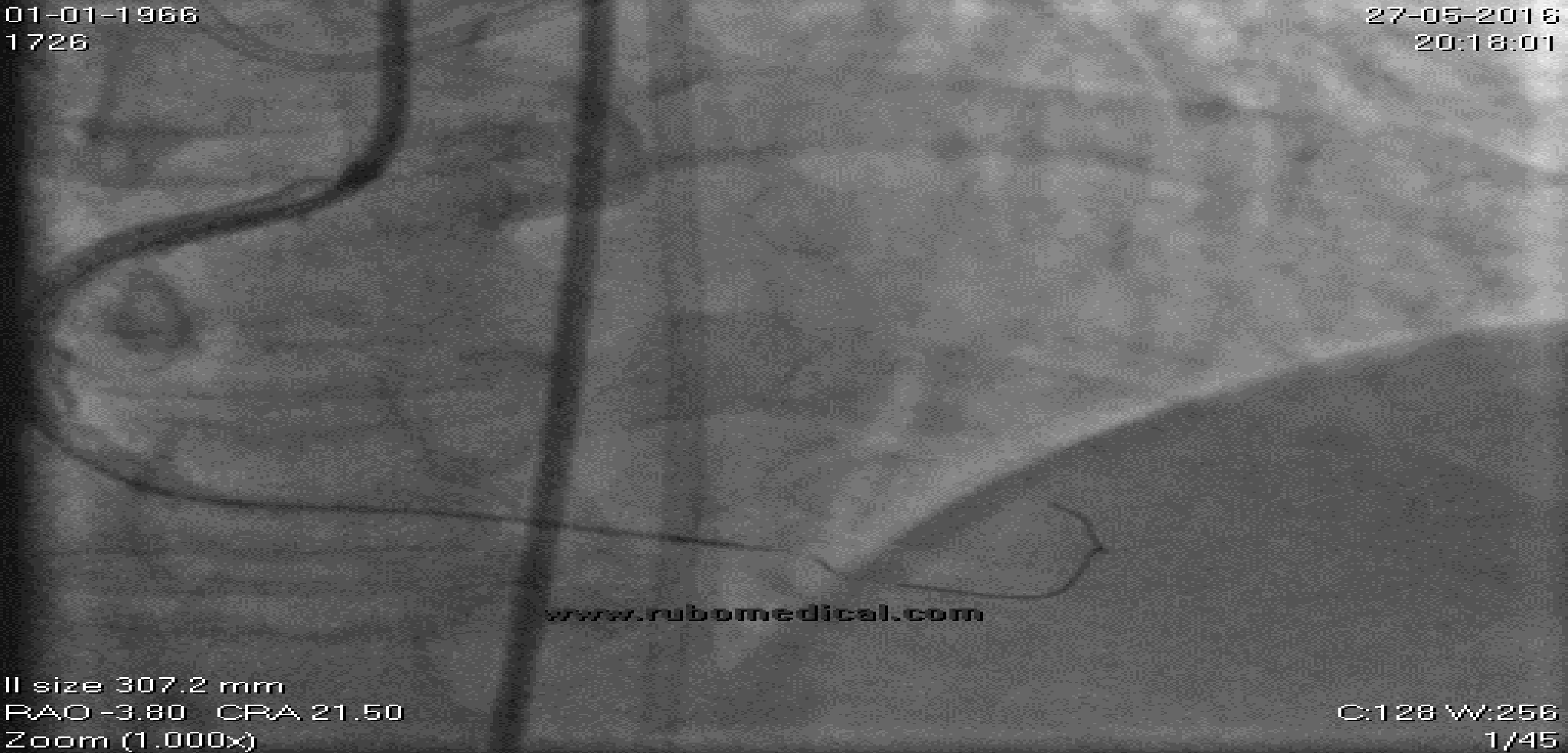
[www.rubomedical.com](http://www.rubomedical.com)

II size 307.2 mm  
RAO -6.80 CRA 25.60  
Zoom (1.000x)

C:128 W:256  
1/83

01-01-1986  
1726

27-05-2018  
20:18:01



[www.rubomedical.com](http://www.rubomedical.com)

II size 307.2 mm  
RAO -3.80 CRA 21.50  
Zoom (1.000x)

C:128 W:256  
1/45

01-01-1988  
1728

27-05-2018  
20:24:31

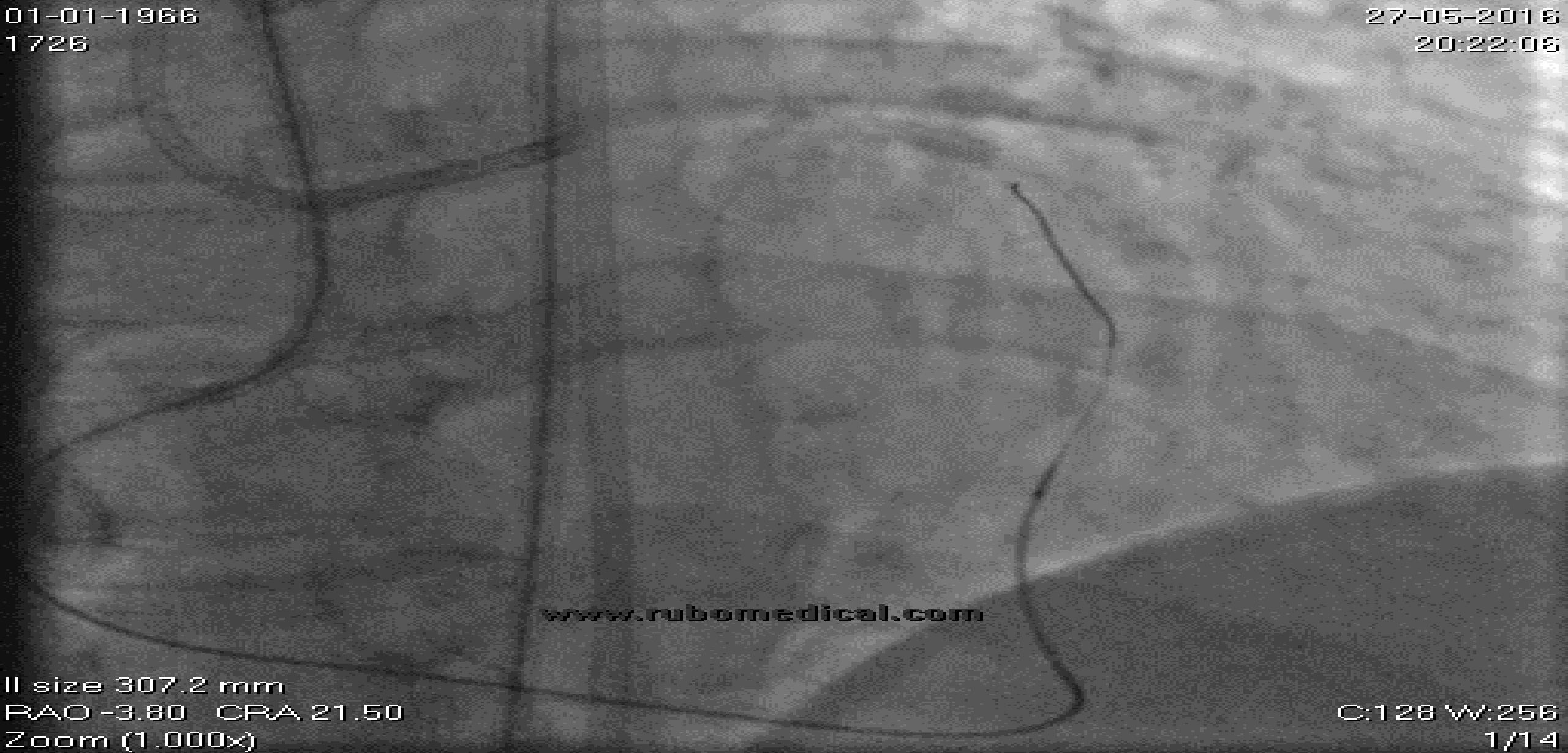
[www.rubomedical.com](http://www.rubomedical.com)

II size 307.2 mm  
LAO 5.00 CRA 29.20  
Zoom (1.000x)

C:128 W:256  
1/60

01-01-1966  
1726

27-05-2018  
20:22:06



www.rubomedical.com

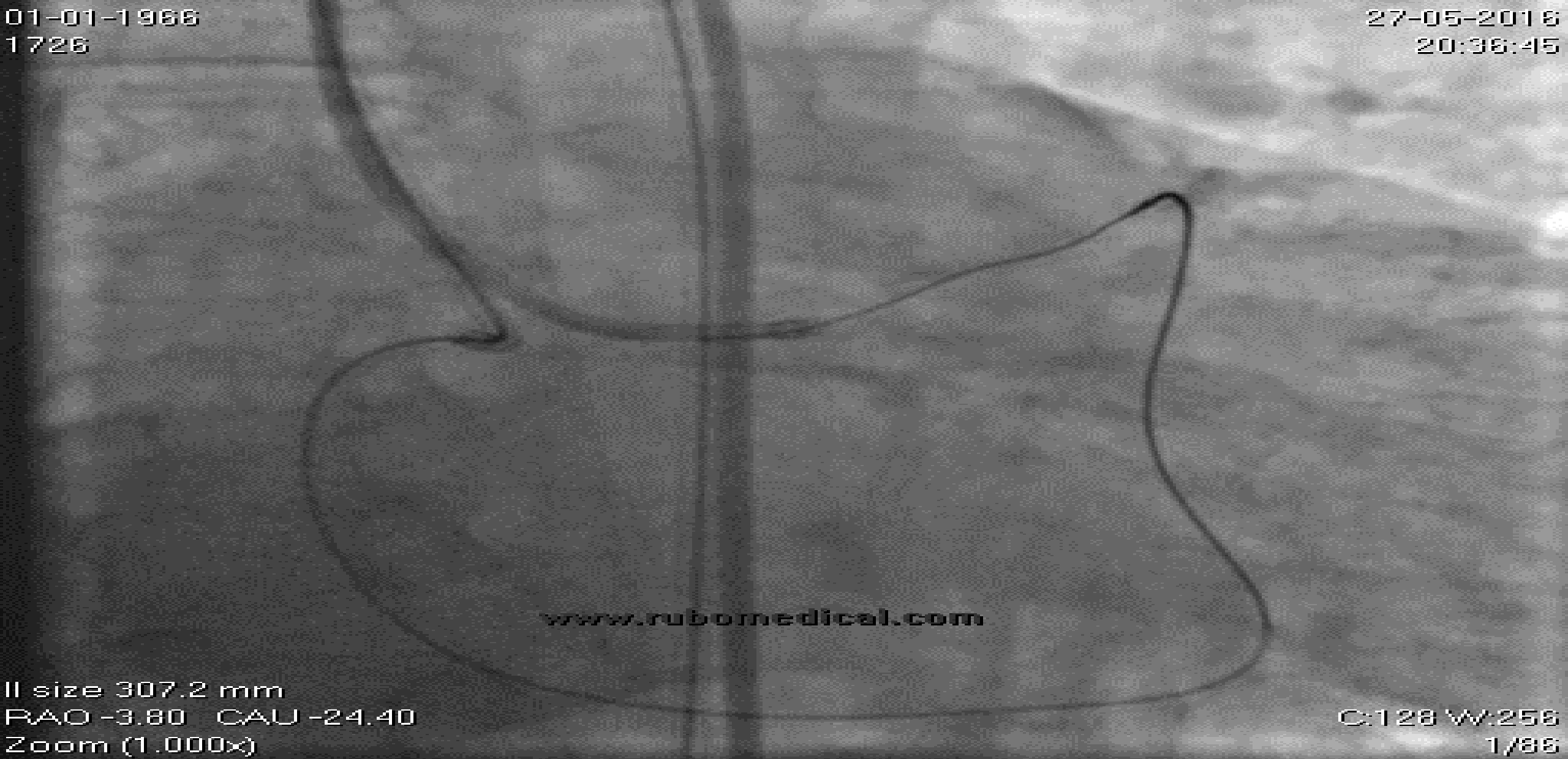
Il size 307.2 mm  
RAO -3.80 CRA 21.50  
Zoom (1.000x)

C:128 W:256  
1/14



01-01-1988  
1728

27-05-2018  
20:38:45



[www.rubomedical.com](http://www.rubomedical.com)

Il size 307.2 mm  
RAO -3.80 CAU -24.40  
Zoom (1.000x)

C:128 W:256  
1/88

01-01-1988  
1728

27-05-2018  
20:38:52

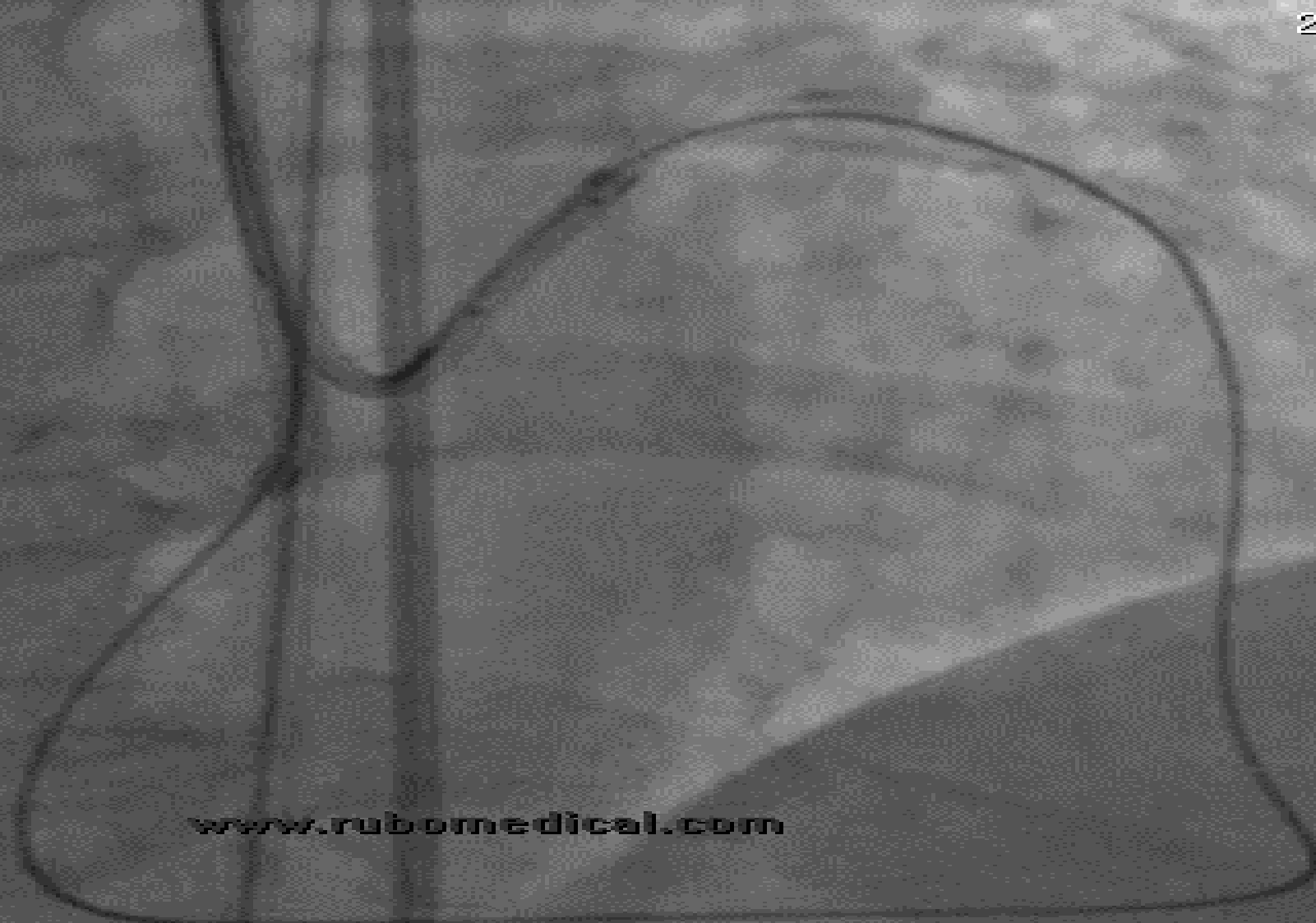
[www.rubomedical.com](http://www.rubomedical.com)

II size 307.2 mm  
RAO -9.00 CRA 21.40  
Zoom (1.000x)

C:128 W:256  
1/18

01-01-1966  
1726

27-05-2018  
20:39:47



[www.rubomedical.com](http://www.rubomedical.com)

II size 307.2 mm  
RAO -9.00 CRA 21.40  
Zoom (1.000x)

C:128 W:256  
1/15

01-01-1966  
1726

27-05-2018  
20:43:34

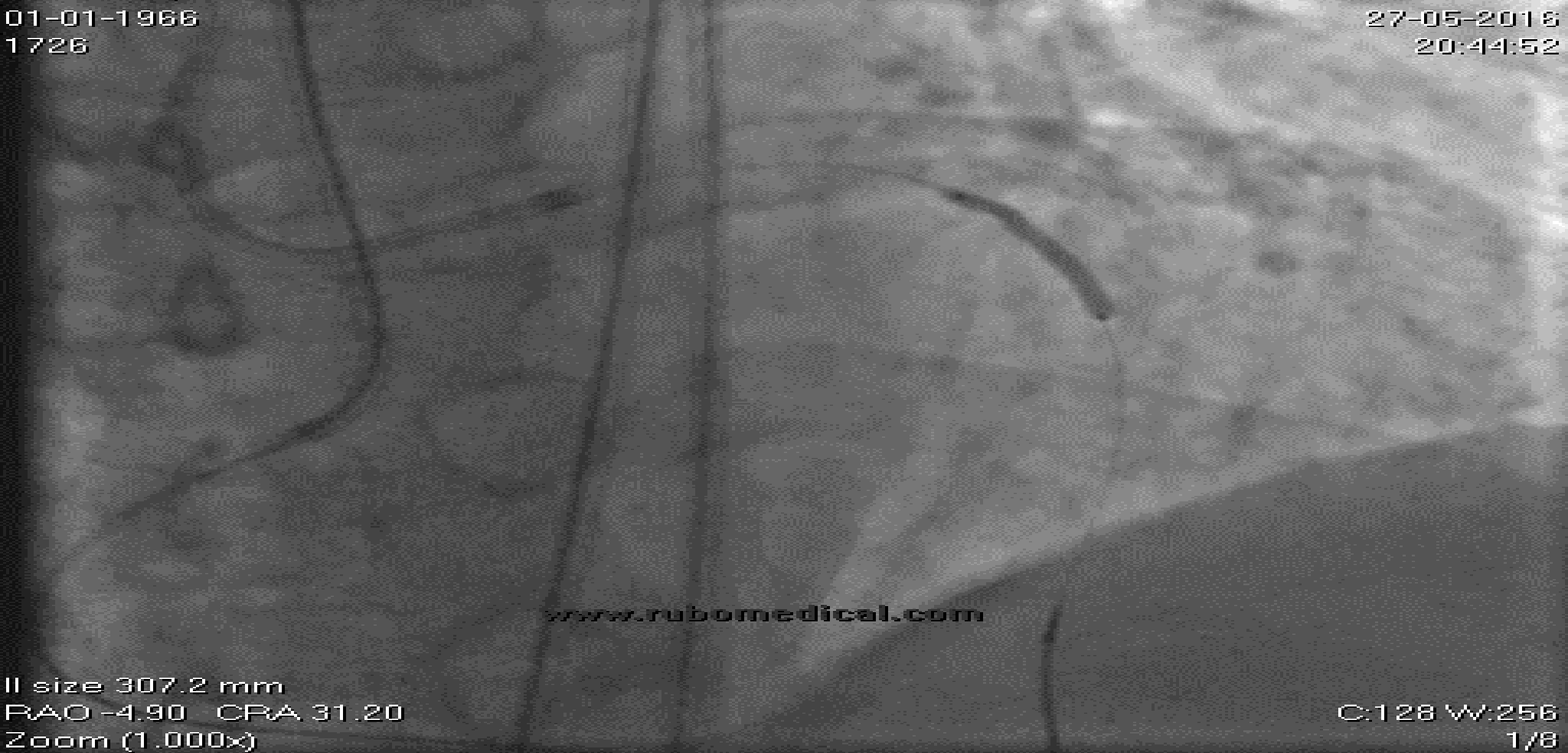[www.rubomedical.com](http://www.rubomedical.com)

II size 307.2 mm  
RAO -9.50 CRA 24.40  
Zoom (1.000x)

C:128 W:256  
1/10

01-01-1986  
1726

27-05-2018  
20:44:52



www.rubomedical.com

II size 307.2 mm  
RAO -4.90 CRA 31.20  
Zoom (1.000x)

C:128 W:256  
1/8

01-01-1988  
1726

27-05-2018  
20:46:03

[www.rubomedical.com](http://www.rubomedical.com)

II size 307.2 mm  
RAO -4.90 CRA 31.40  
Zoom (1.000x)

C:128 W:256  
1/53

01-01-1988  
1728

27-05-2018  
20:48:33

[www.rubomedical.com](http://www.rubomedical.com)

II size 307.2 mm  
RAO -25.00 CAU -14.10  
Zoom (1.000x)

C:128 W:256  
1/8

01-01-1986  
1728

27-05-2018  
20:50:17

[www.rubomedical.com](http://www.rubomedical.com)

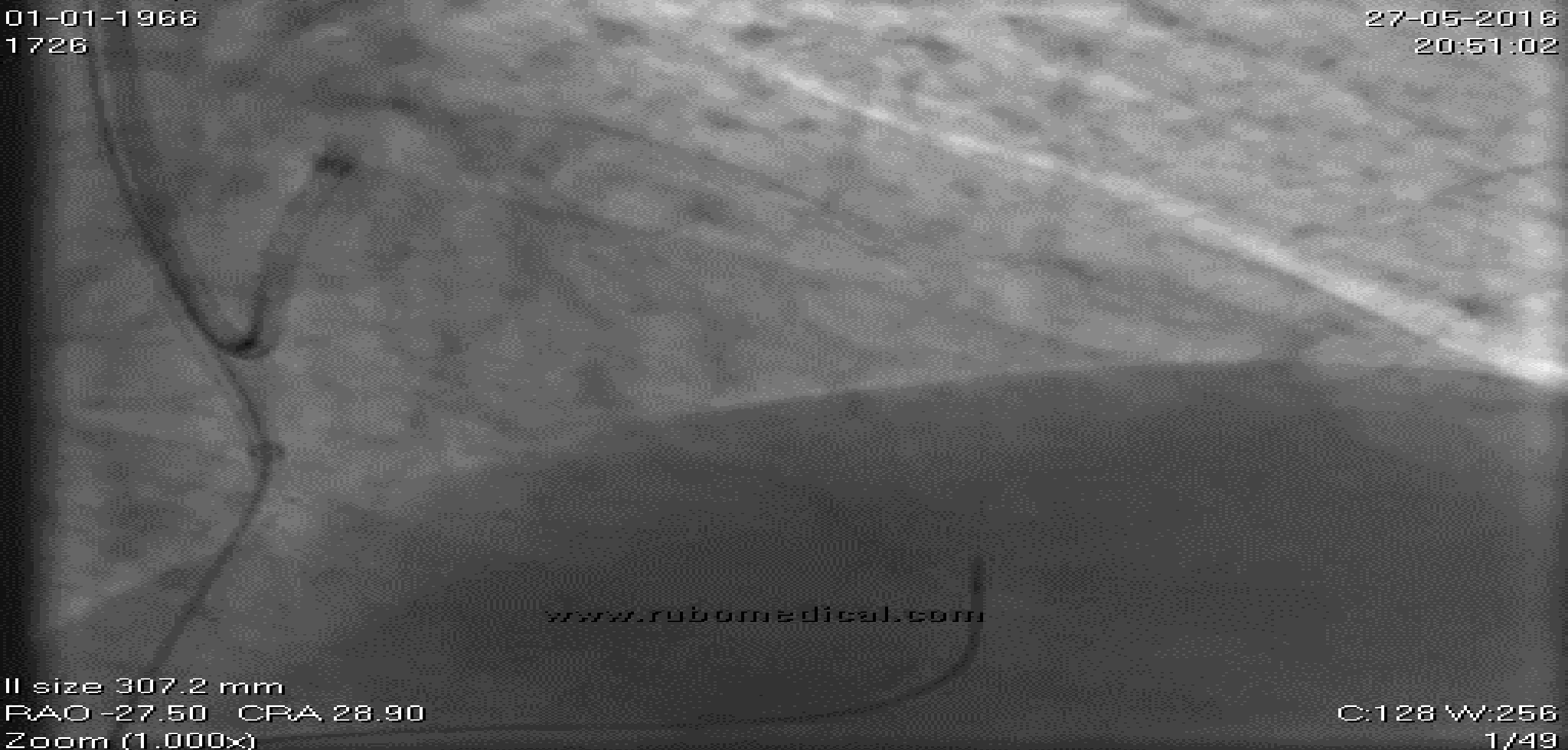
Il size 307.2 mm  
RAO -25.00 CAU -14.10  
Zoom (1.000x)

C:128 W:256  
1/15



01-01-1988  
1726

27-05-2018  
20:51:02



[www.rubomedical.com](http://www.rubomedical.com)

II size 307.2 mm  
RAO -27.50 CRA 28.90  
Zoom (1.000x)

C:128 W:256  
1/49

01-01-1988  
1728

27-05-2018  
20:52:32

[www.rubomedical.com](http://www.rubomedical.com)

II size 307.2 mm  
LAO 23.00 CRA 11.90  
Zoom (1.000x)

C:128 W:256  
1/86

01-01-1966

1726

27-05-2016

20:53:22

[www.rubomedical.com](http://www.rubomedical.com)

II size 307.2 mm

RAO -40.00 CRA 32.40

Zoom (1.000x)

C:128 W:256

1/57



---

TEŞEKKÜRLER