

TİPİK MİKROKANAL VAKASI

DR. ÜNAL ÖZTÜRK

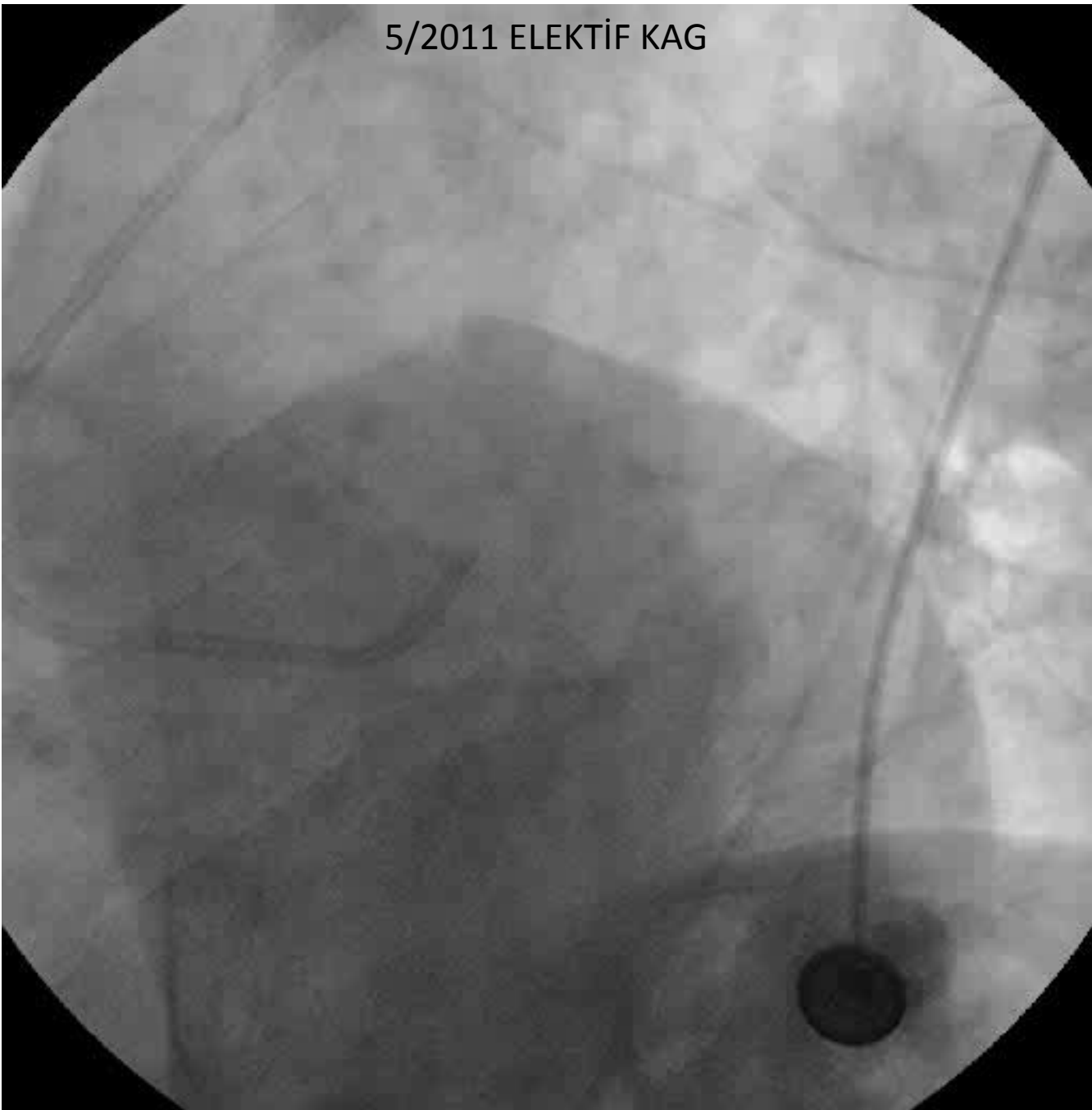NECİP FAZIL ŞEHİR DEVLET HASTANESİ

KAHRAMANMARAŞ

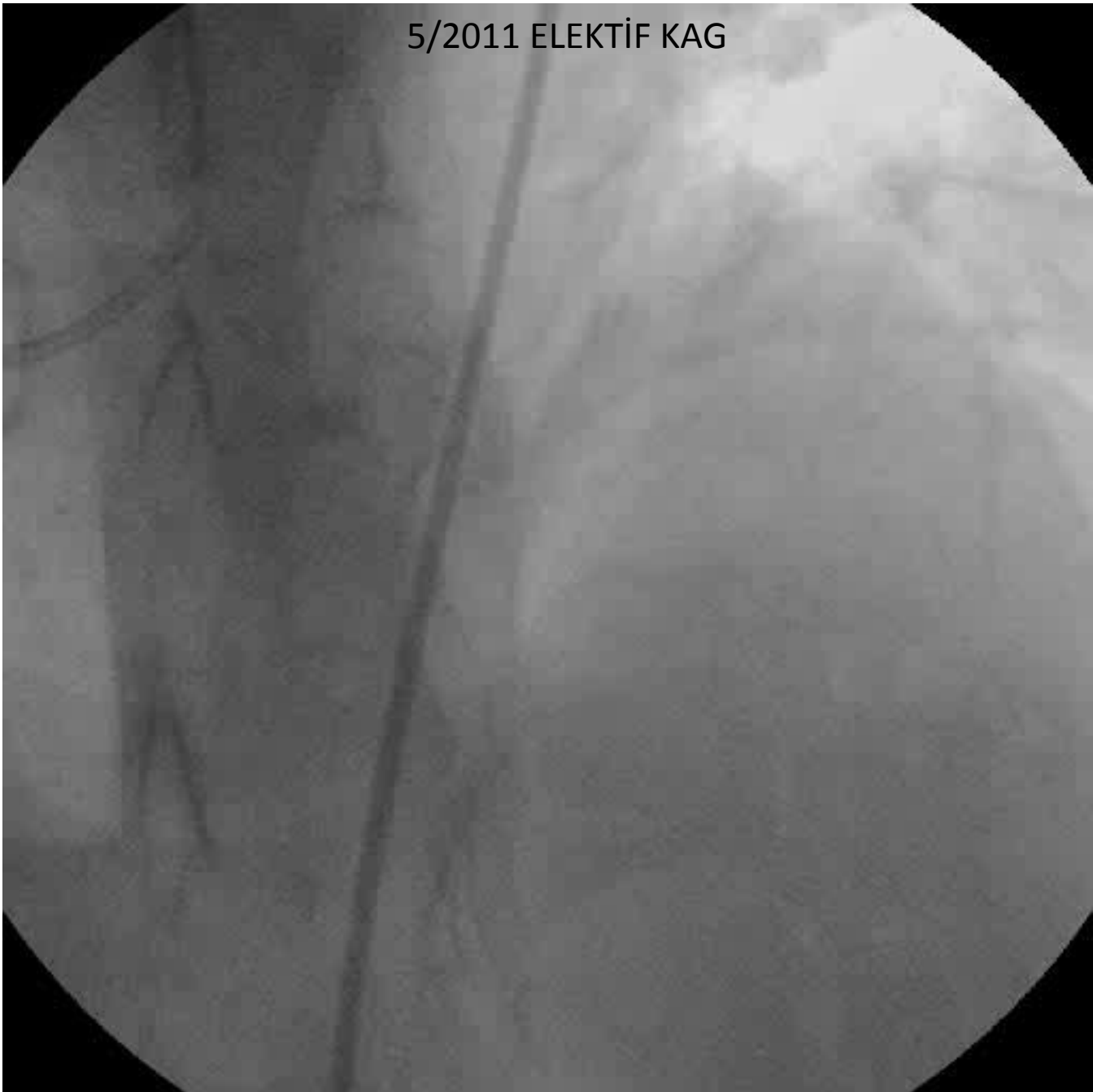
OLGU

- 57 Y. ERKEK
- İLK KARDİYOLOJİ POLK. BAŞVURUSU
- BİR YILDIR EFOR ANGINASI
- RİSK FAKTÖRÜ: HT(+) 5 YIL
- EKG: NSR, 85/DK, ANTERİOR DERİVASYONLARDA MİNİMAL T DALGA NEGATİFLİĞİ
- EKO: EF%55, HAFİF LV HİPERTROFİSİ, APIKOSEPTAL HİPOKİNETİK, ÇAPLAR VE KAPAKLAR DOĞAL.
- EFOR TESTİ: POZİTİF
- LABORATUVAR: AKŞ:95, LDL:170, CREATİNİN:1.0

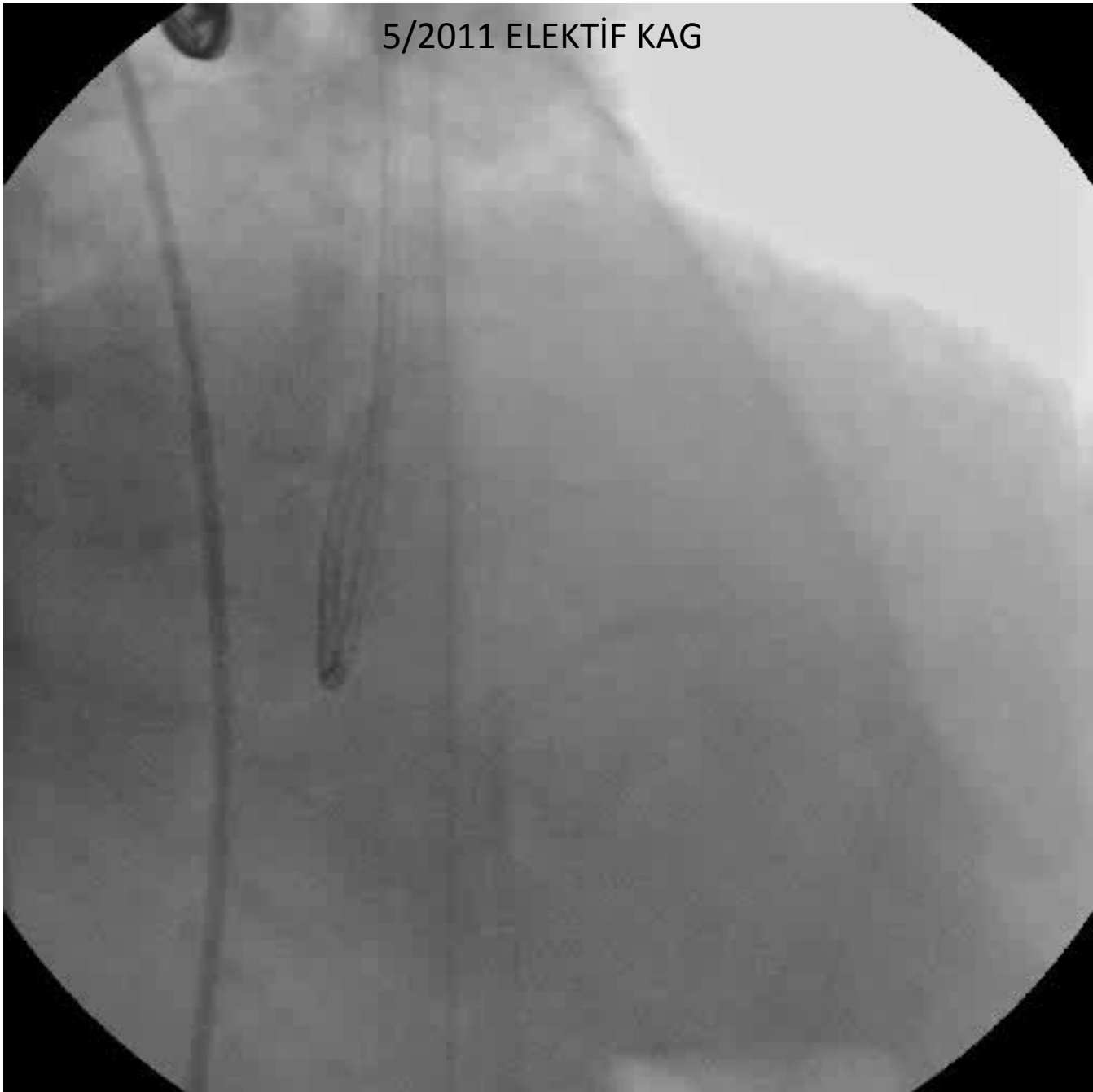
5/2011 ELEKTİF KAG



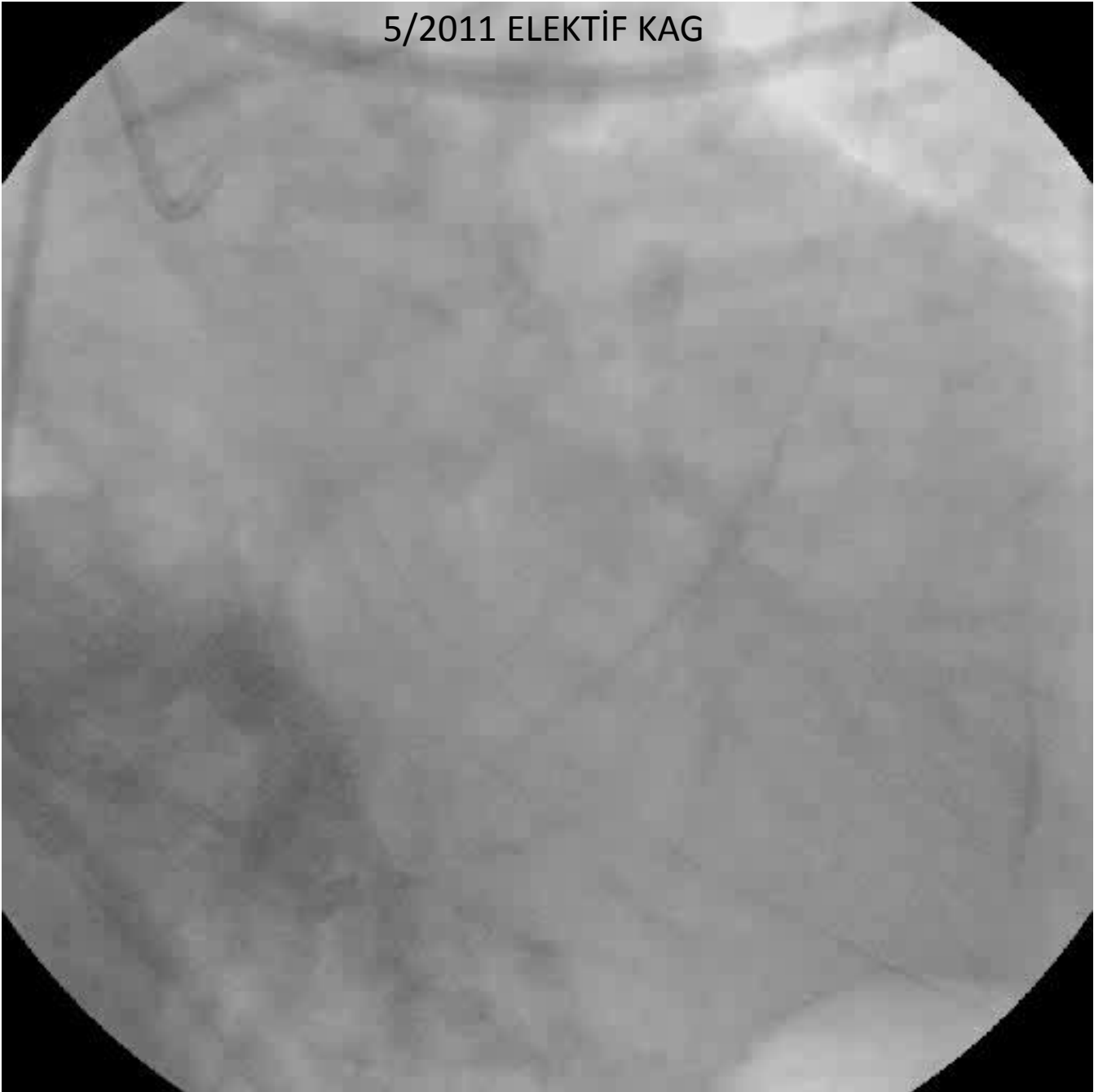5/2011 ELEKTİF KAG



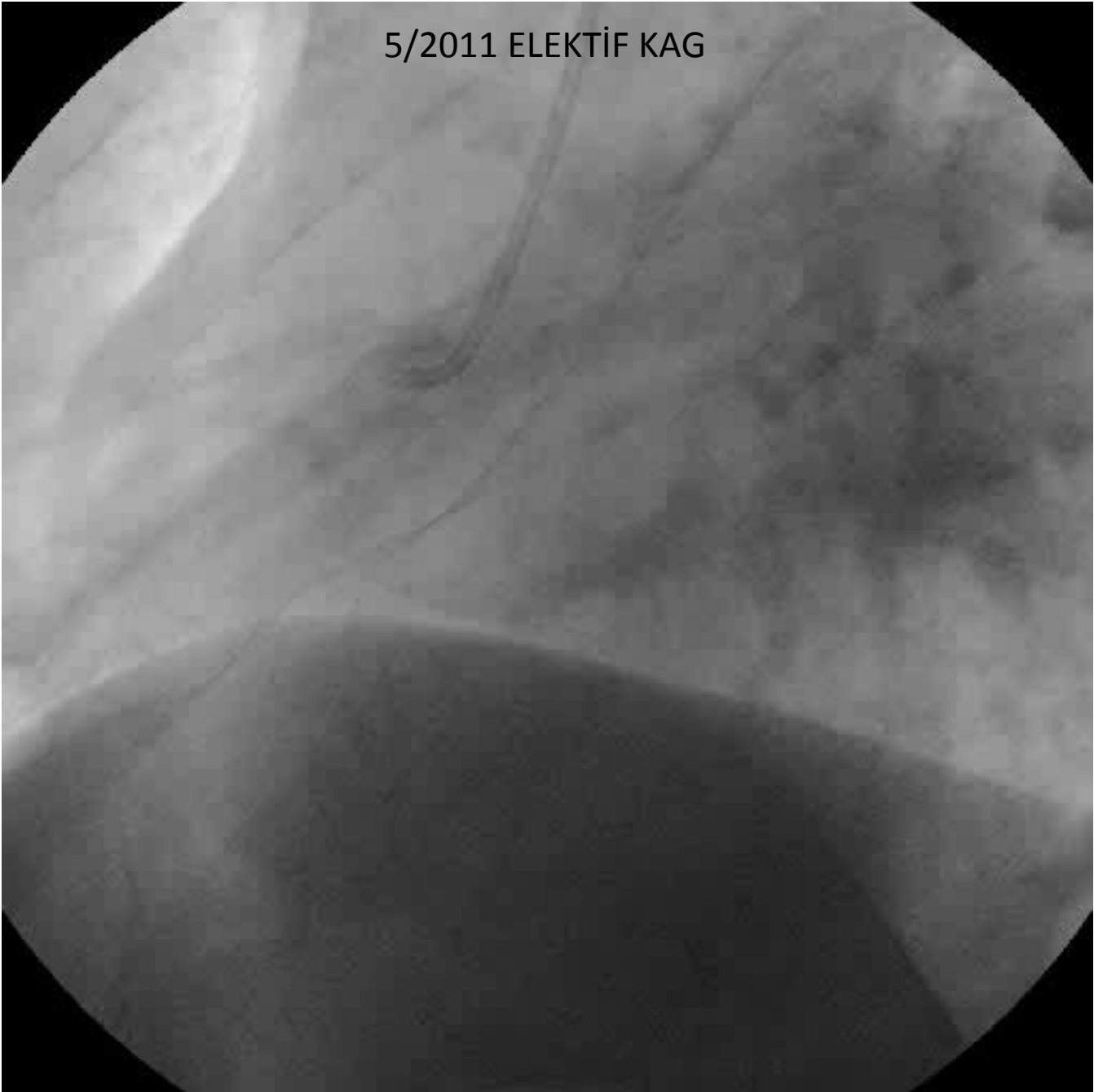5/2011 ELEKTİF KAG



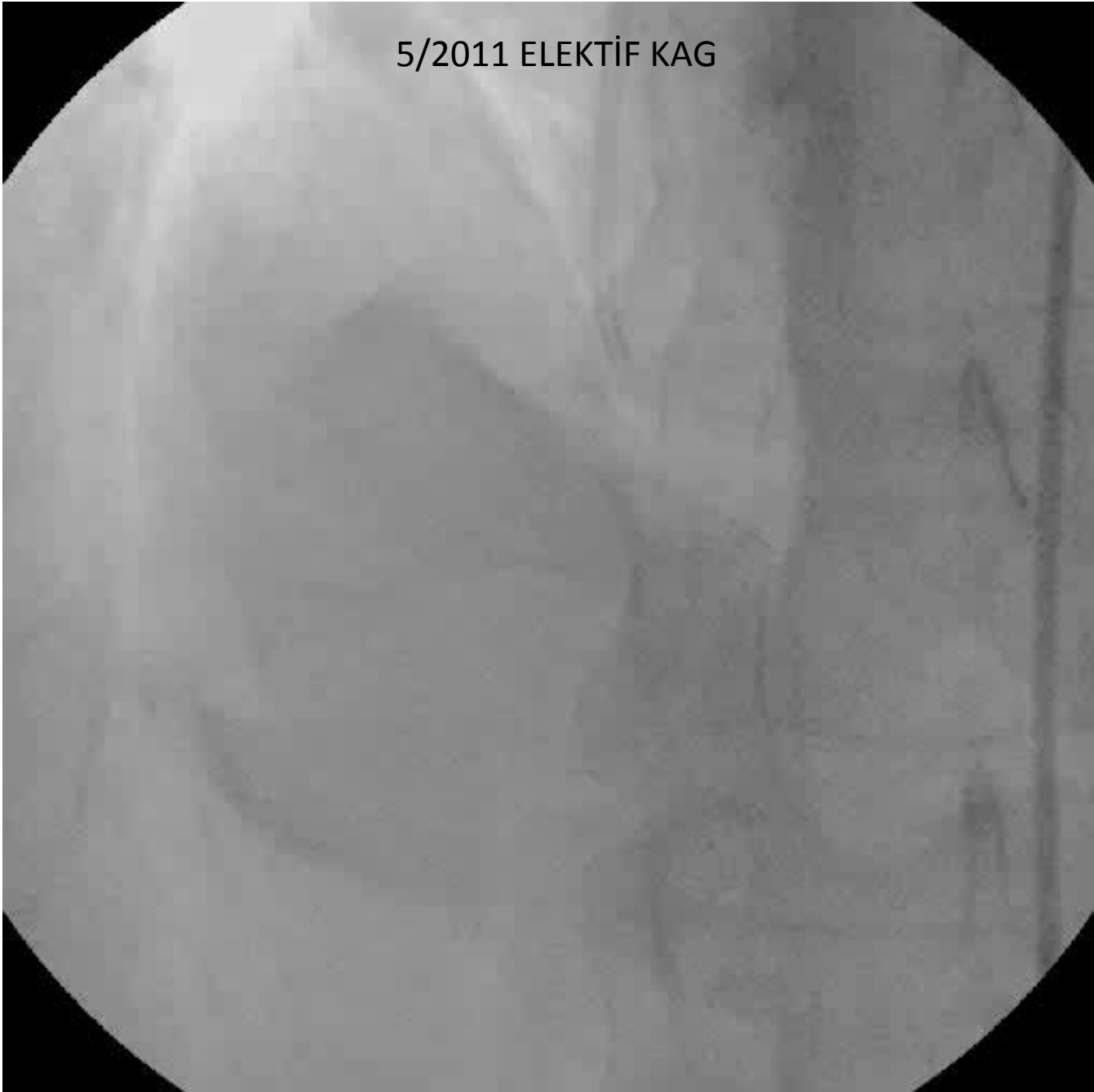5/2011 ELEKTİF KAG



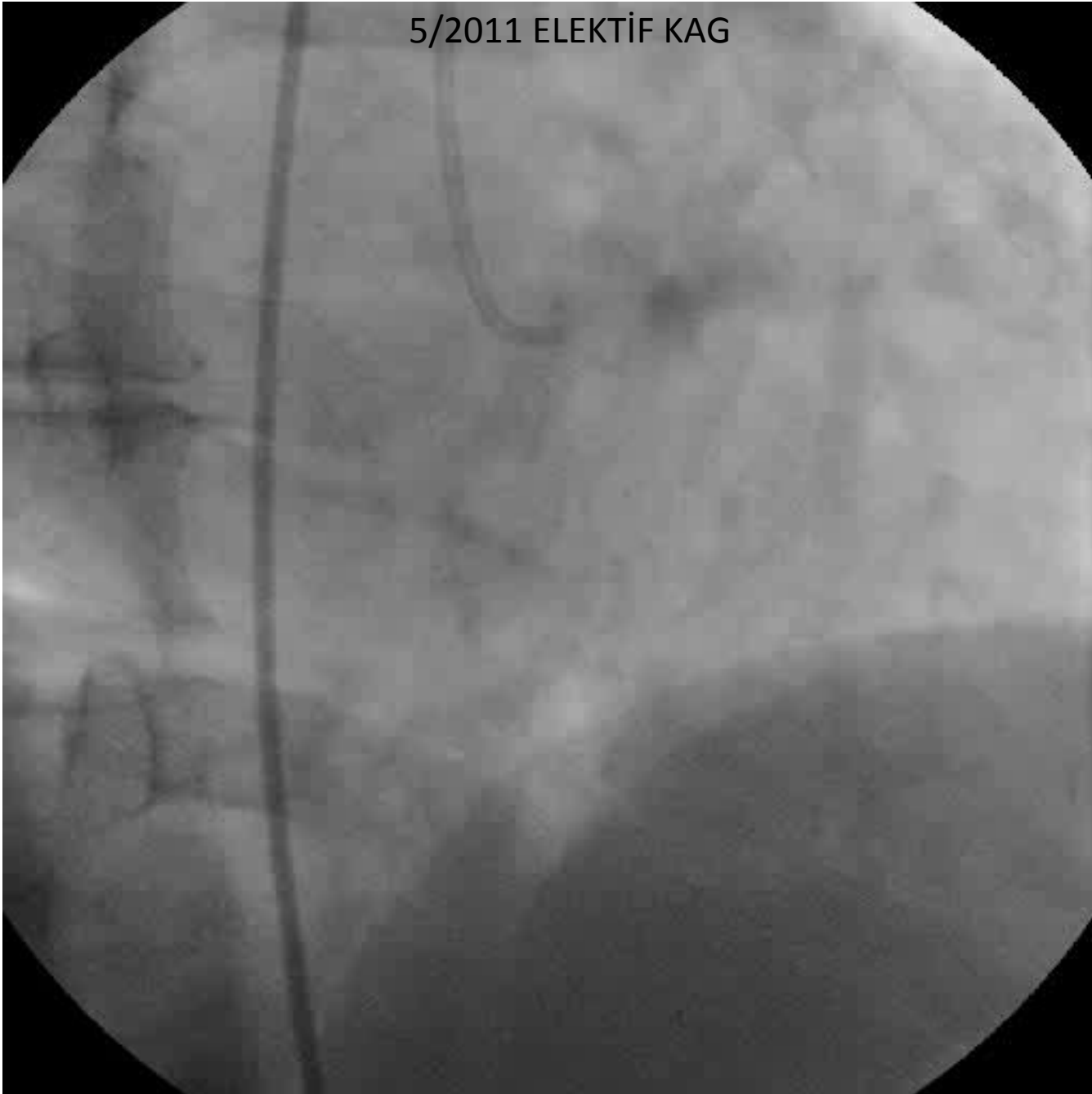
5/2011 ELEKTİF KAG



5/2011 ELEKTİF KAG



5/2011 ELEKTİF KAG

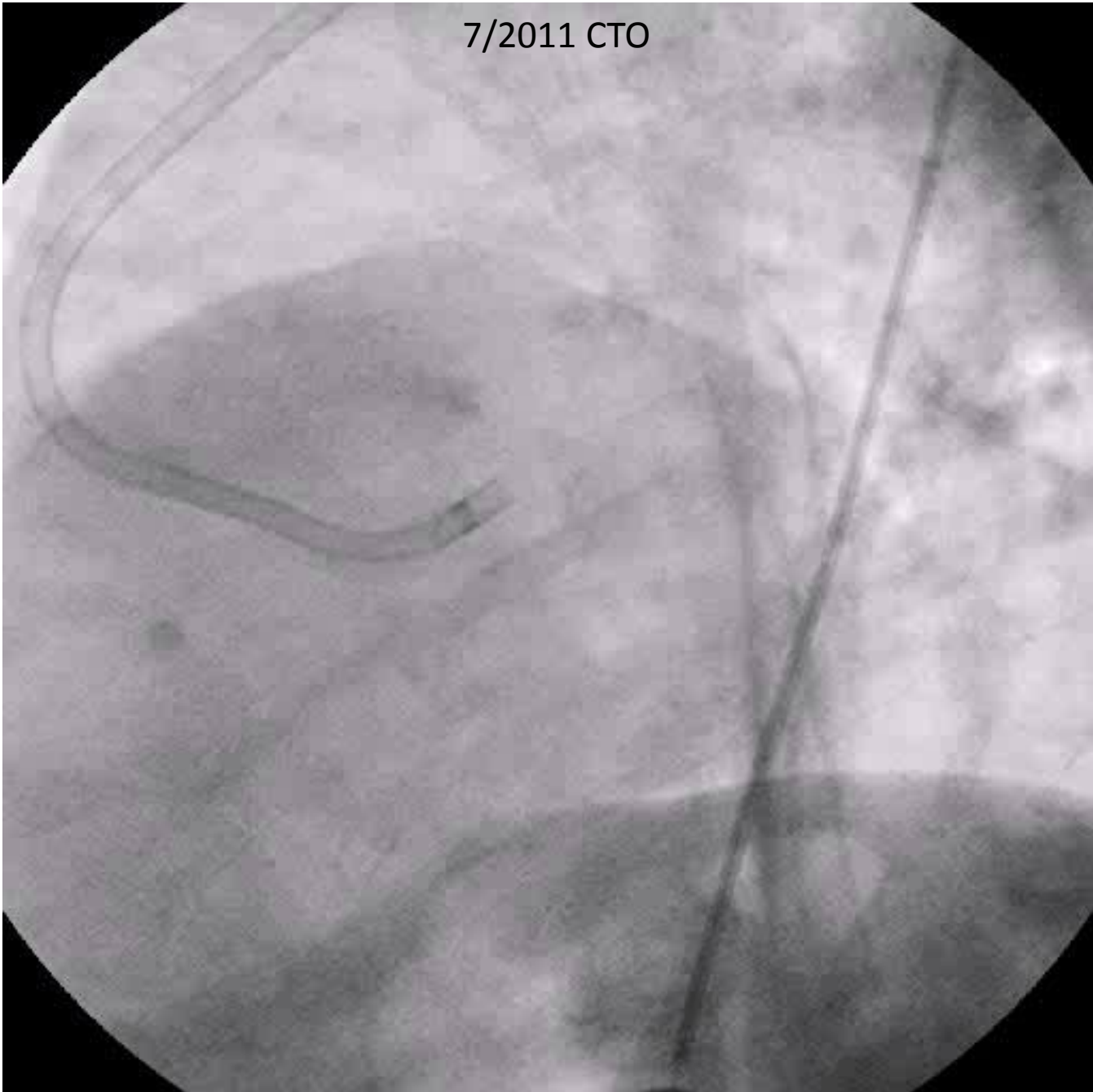


KAG DEĞERLENDİRMESİ

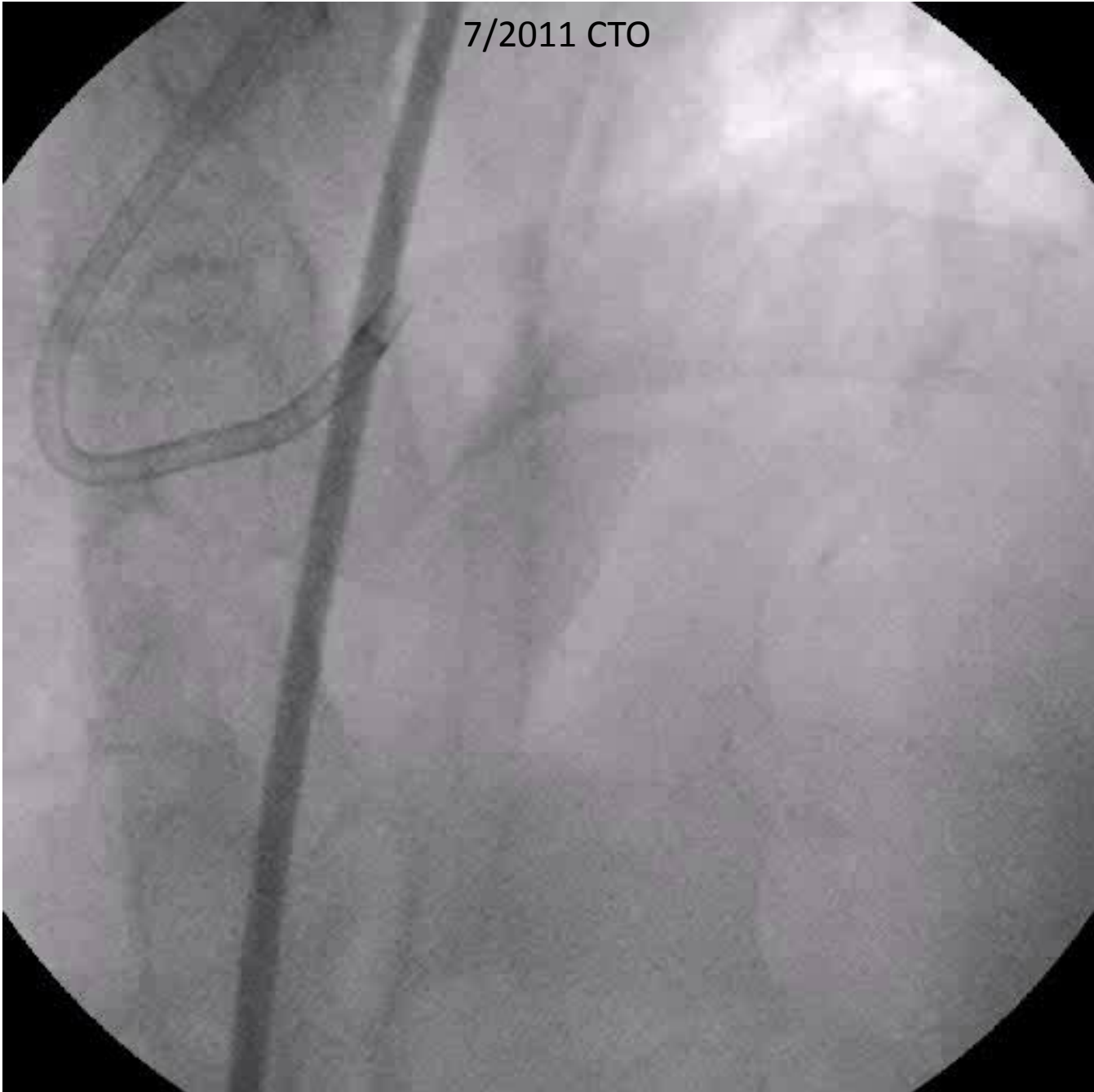- LM: NORMAL
- LAD: 1. SEPTAL SONRASI %100 TIKALI (CTO)
- CX: 1. OM MİD %30 PLK
- RCA: SGV ÖNCESİ %50

KARAR: LAD CTO LEZYONUNA ELEKTİF GİRİŞİM

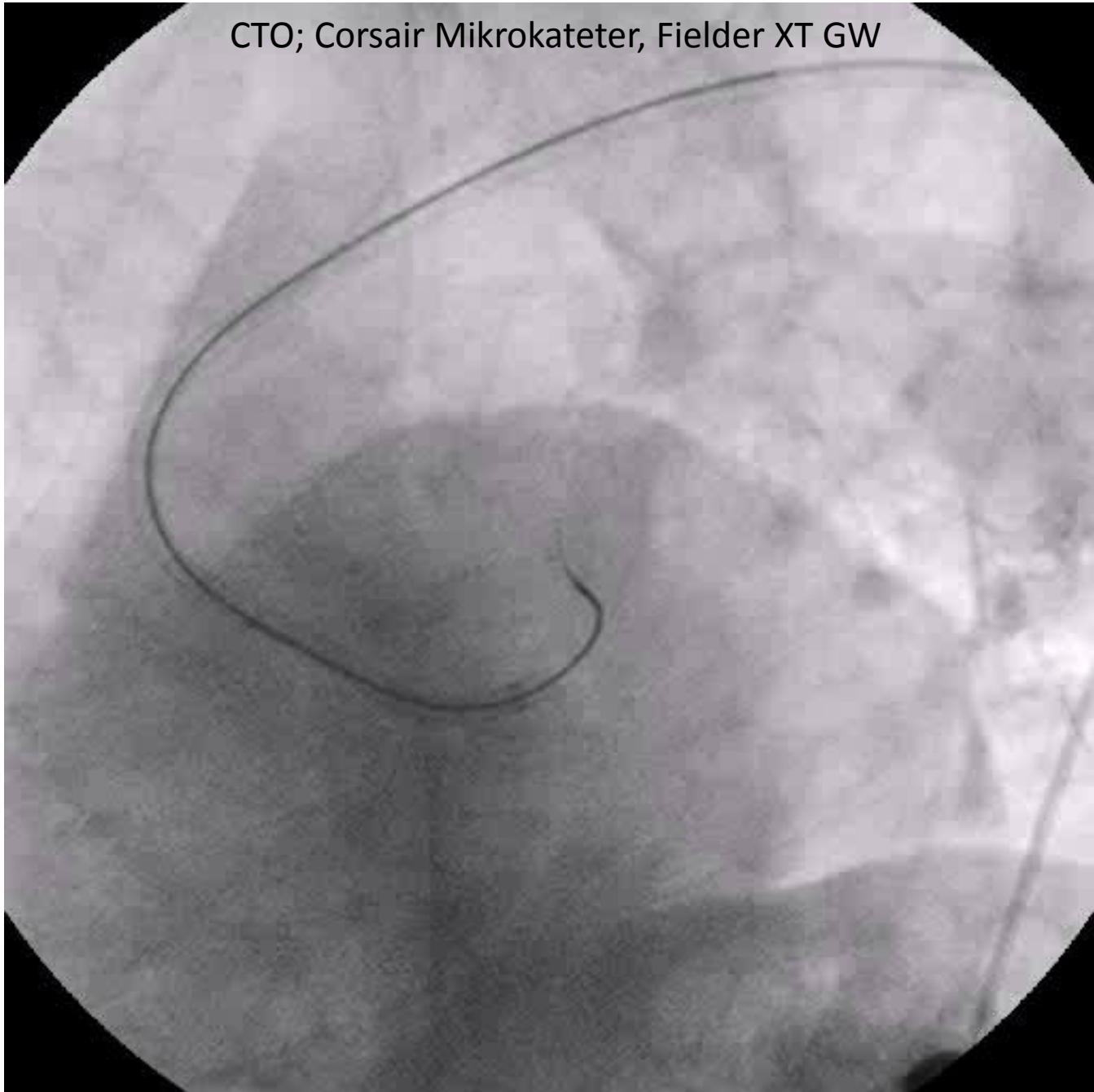
7/2011 CTO



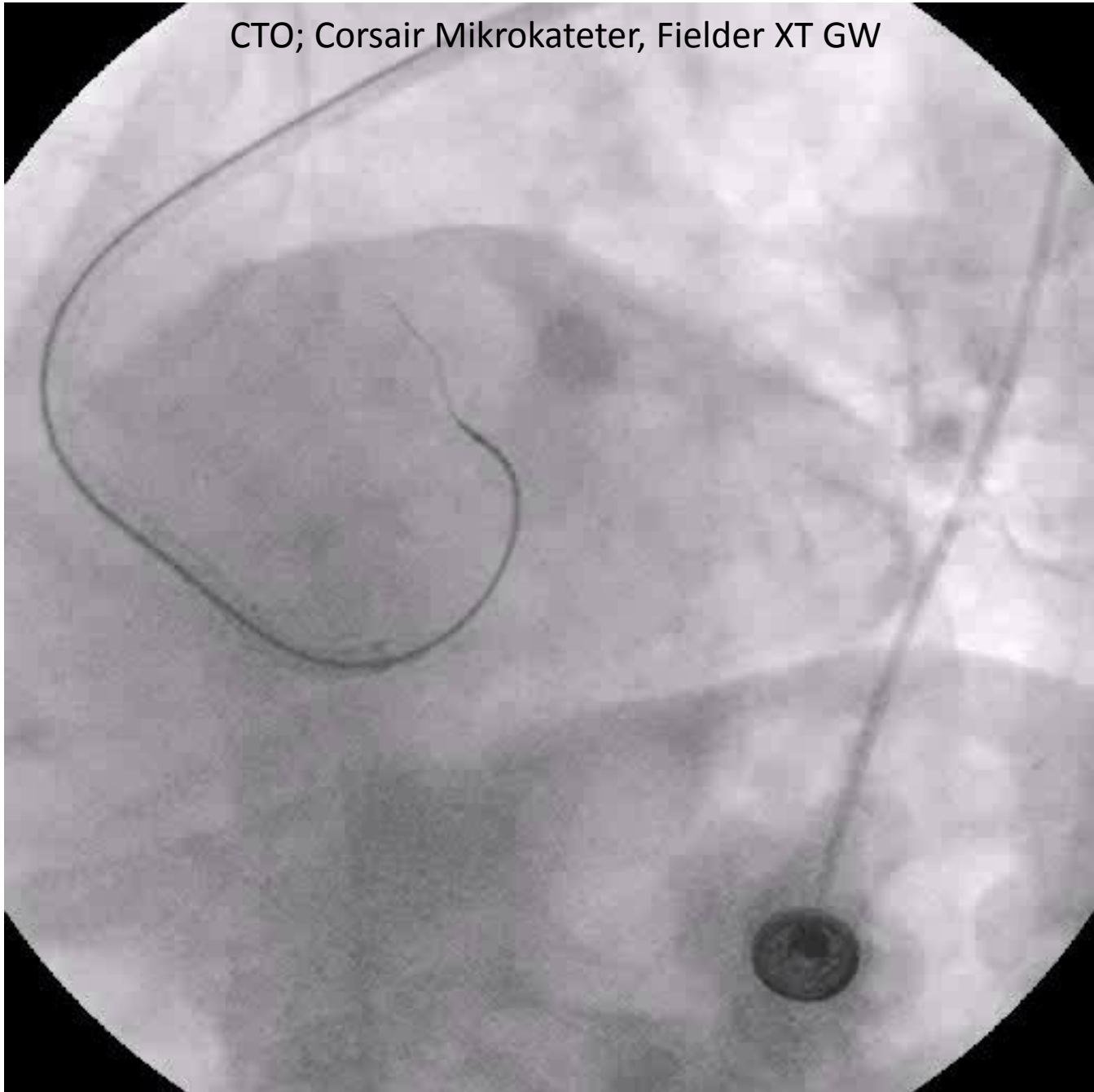
7/2011 CTO



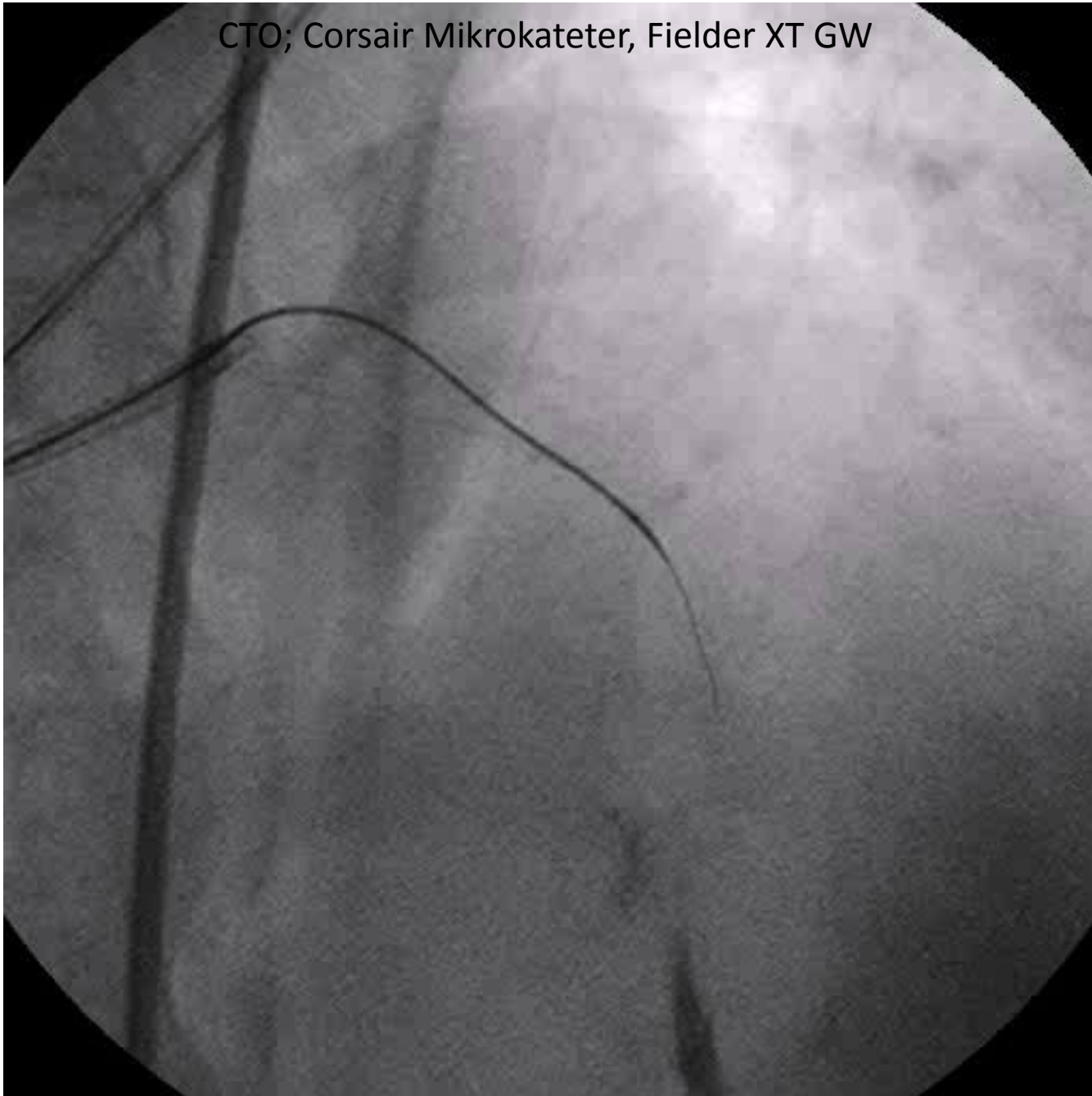CTO; Corsair Mikrokateter, Fielder XT GW



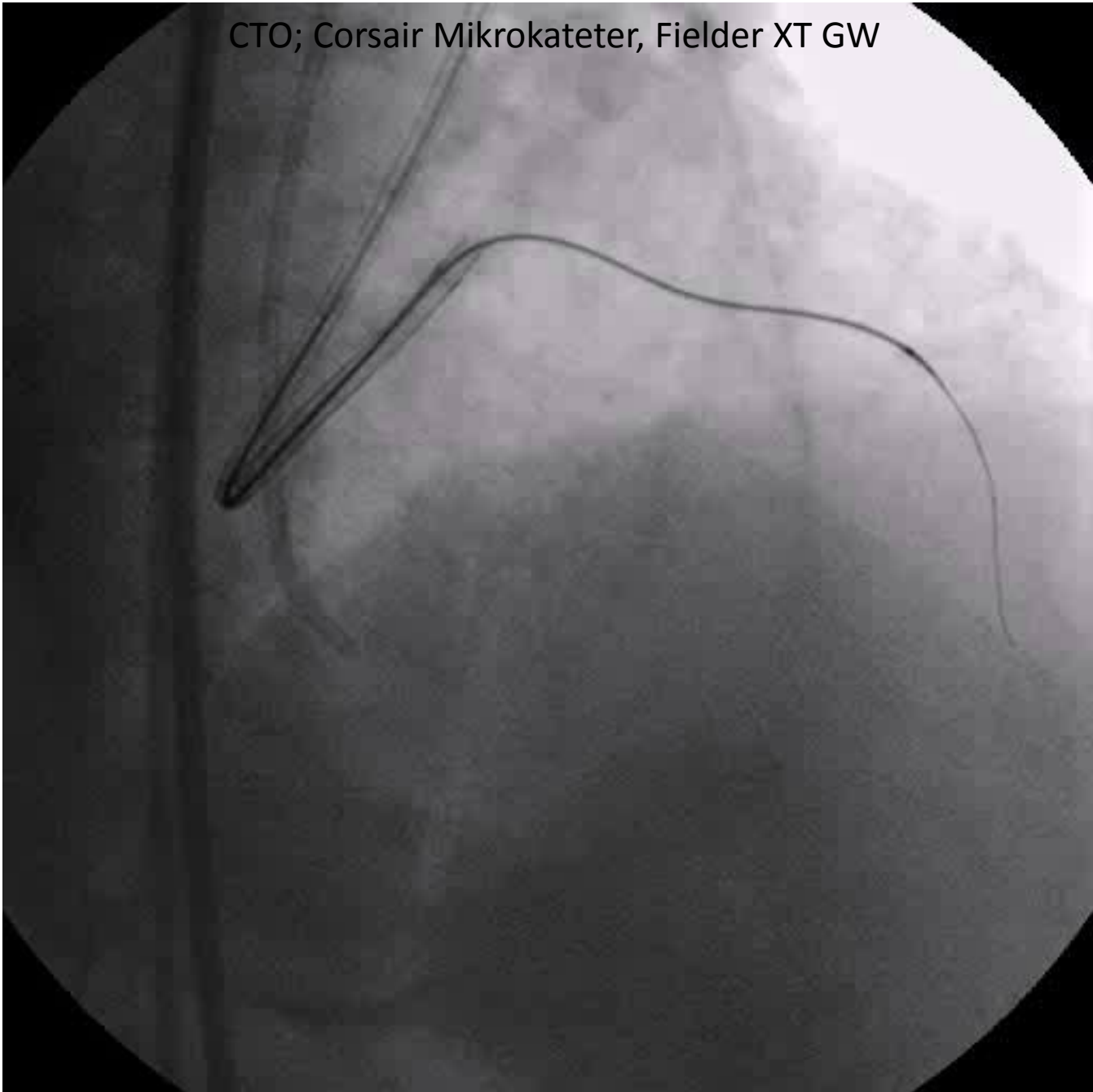
CTO; Corsair Mikrokateter, Fielder XT GW



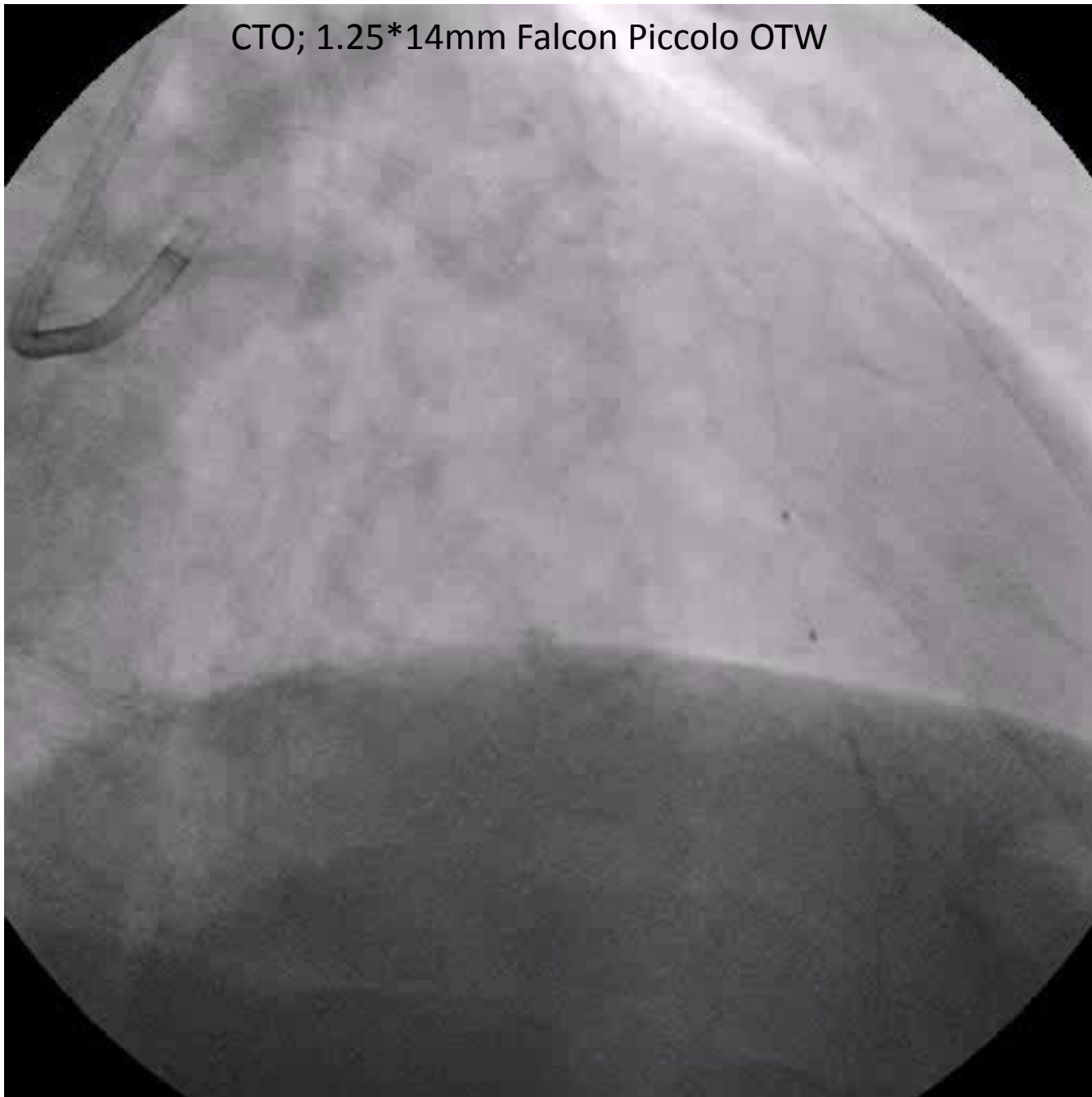
CTO; Corsair Mikrokateter, Fielder XT GW



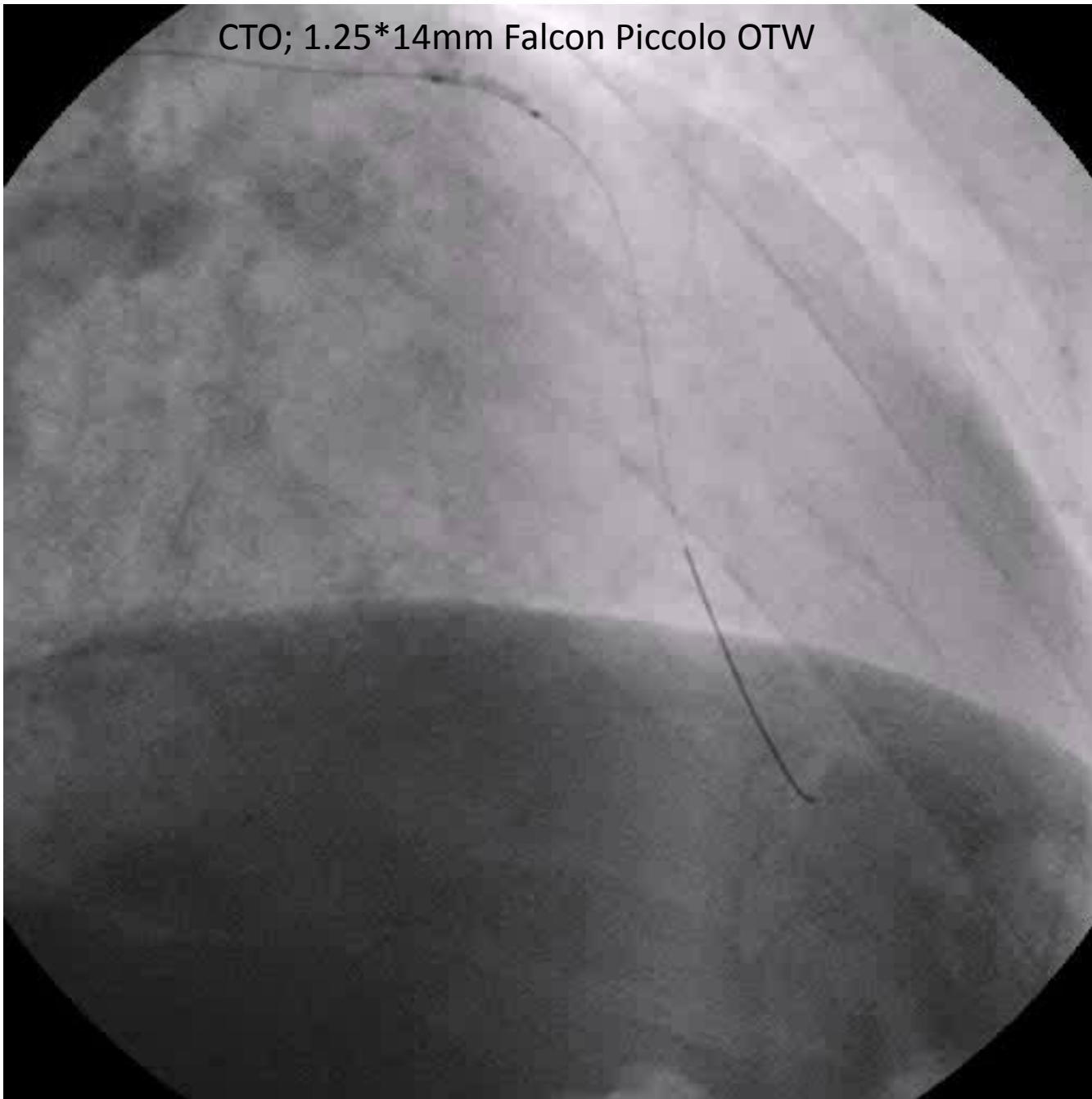
CTO; Corsair Mikrokateter, Fielder XT GW



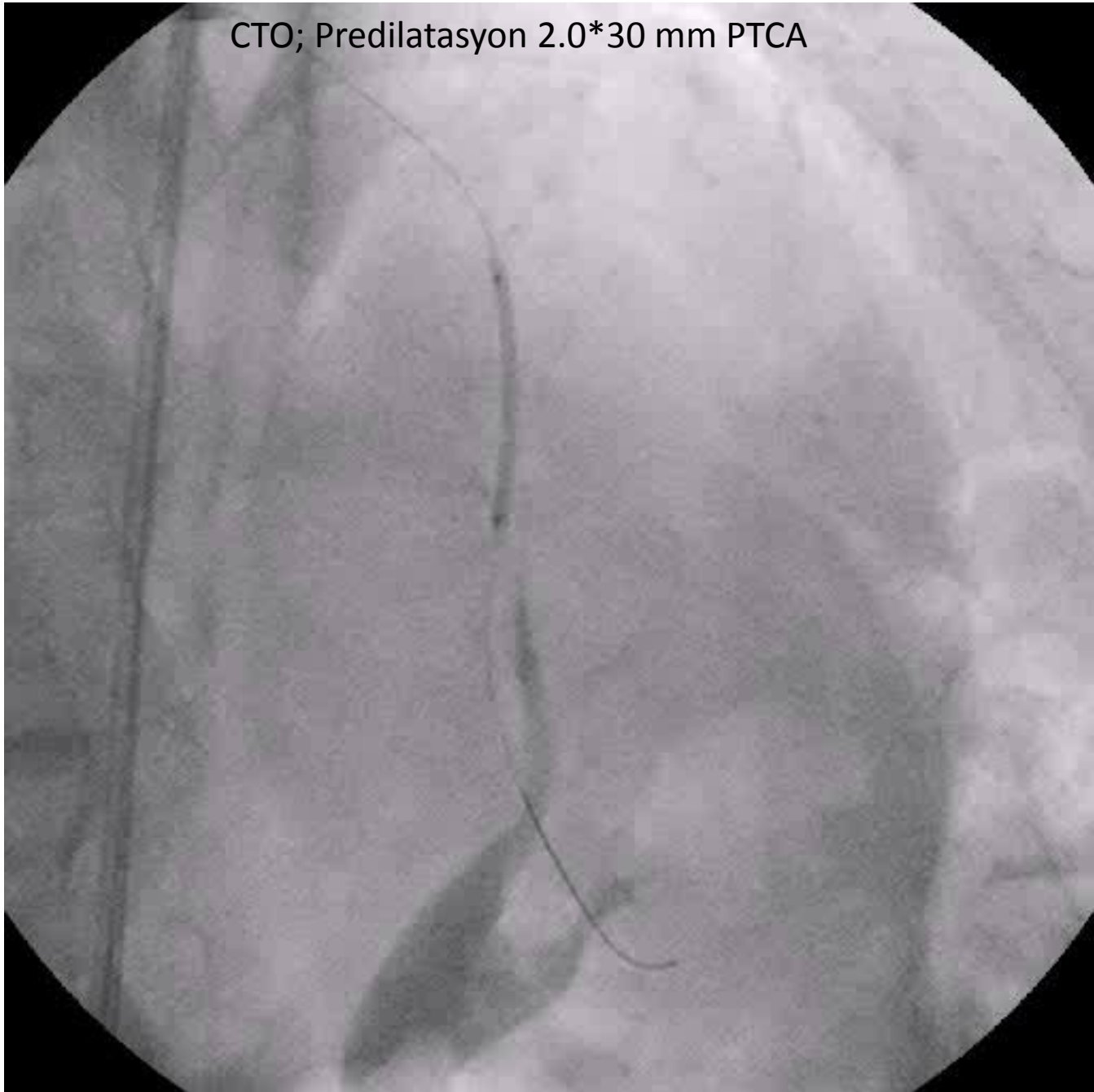
CTO; 1.25*14mm Falcon Piccolo OTW



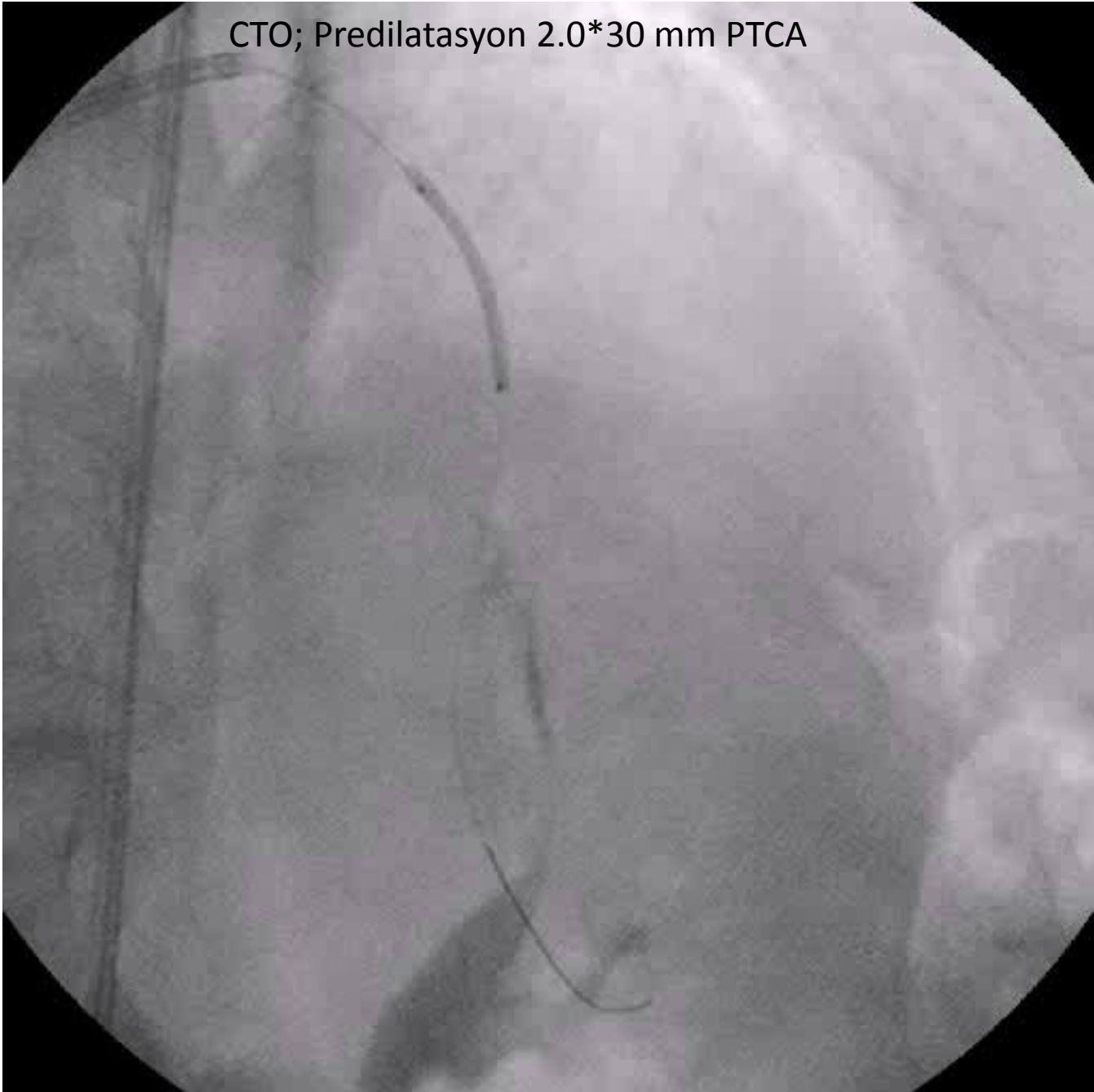
CTO; 1.25*14mm Falcon Piccolo OTW



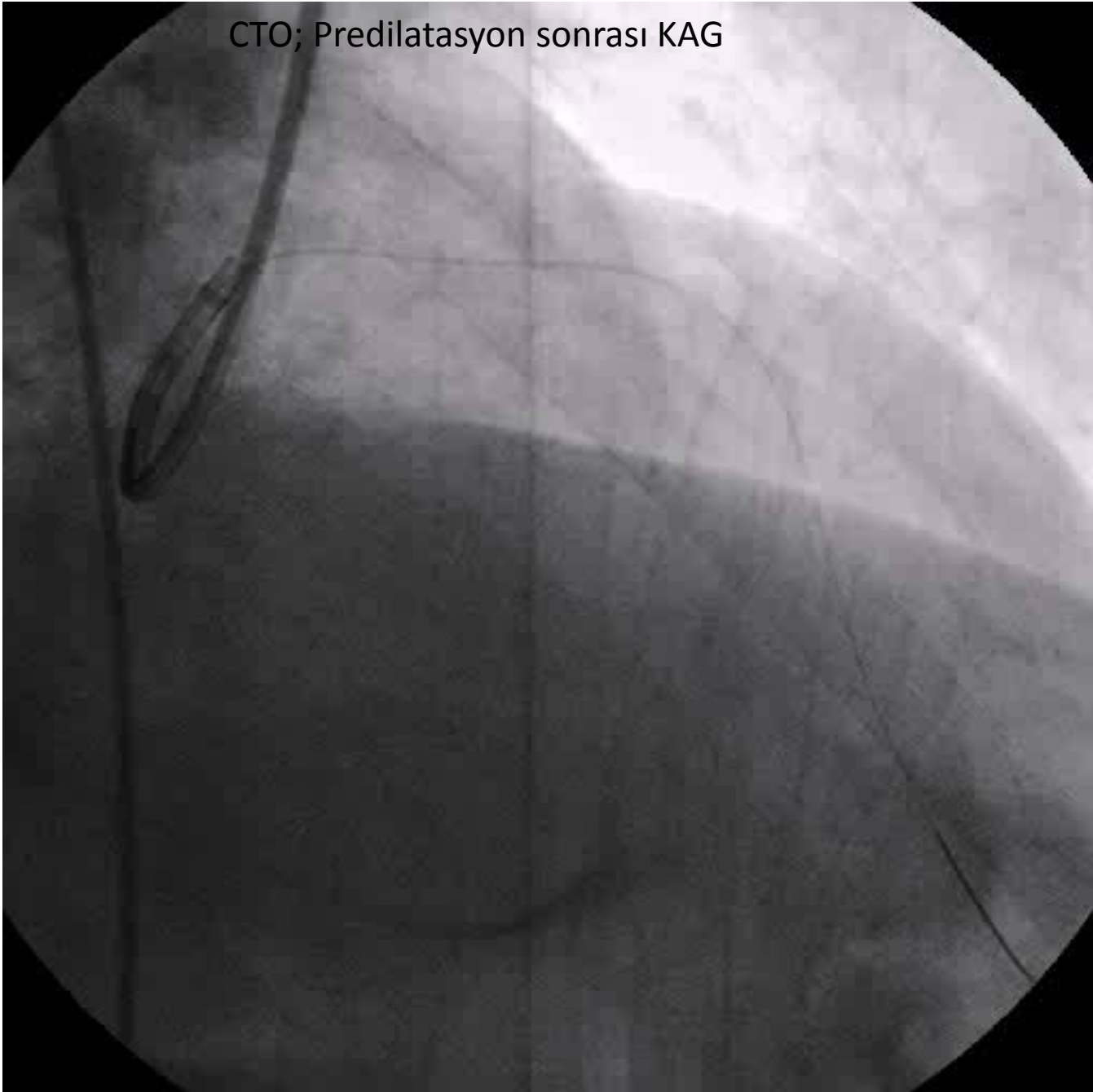
CTO; Predilatasyon 2.0*30 mm PTCA



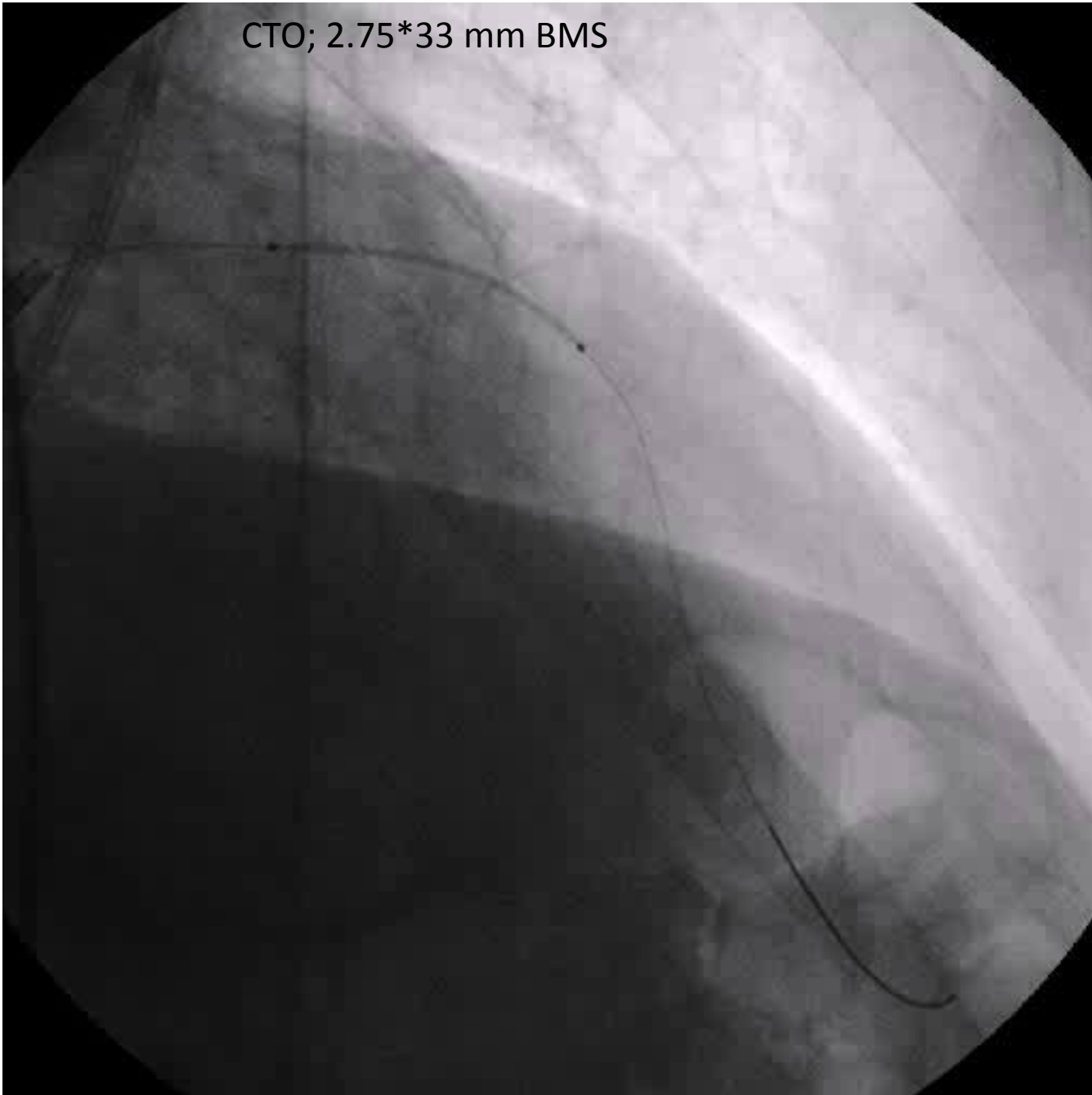CTO; Predilatasyon 2.0*30 mm PTCA



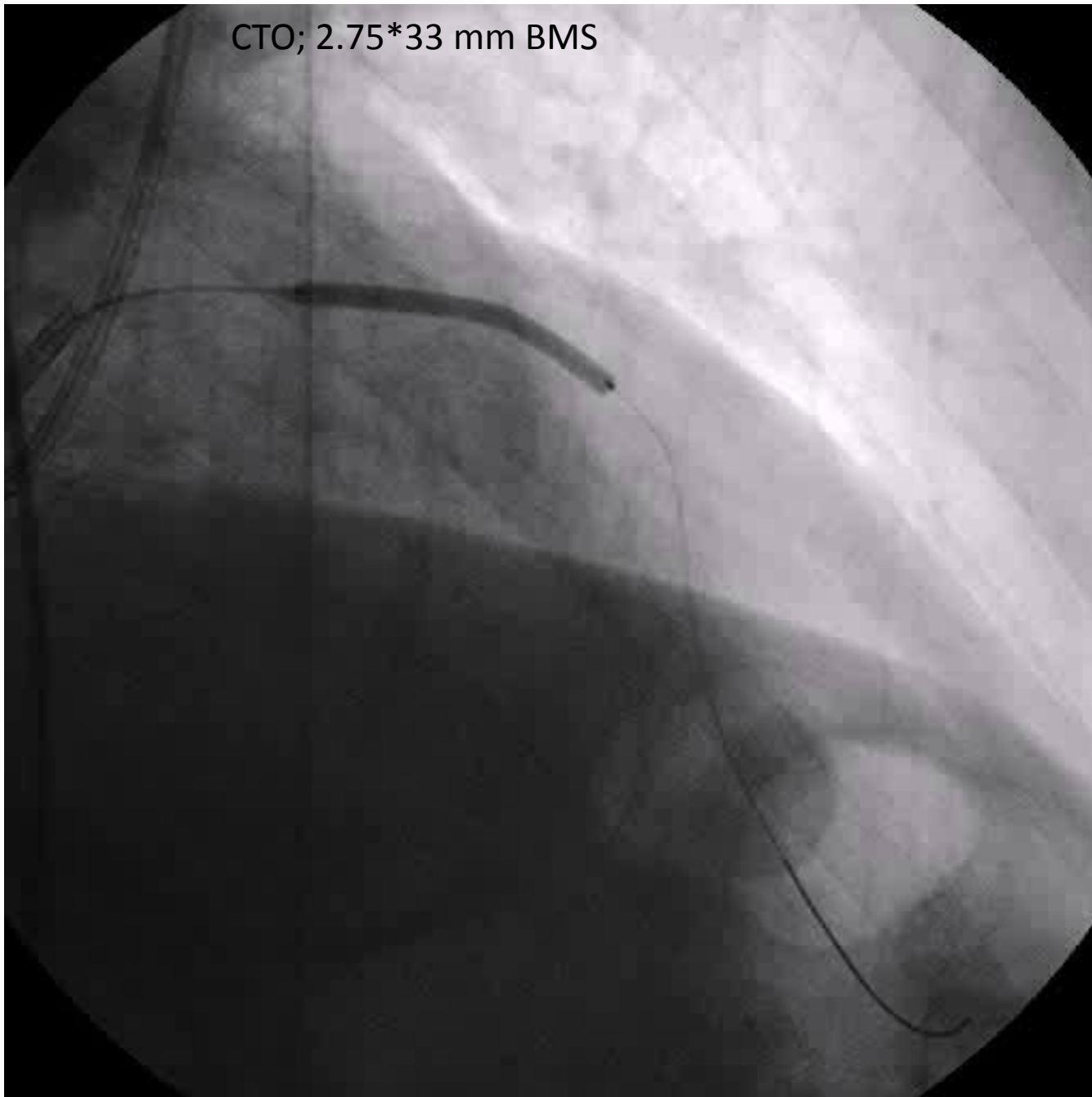CTO; Predilatasyon sonrası KAG



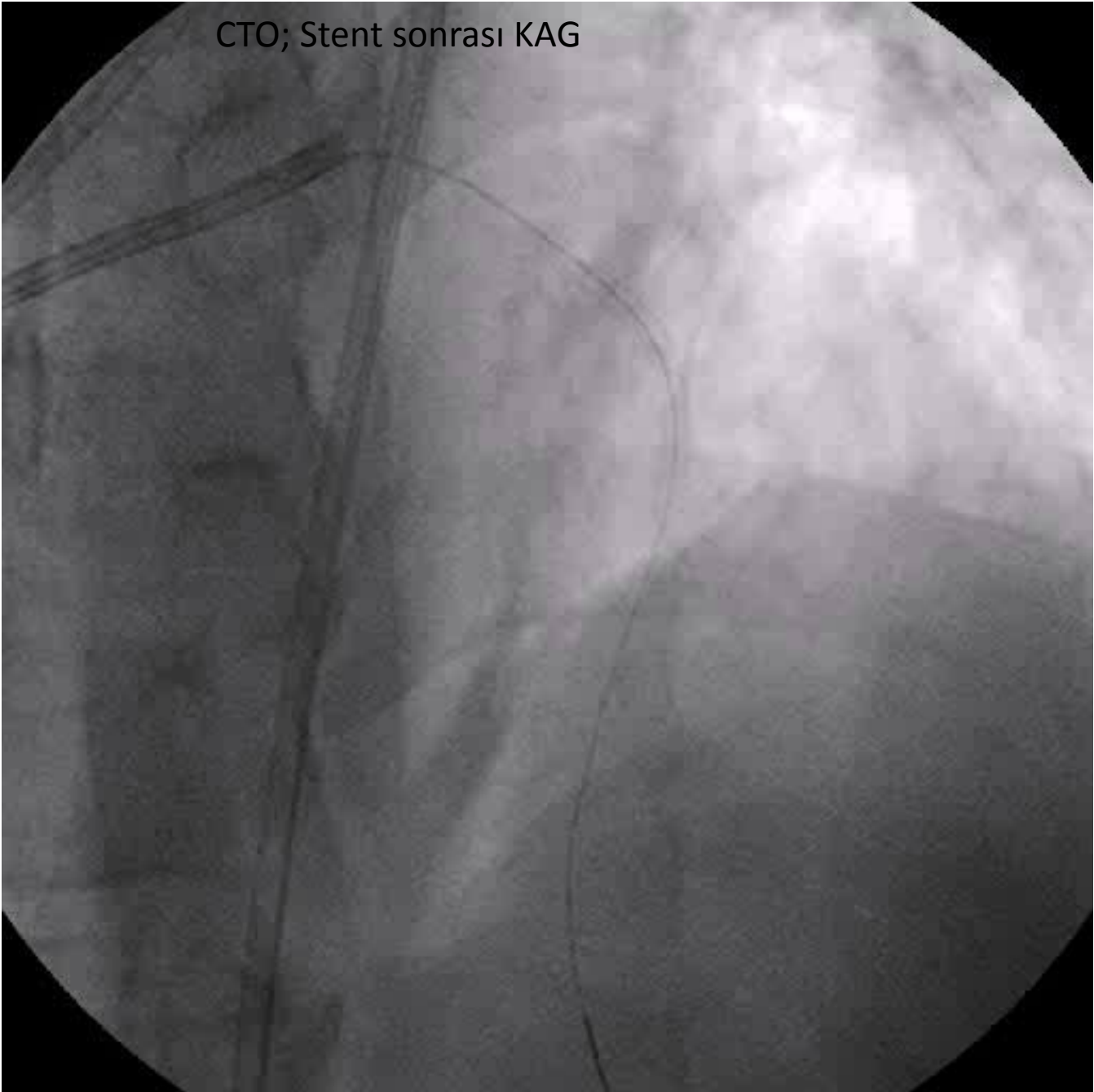CTO; 2.75*33 mm BMS



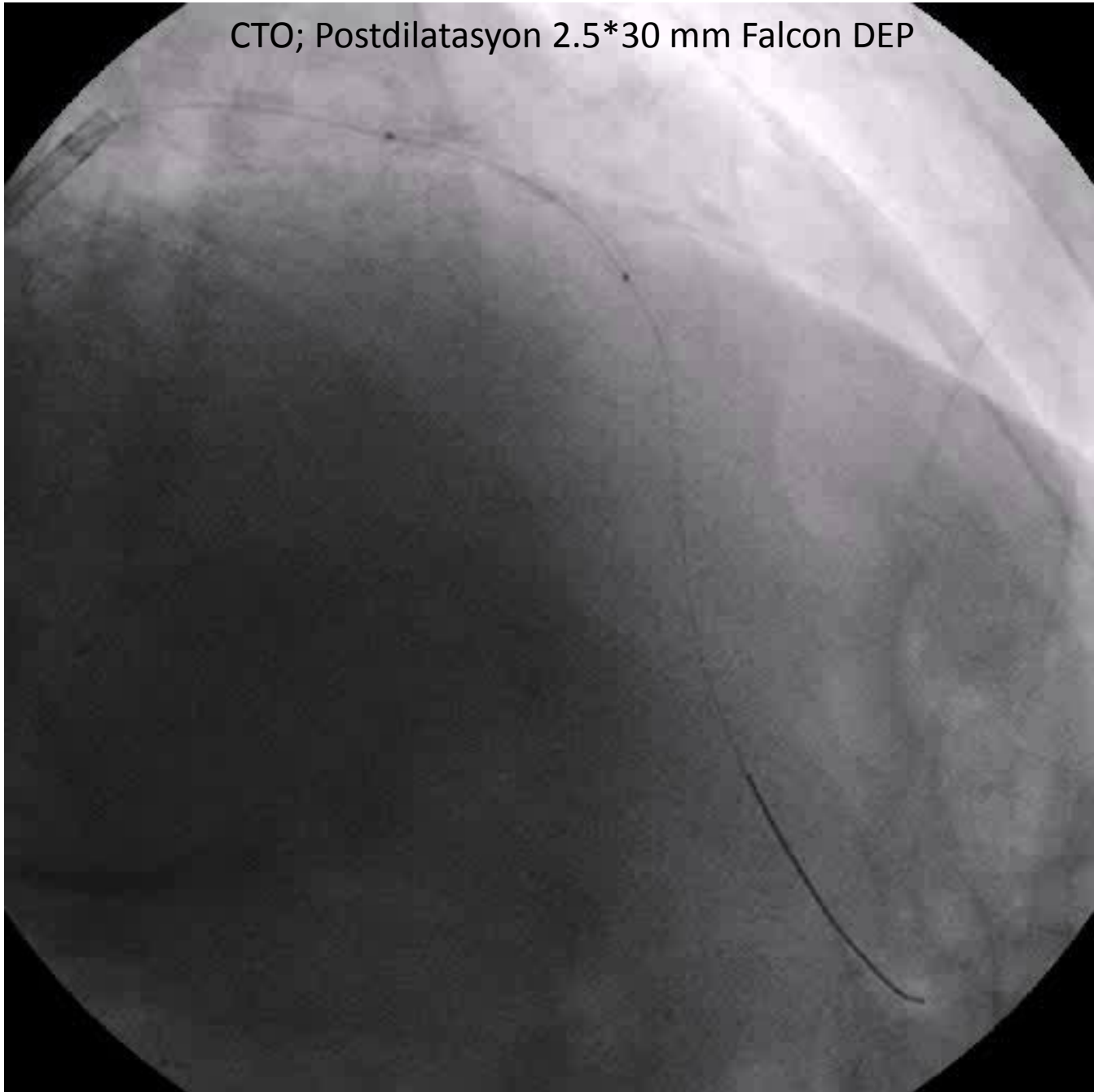
CTO; 2.75*33 mm BMS



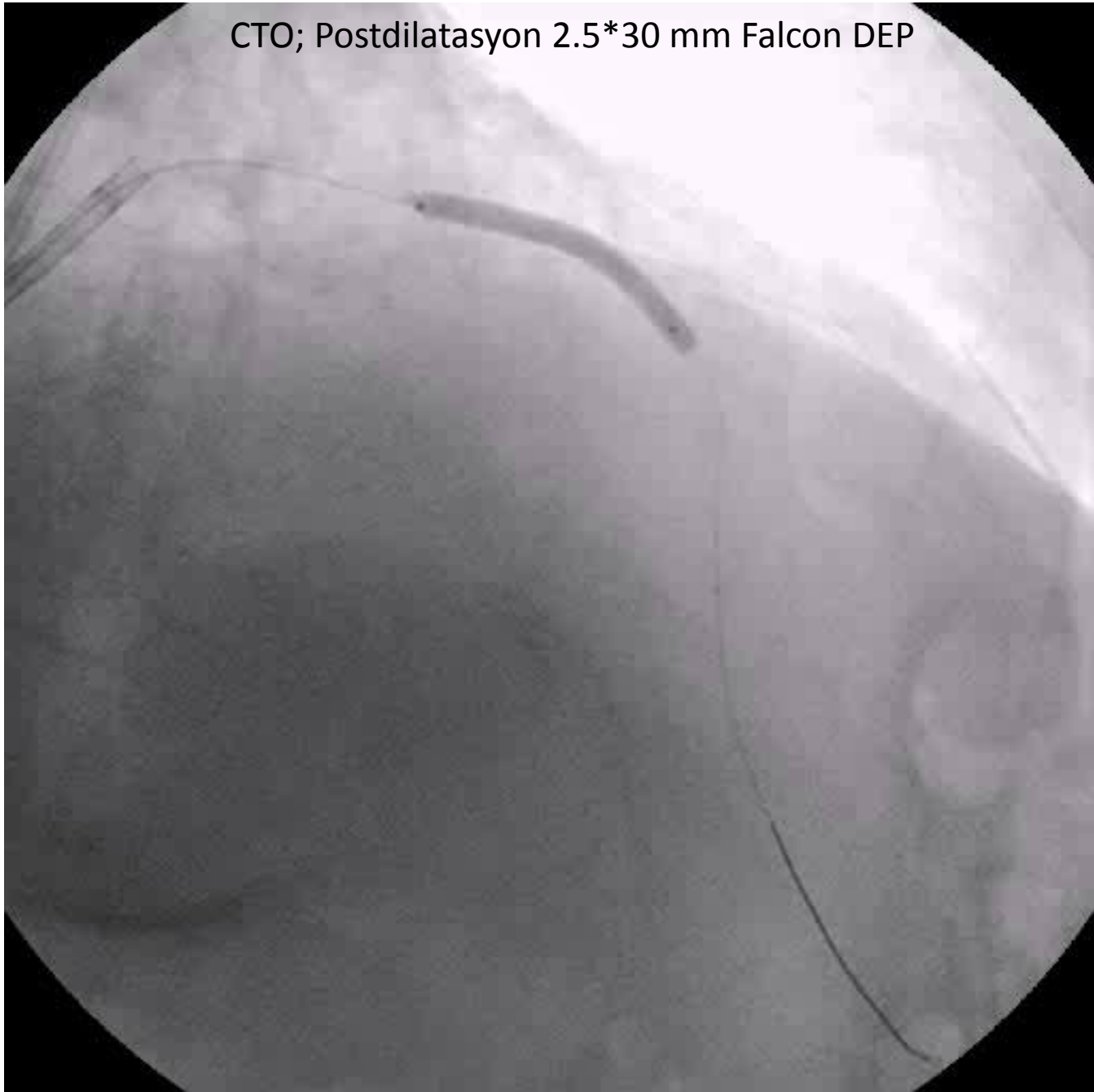
CTO; Stent sonrası KAG



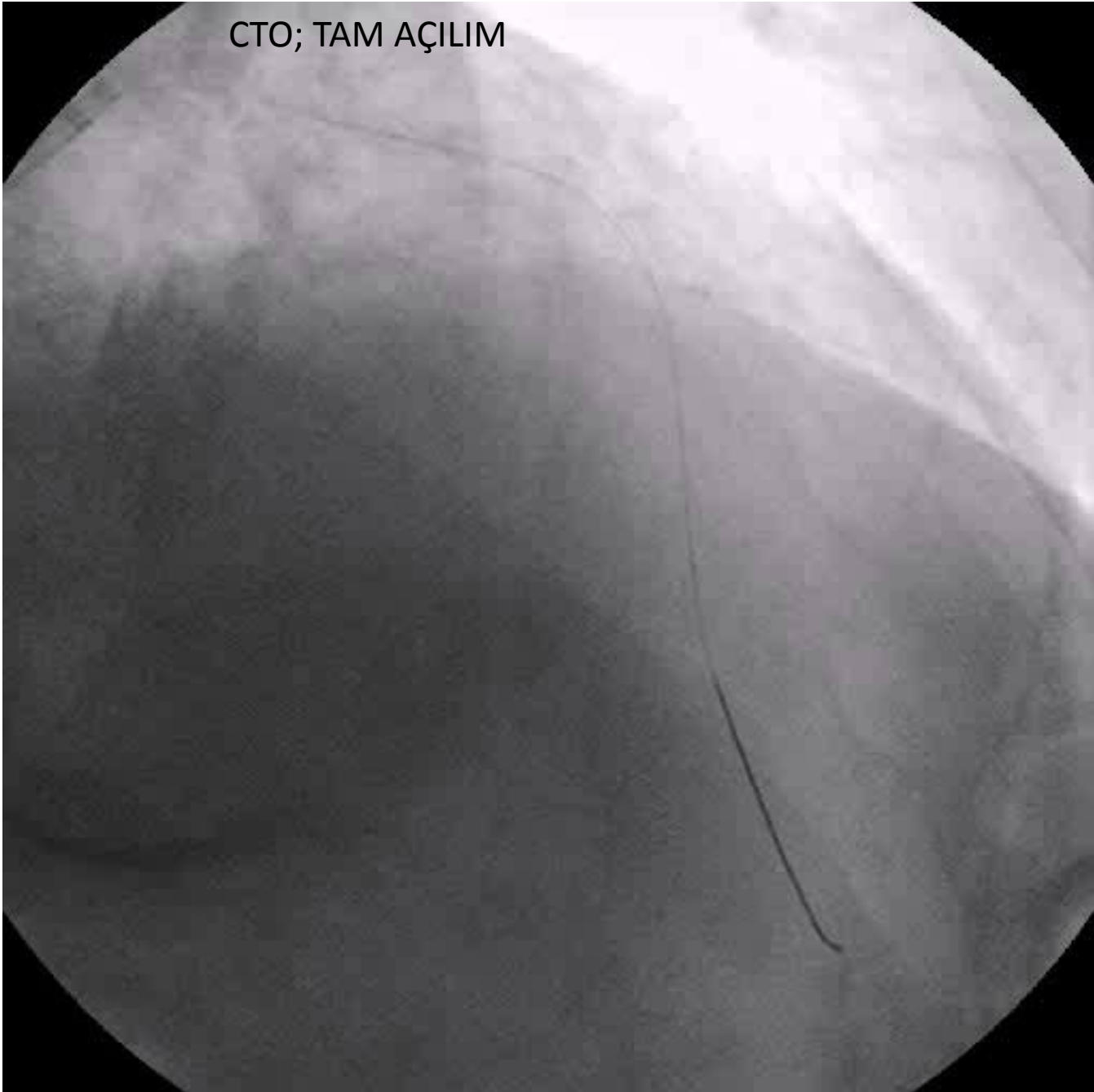CTO; Postdilatasyon 2.5*30 mm Falcon DEP



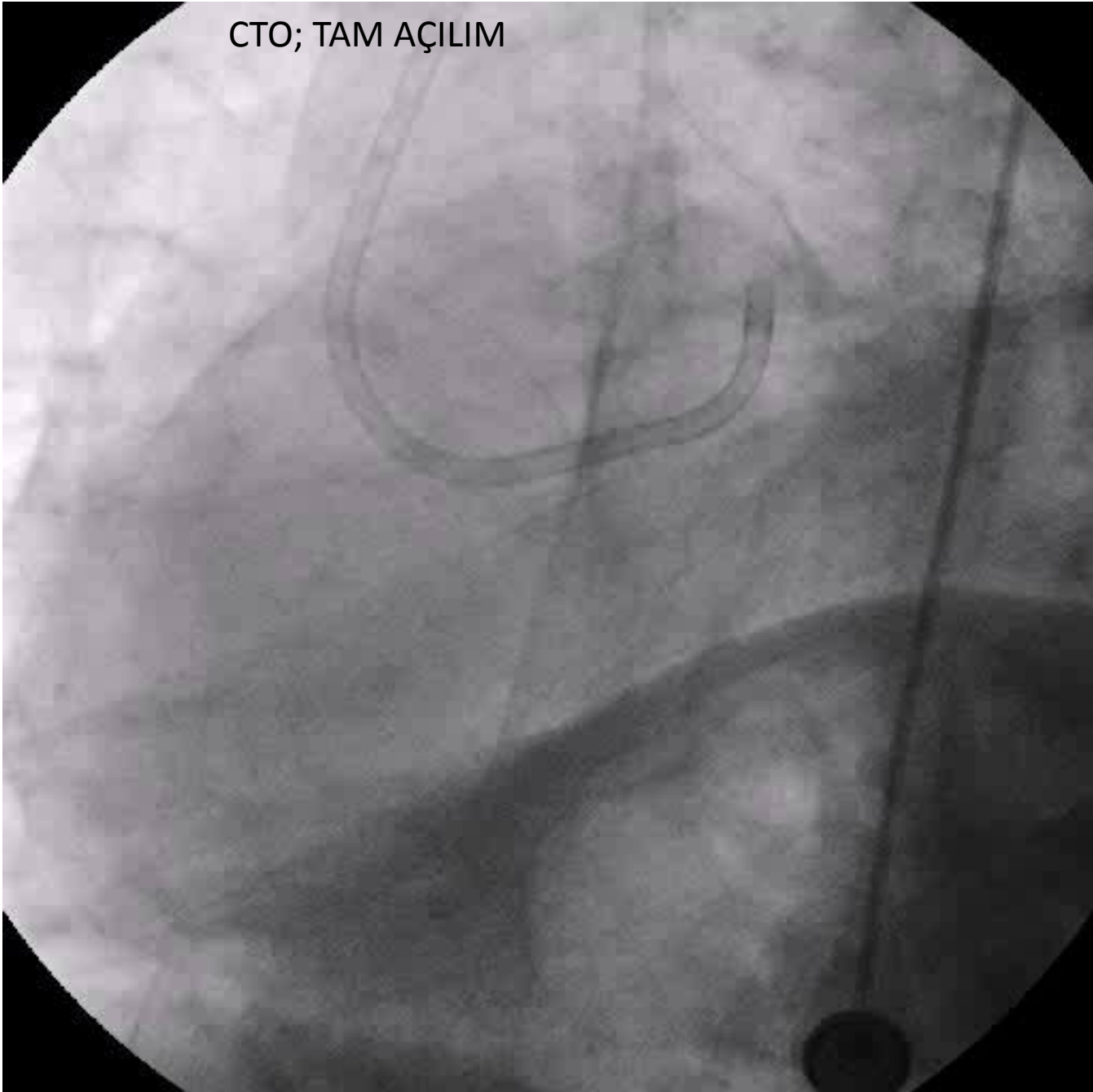CTO; Postdilatasyon 2.5*30 mm Falcon DEP



CTO; TAM AÇILIM



CTO; TAM AÇILIM



19 AY SONRA

- A.INFERİOR POSTERİOR MI

YASAR CUMA
ID: 13/0185-87
17/01/2013
Img: 110000 (1/94)
W/C: 227/113
kV/mA: 95/665

PRİMER PCI ÖNCESİ DİAGNOSTİK KAG

YASAR CUMA
ID: 13/0185-87
17/01/2013
Img: 210000 (1/136)
W/C: 229/114
kV/mA: 105/601

PRİMER PCI ÖNCESİ DIAGNOSTİK KAG

YASAR CUMA
ID: 13/0185-87
17/01/2013
Img: 410000 (1/120)
W/C: 216/108
kV/mA: 125/264

PRİMER PCI ÖNCESİ DIAGNOSTİK KAG

YASAR CUMA
ID: 13/0185-87
17/01/2013
Img: 510000 (1/108)
W/C: 224/112
kV/mA: 79/800

PRİMER PCI ÖNCESİ DİAGNOSTİK KAG

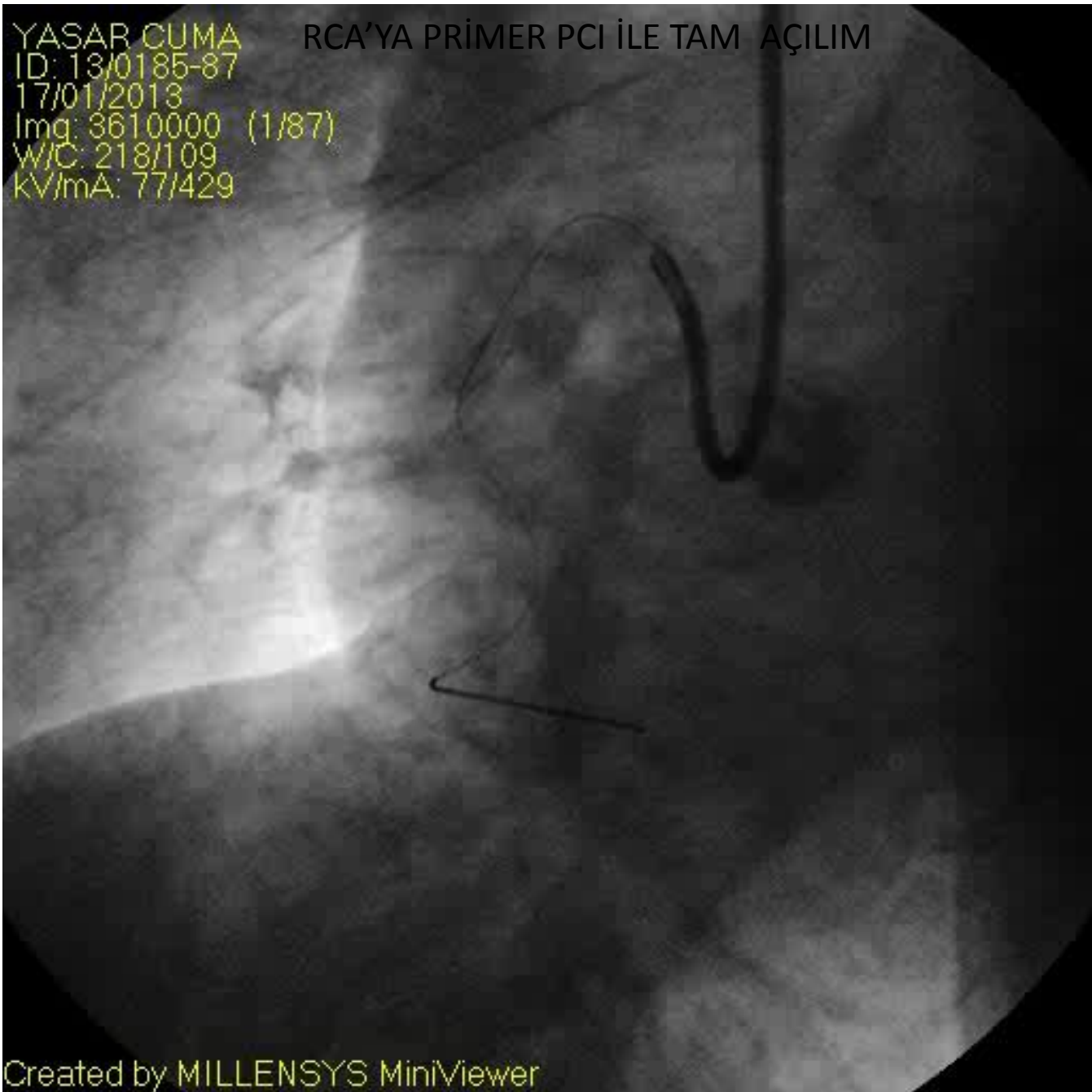
YASAR CUMA PRİMER PCI ÖNCESİ DIAGNOSTİK KAG
ID: 13/0185-87
17/01/2013
Imj: 610000 (1/118)
W/C: 159/79
kV/mA: 87/379

KARAR

- RCA PRİMER PCI
- LAD STENT ÖNCESİ DİSSEKE LEZYONA ELEKTİF PCI

YASAR CUMA
ID: 13/0185-87
17/01/2013
Img: 3610000 (1/87)
W/C: 218/109
kV/mA: 77/429

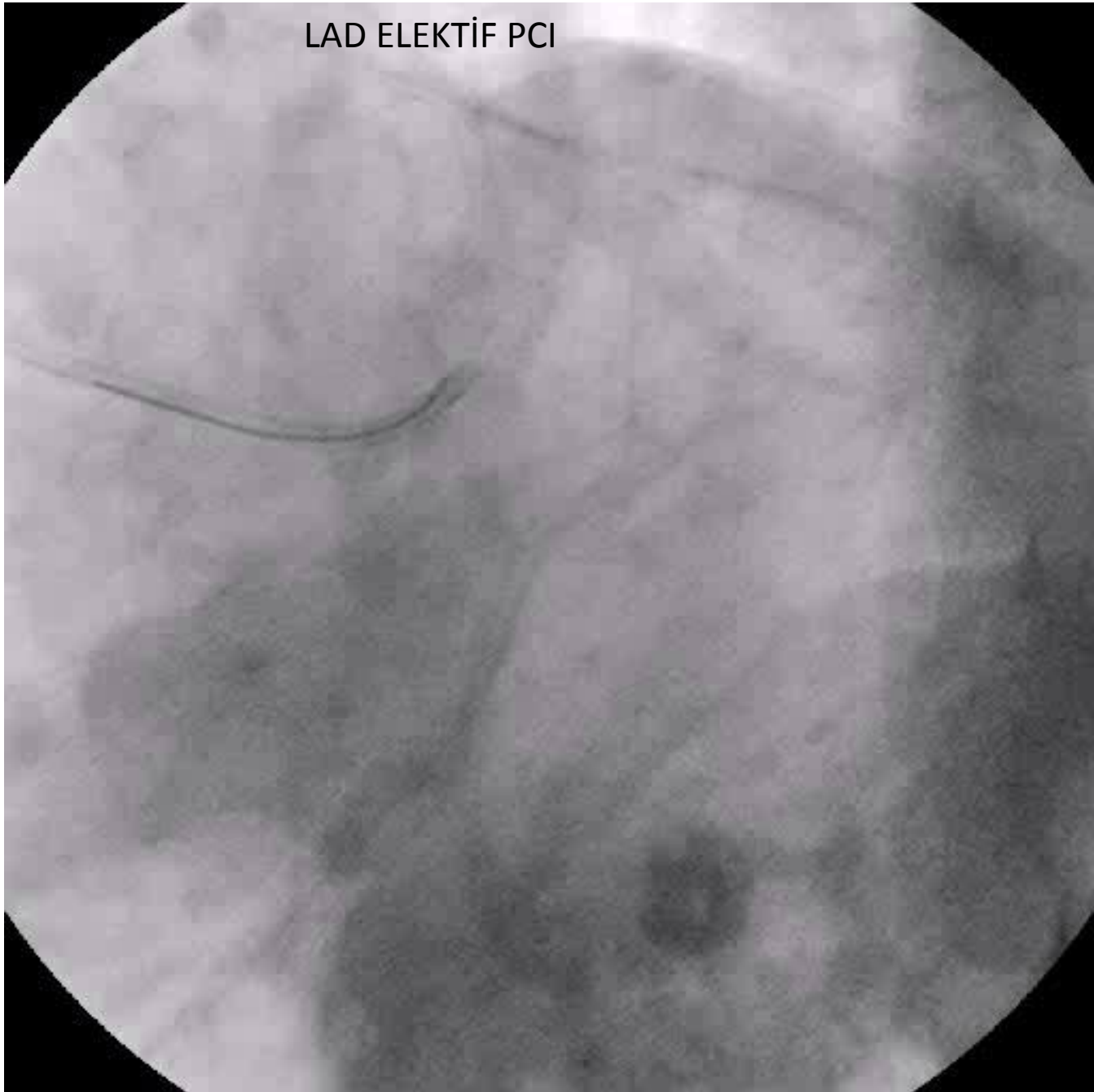
RCA'YA PRİMER PCI İLE TAM AÇILIM



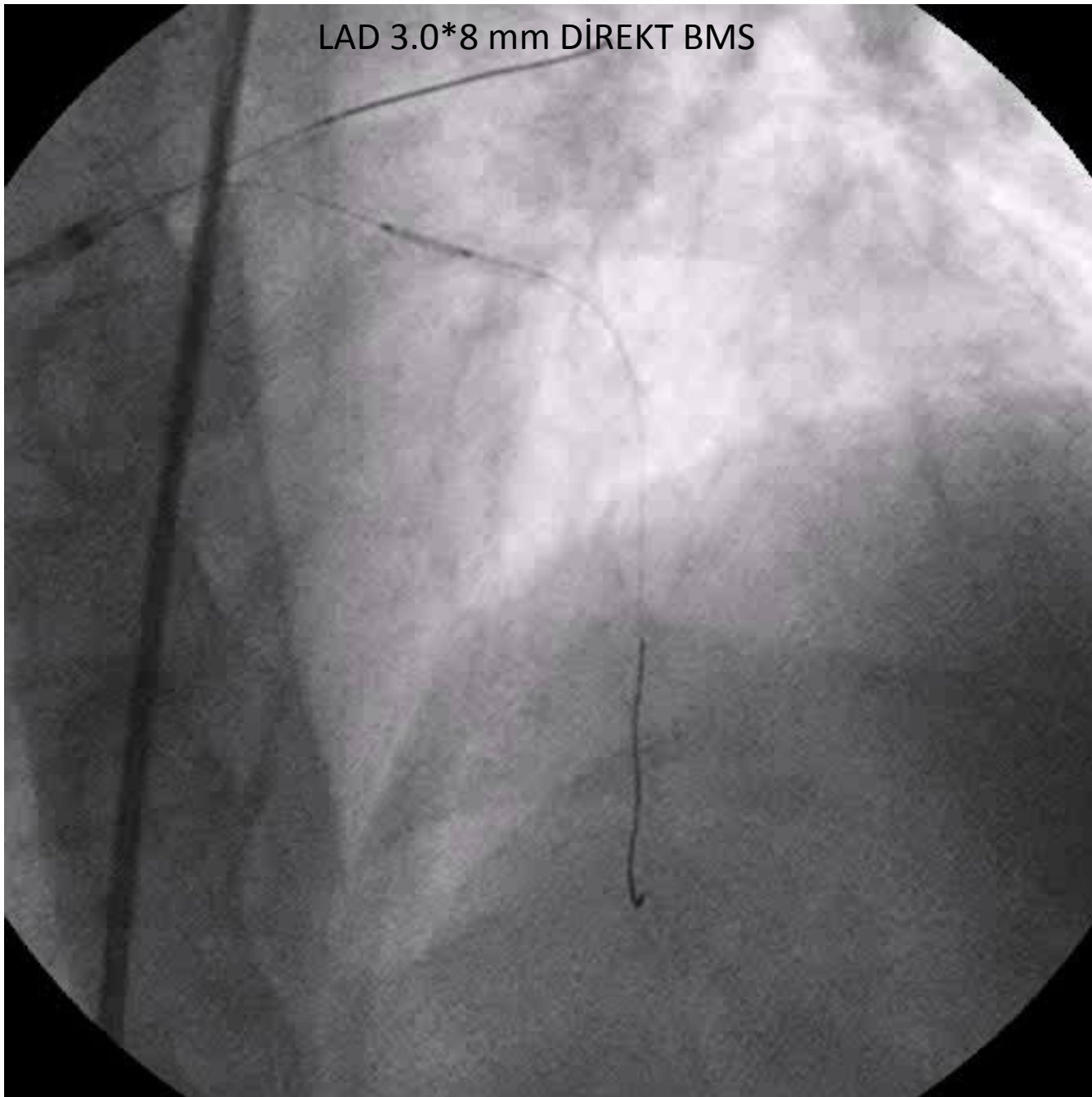
YASAR CUMA
ID: 13/0185-87
17/01/2013
Img: 3710000 (1/70)
W/C: 226/113
KV/mA: 85/388

RCA'YA PRİMER PCI İLE TAM AÇILIM

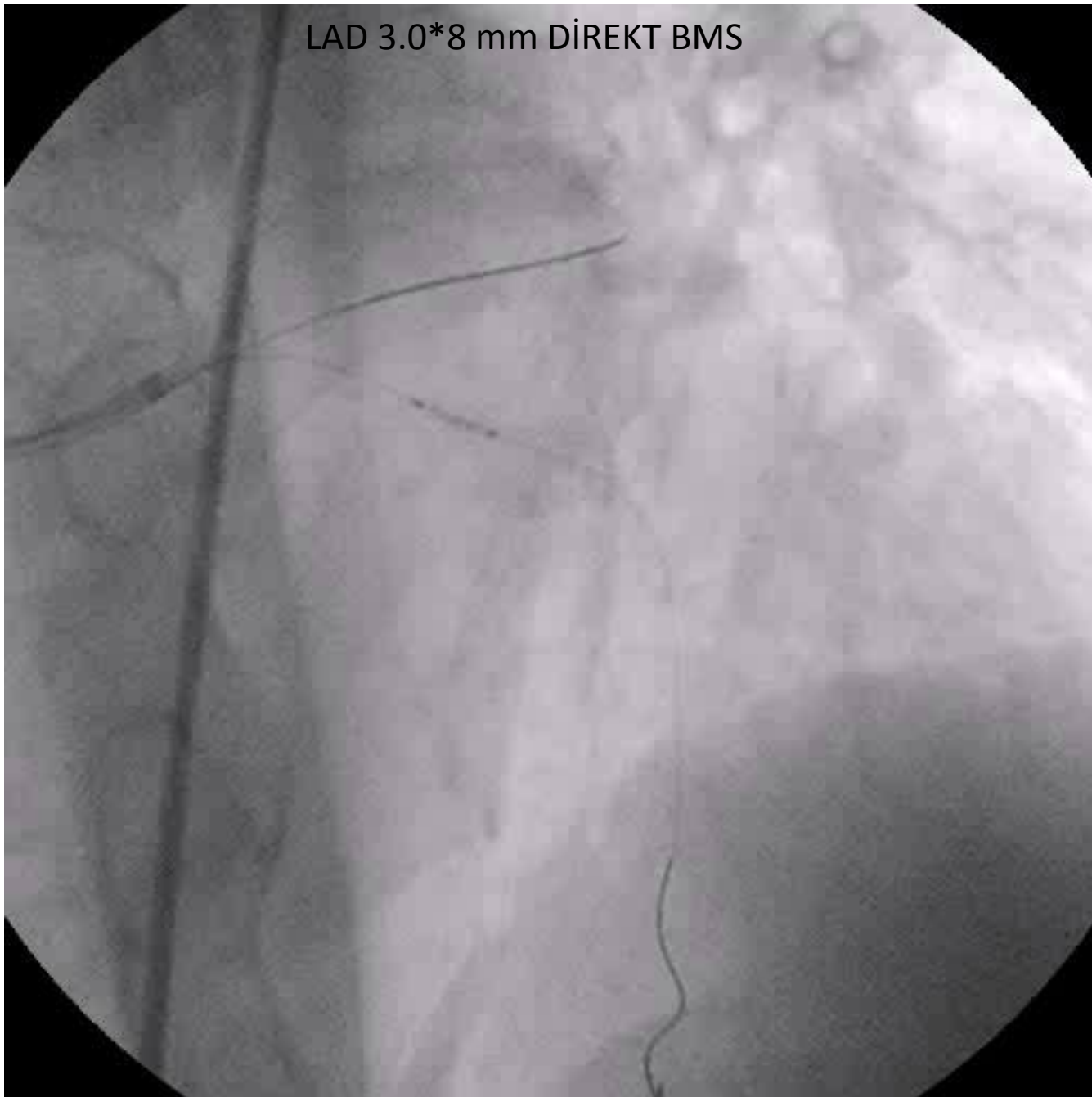
LAD ELEKTİF PCI



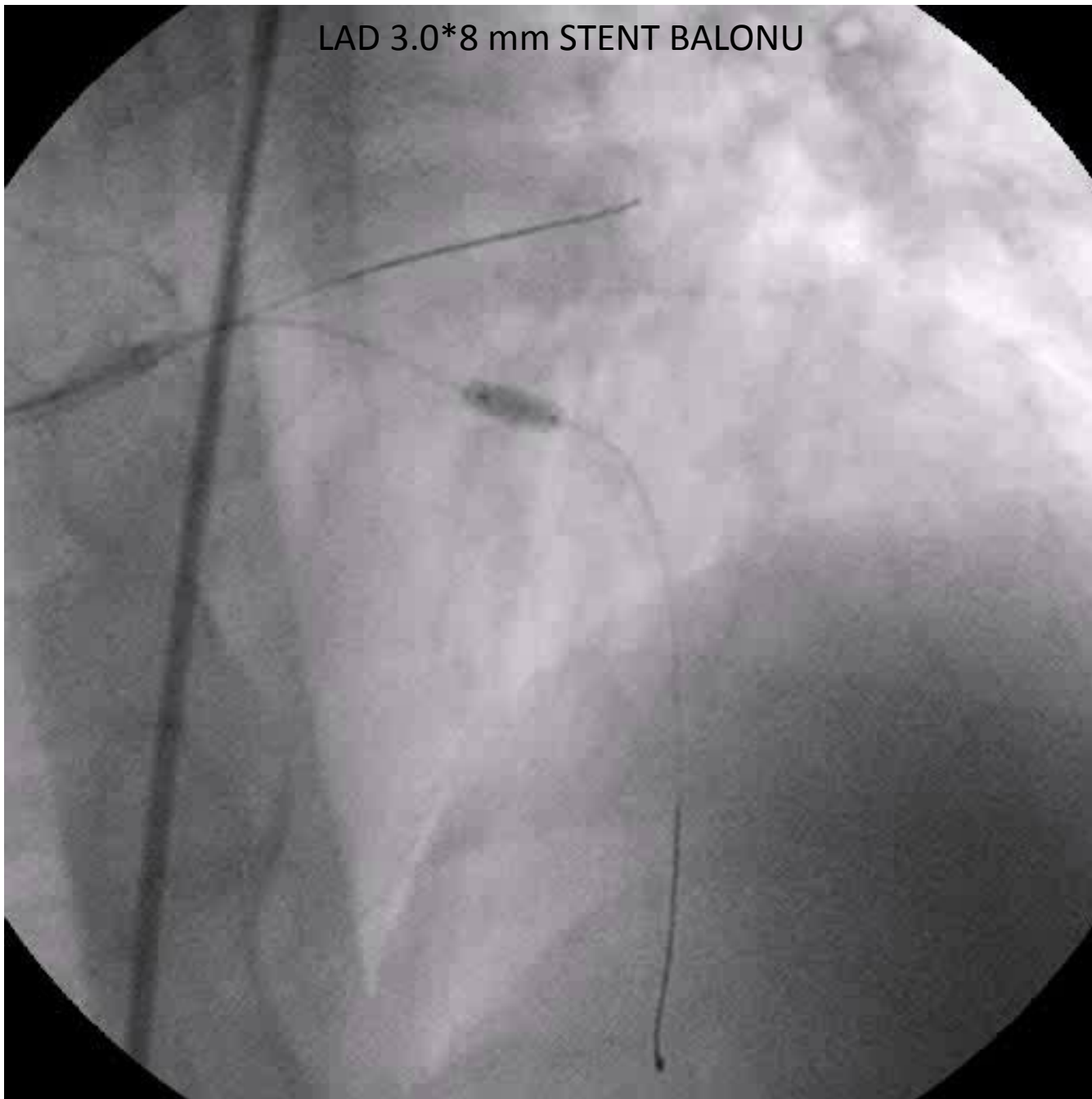LAD 3.0*8 mm DİREKT BMS



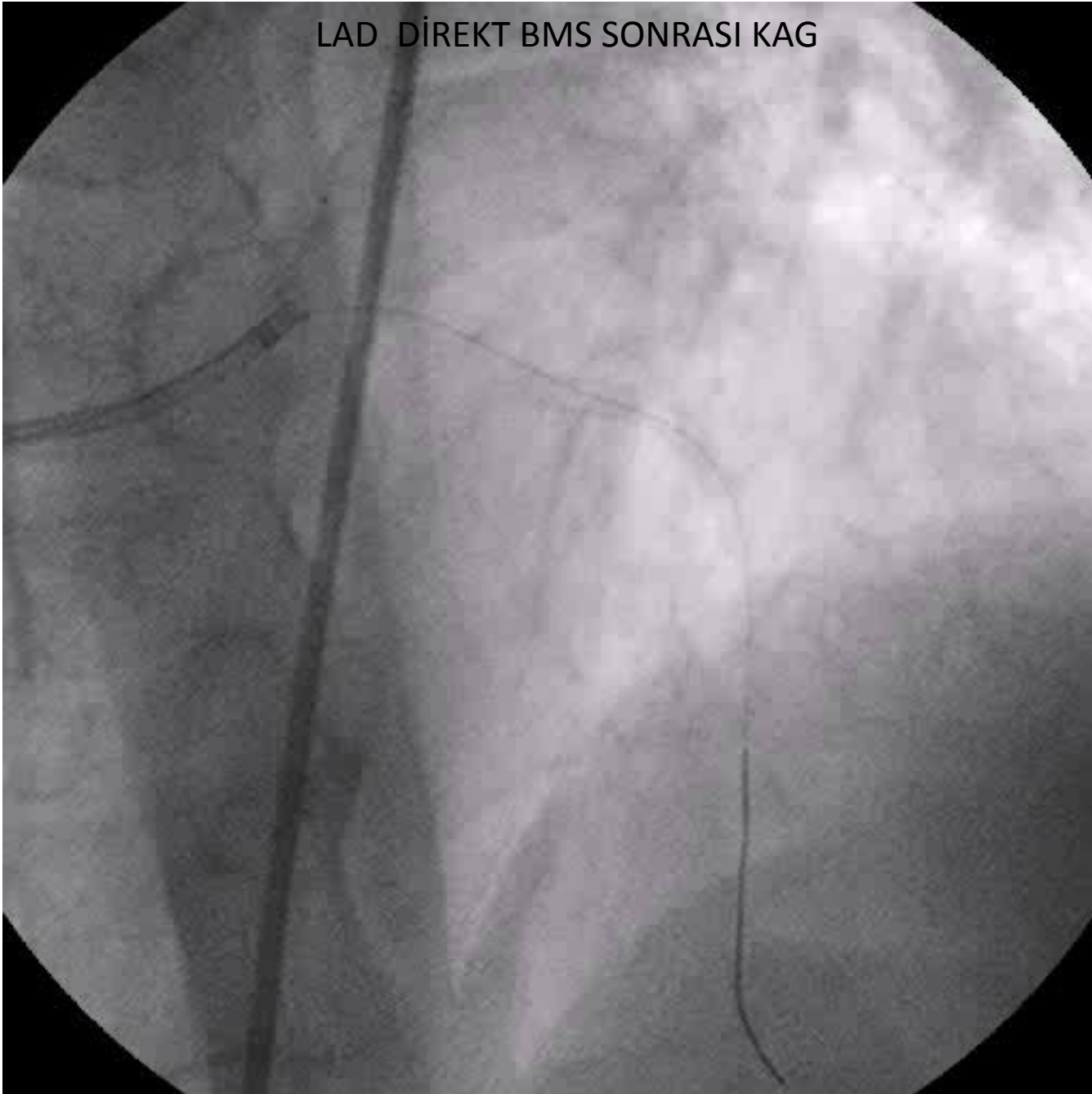
LAD 3.0*8 mm DİREKT BMS



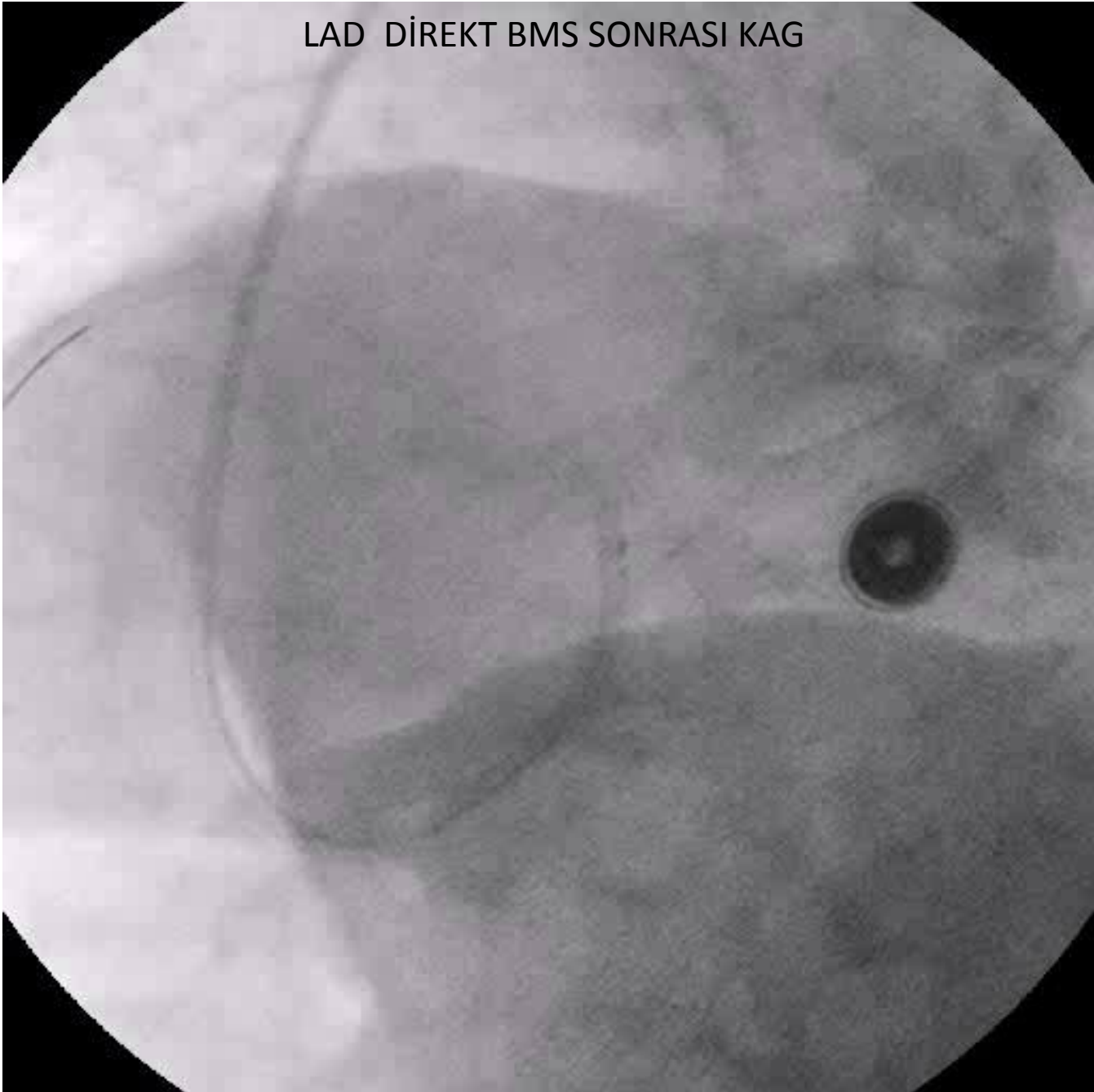LAD 3.0*8 mm STENT BALONU



LAD DİREKT BMS SONRASI KAG



LAD DİREKT BMS SONRASI KAG



- TEŞEKKÜR EDERİM.....