

RETROGRAD BAŐLANIP ANTEGRAD DEVAM EDİLEN KTO VAKASI

Prof. Dr Vedat AYTEKİN

Doç. Dr Refik ERDİM

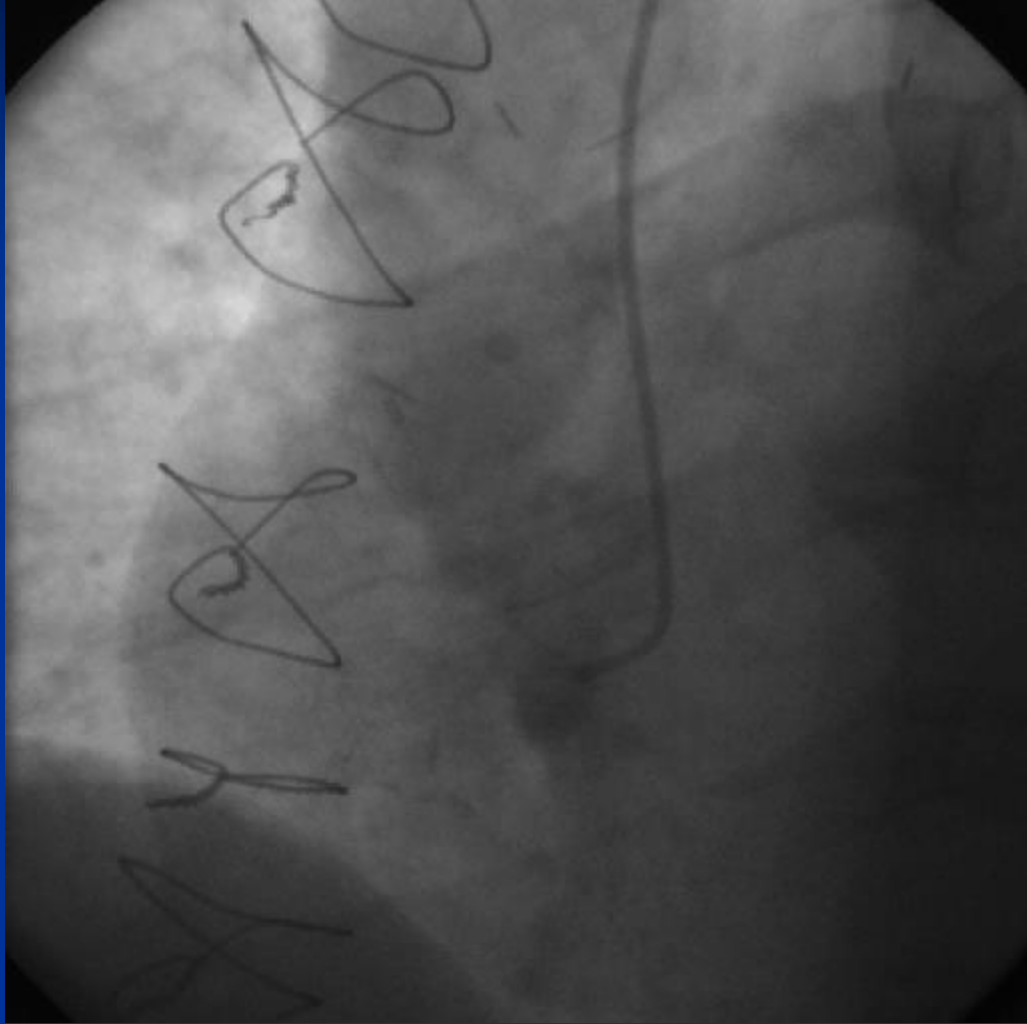
ŐiŐli Florence Nightingale Hastanesi

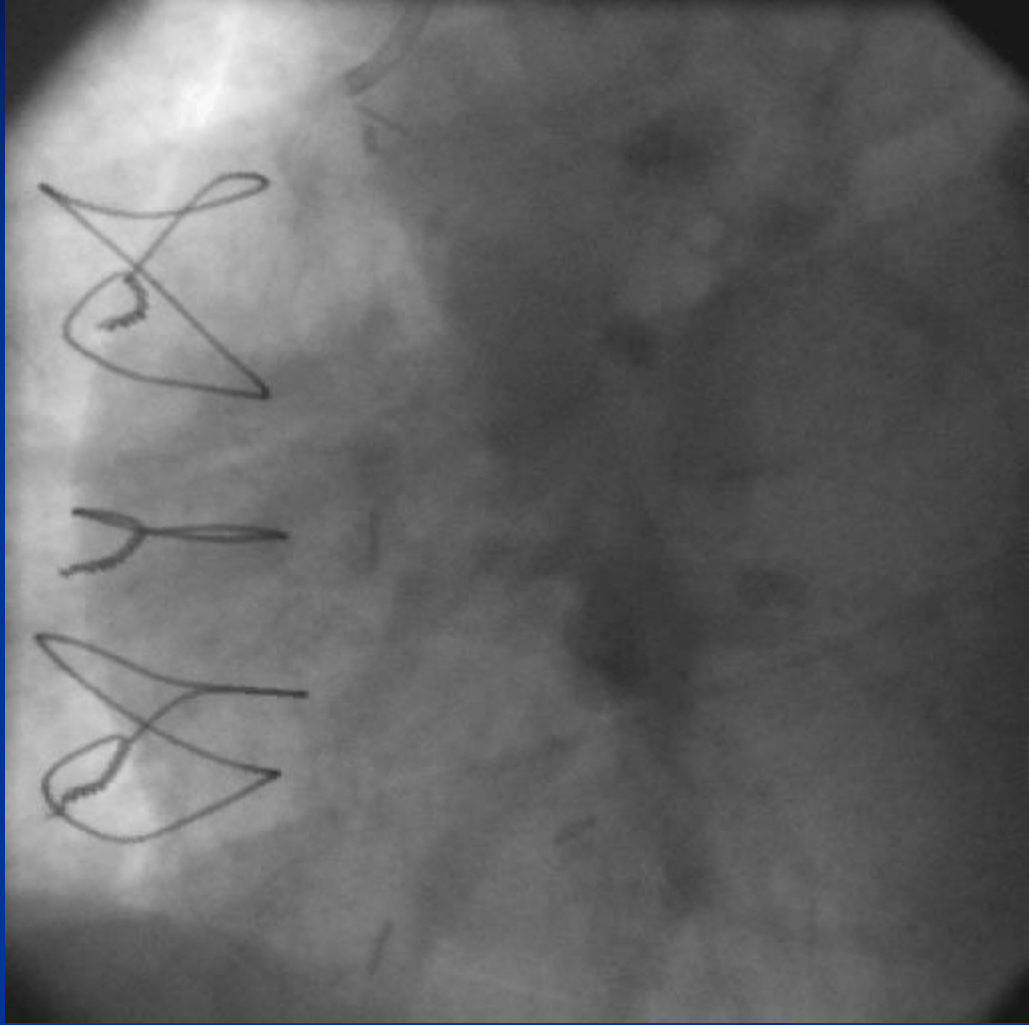


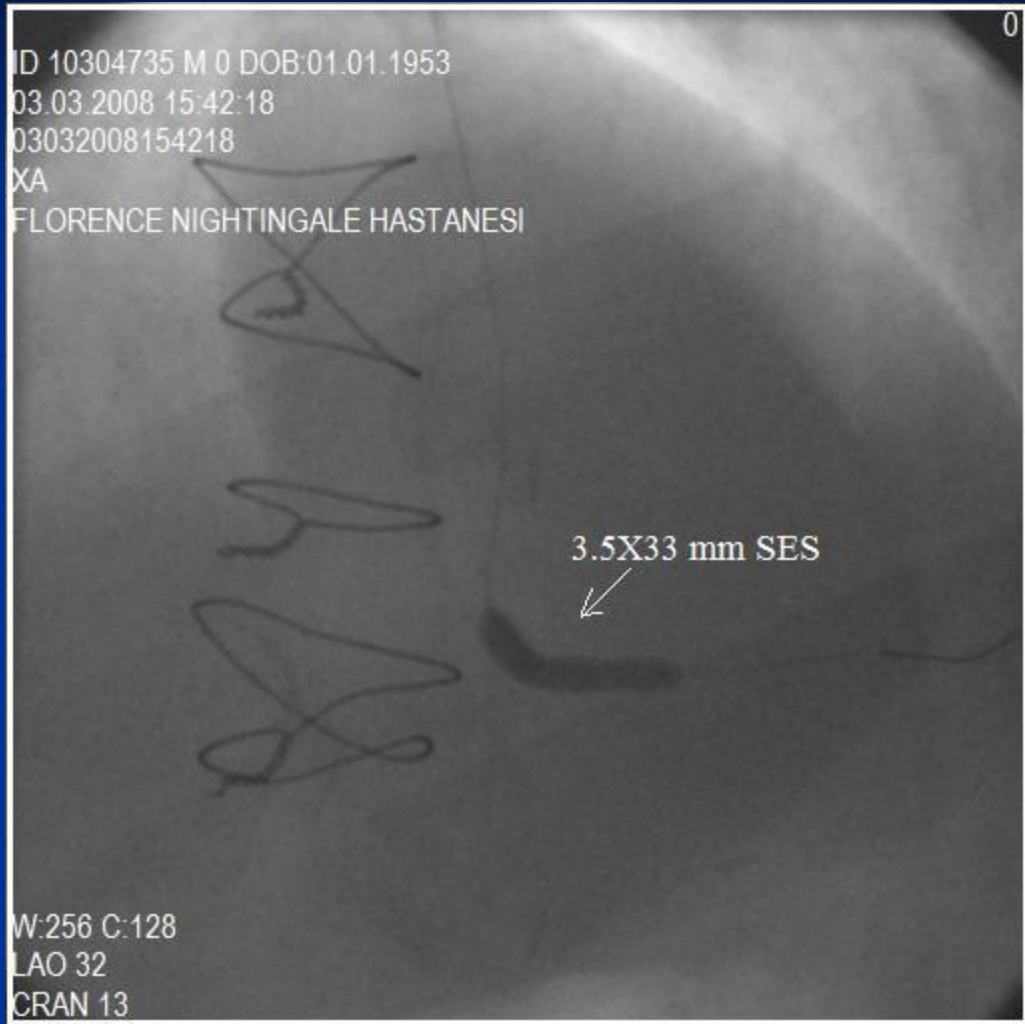
- 60 yaşında erkek hasta
- Minimal eforla göğüs ağrısı tarifliyor (CCS Klas III).
- FM:Doğal
- Özgeçmiş: HT,DM tip II,HL
- Lab: Krea 0.9 mg/dl(GFR:91 ml/min)
- EKO: EF %45 İinferior ve inferolateral hipokinezi

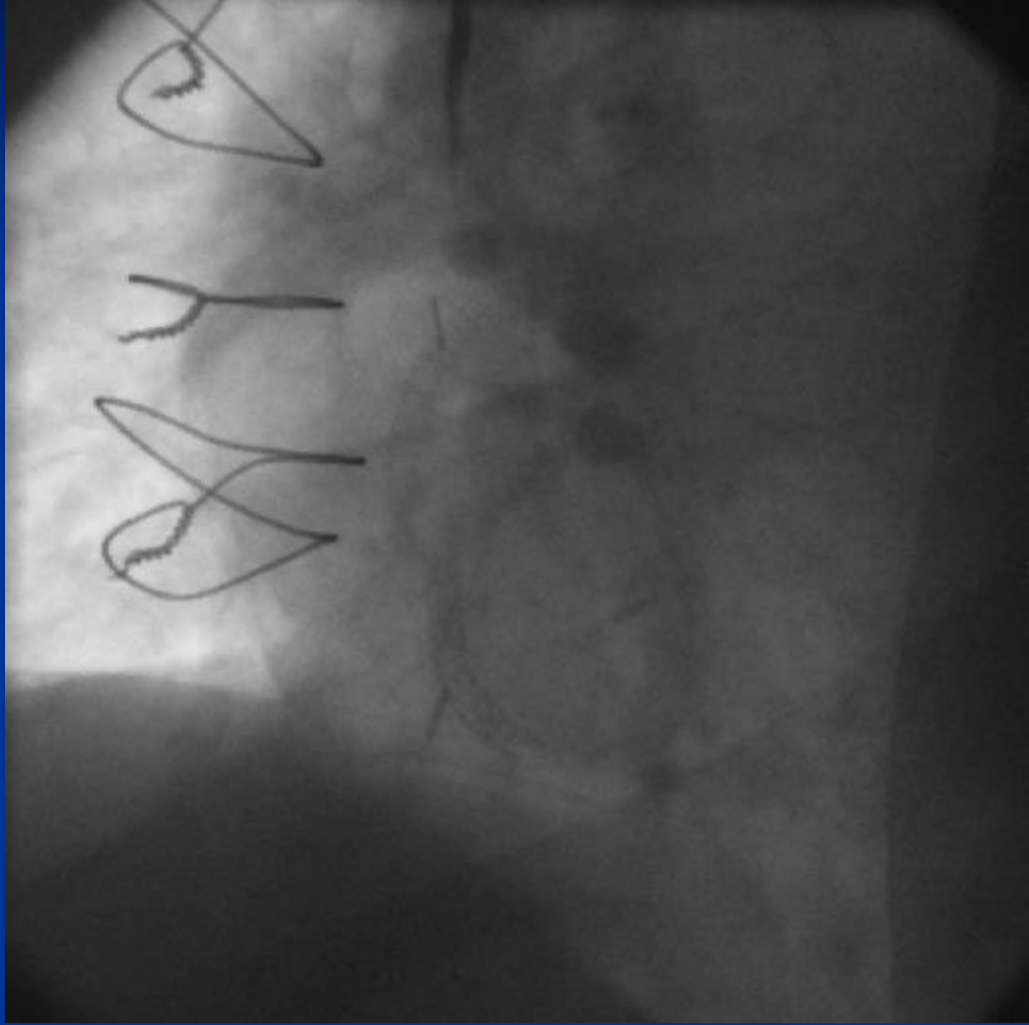
- 2001 yılında RCA,LAD ve OM dala PTCA+Stent implantasyonu yapılmış.
- 2002 yılında CABG (LIMA-LAD, Ao-IM, Ao-RCA, Ao-Cxa)+Sağ karotis endarterektomi operasyonu.

- 2008 yılında Ao-RCA greft distaline Cutting balon anjiyoplasti ve Sirolimus salınımlı stent (3.5x33 mm) implantasyonu.

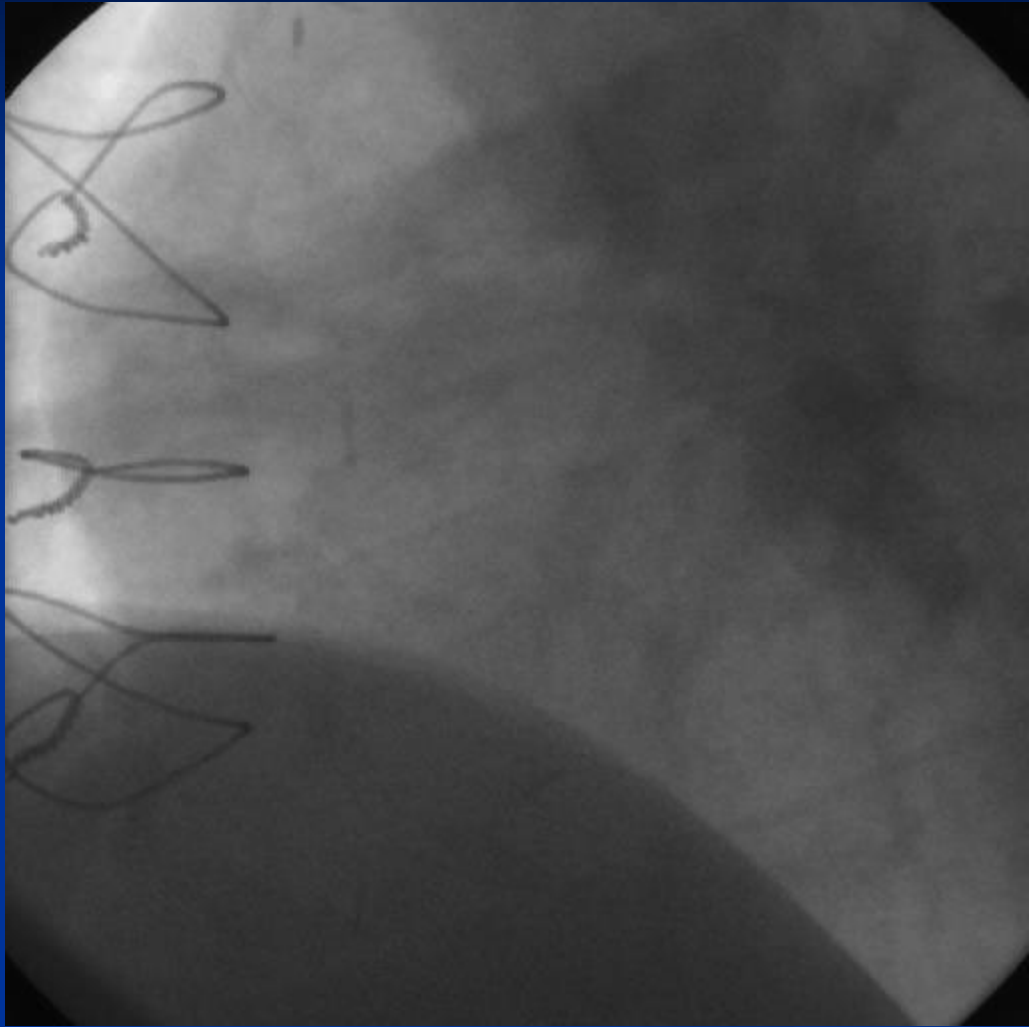


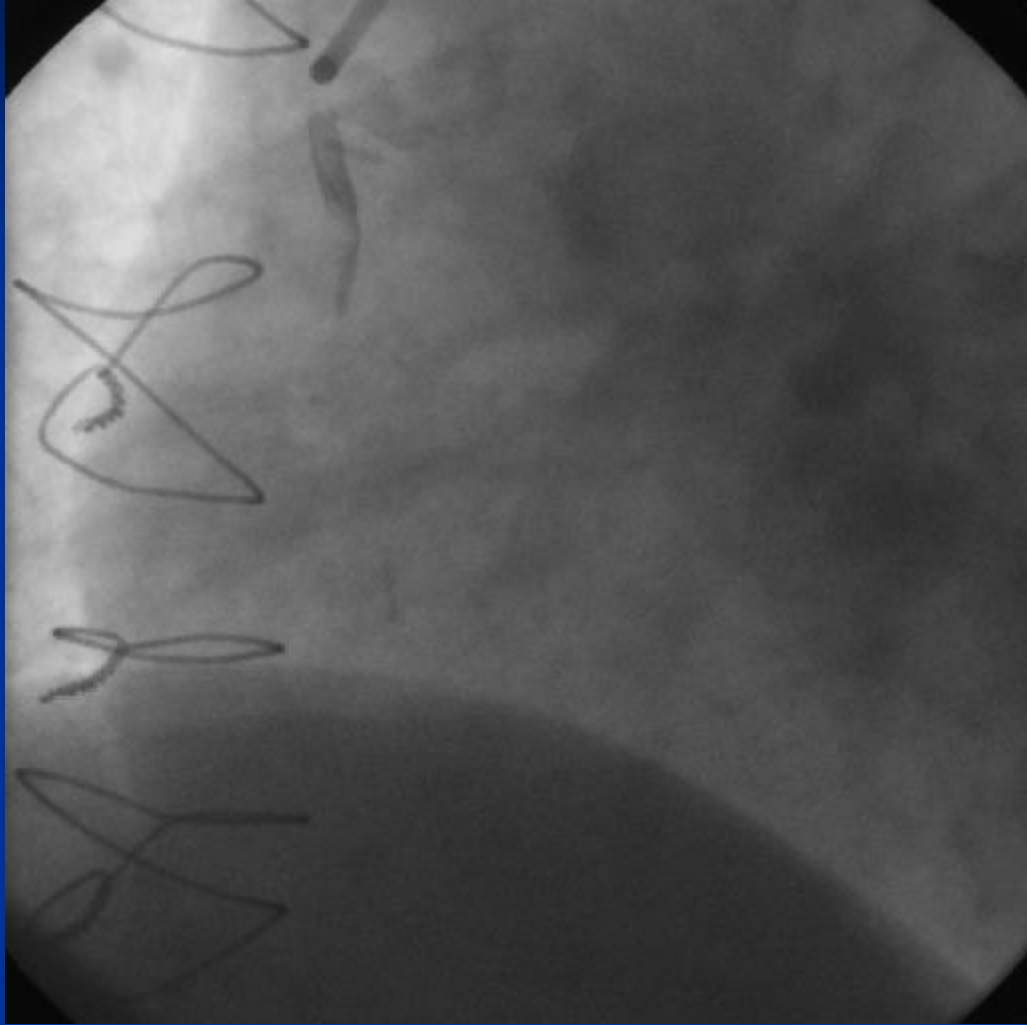






- 01/2012 de Ao-RCA stent restenozuna 3.5 mm NC balon dilatasyonu

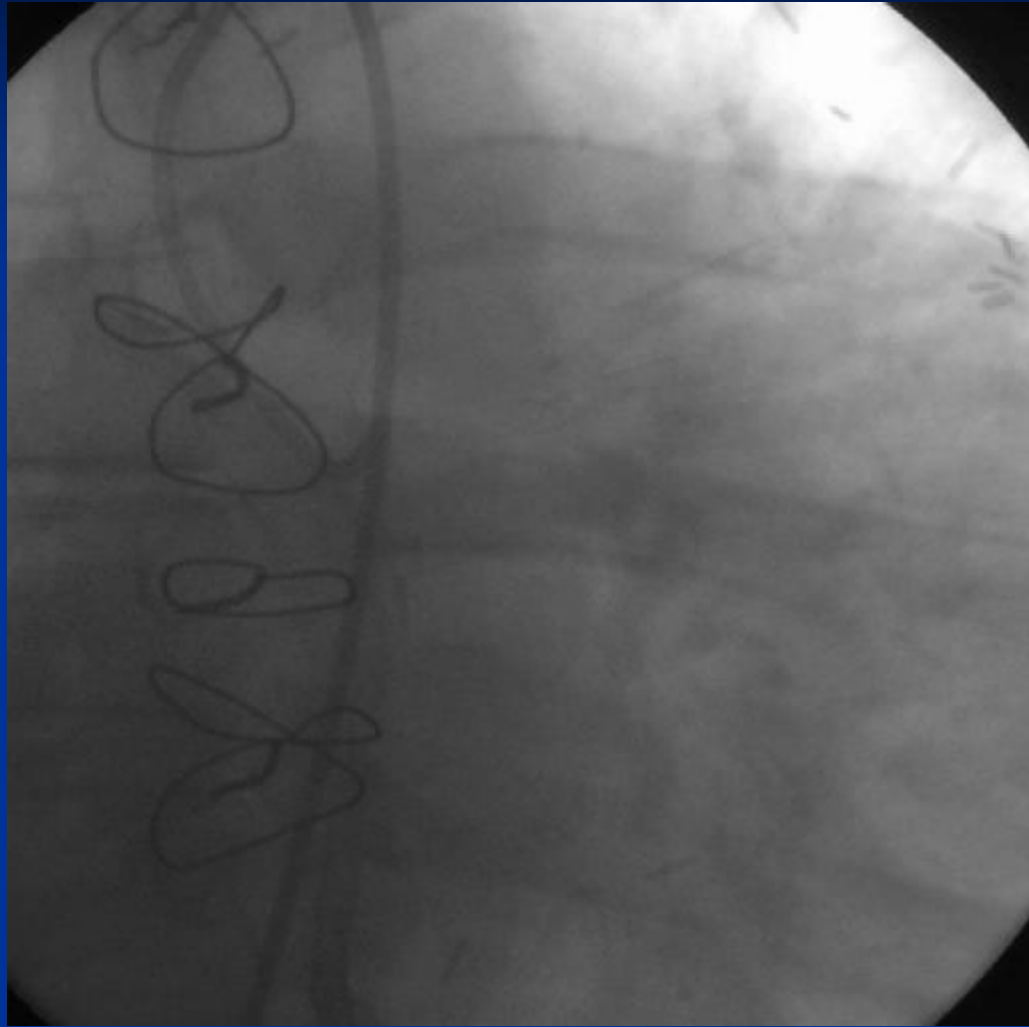


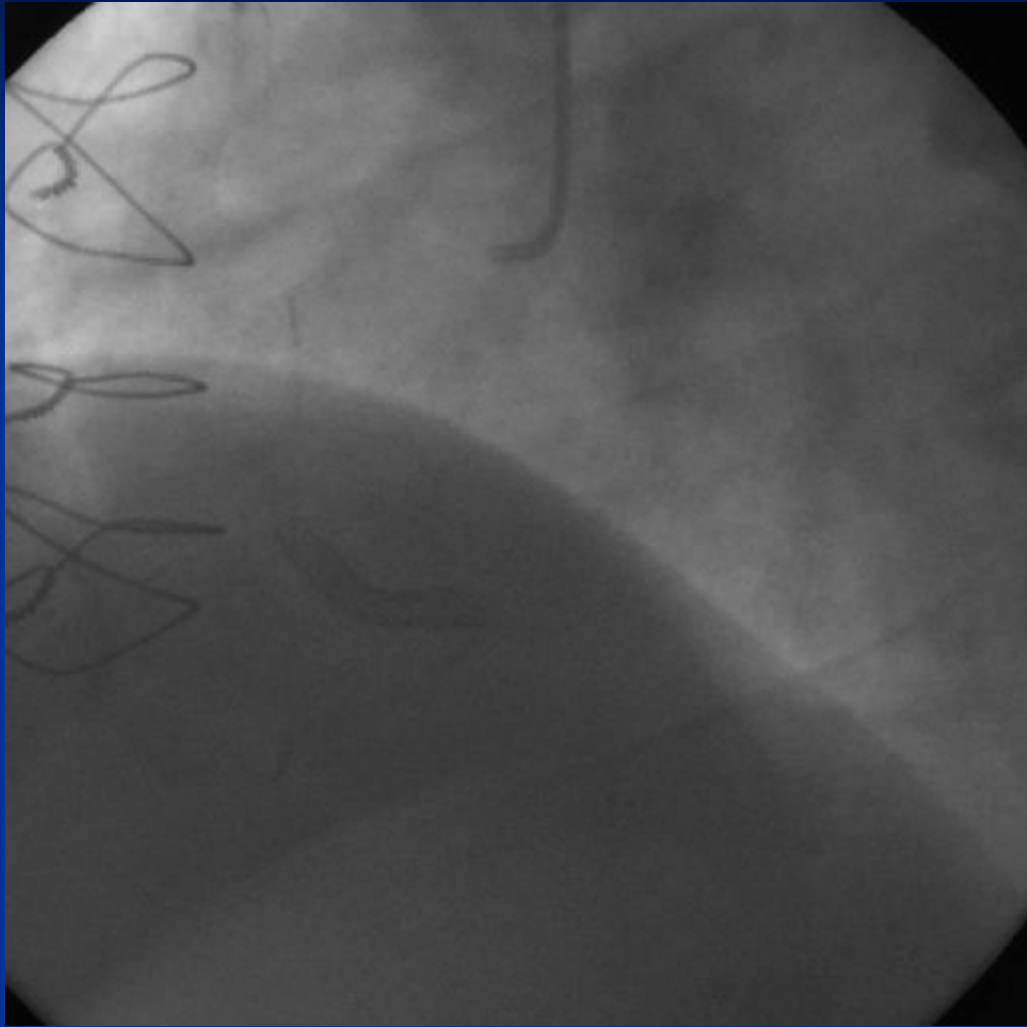


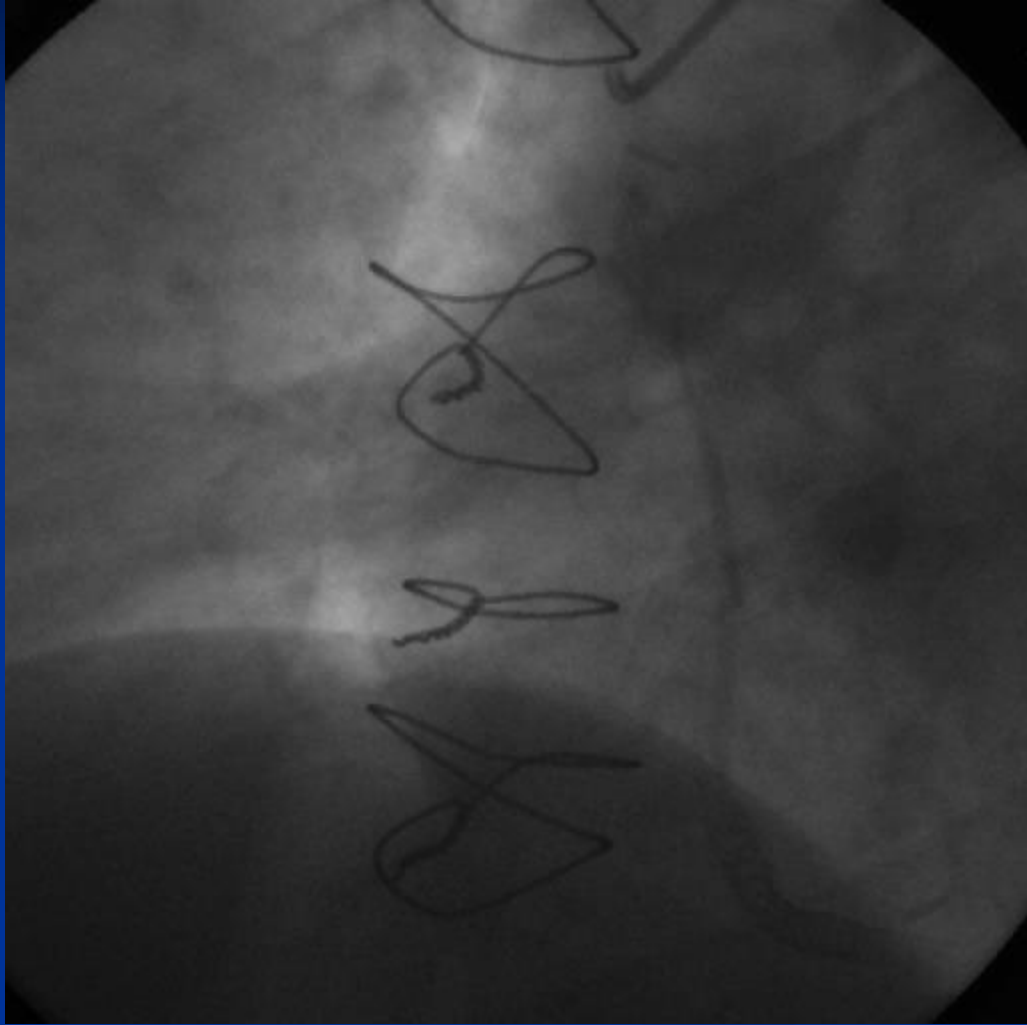
- 04/2012 restenoz sebebiyle Ao-RCA greft stent içi restenozuna 3.0x28 mm Biolimus salınımlı stent implantasyonu)
- 08/2012 restenoz sebebiyle Ao-RCA greft stent içi restenozuna 3.5x26 mm Sirolimus salınımlı stent implantasyonu

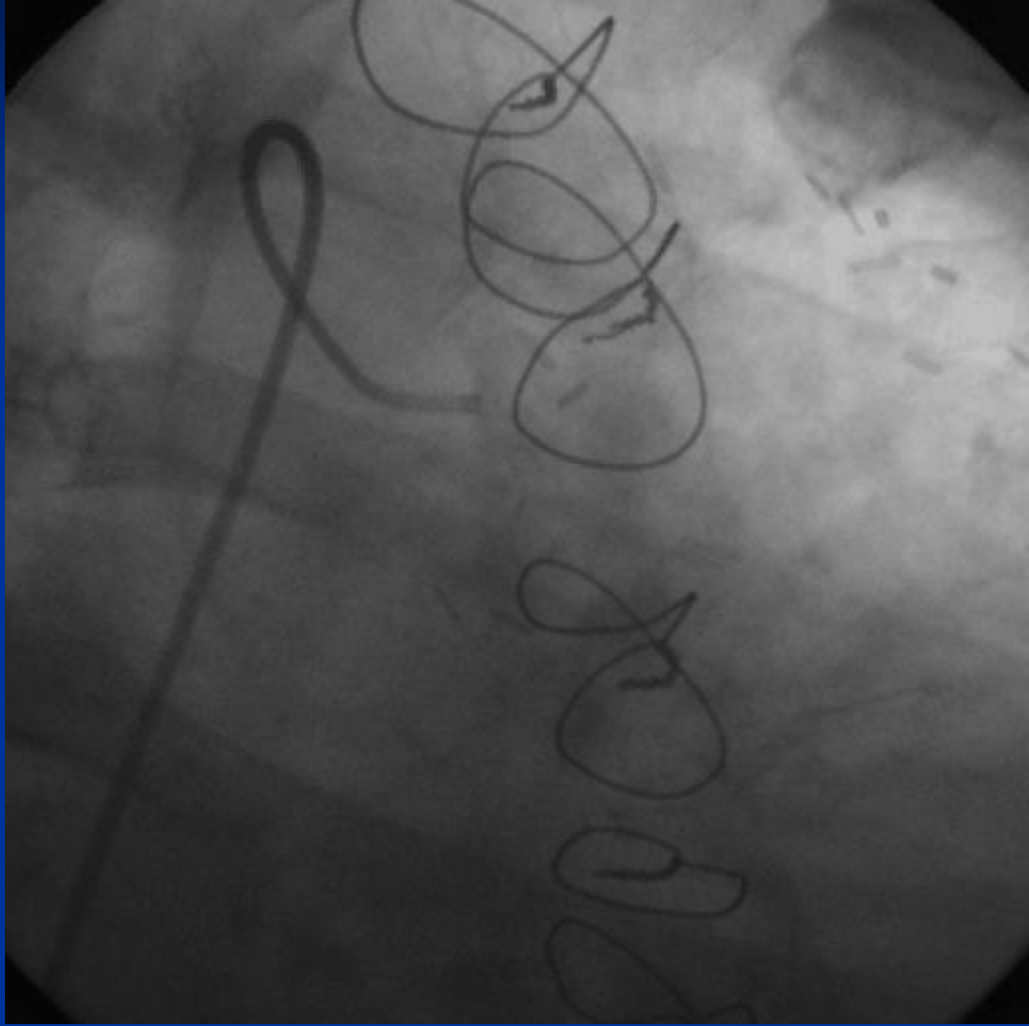
- 12/2012 de Ao-RCA greft proksimal 3,5mmx23mm Biolimus salınımlı ilaçlı stent, Ao-RCA greft distal restenoz lezyonuna 3,5mmx38mm Everolimus salınımlı ilaçlı stent.

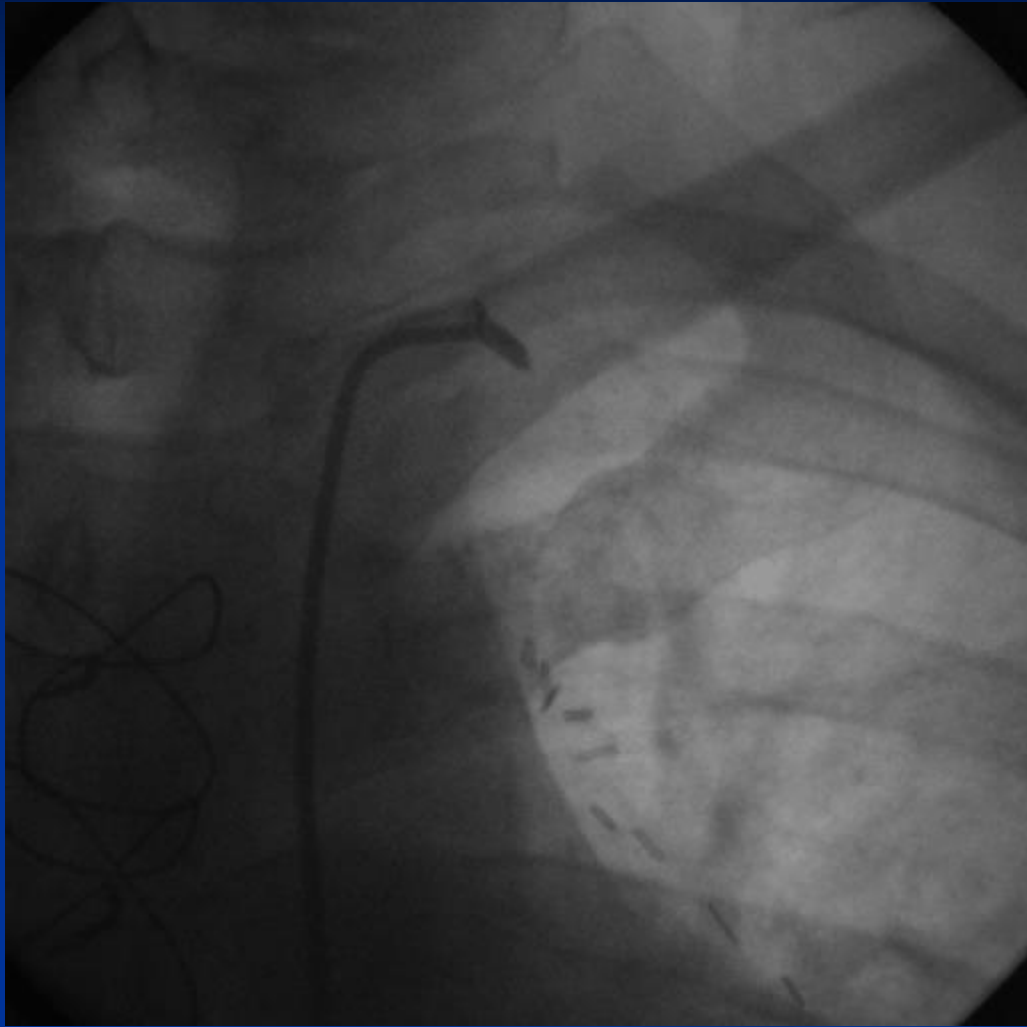
- 04/2013 tarihinde tekrar göğüs ağrısı ile başvuran hastaya yapılan anjiyoda Ao-RCA greft distalindeki stentte %90 darlık gözlemlendi. Hastada proksimalinden total oklude olan nativ RCA lezyonunun greftten retrograd olarak açılması planlandı.

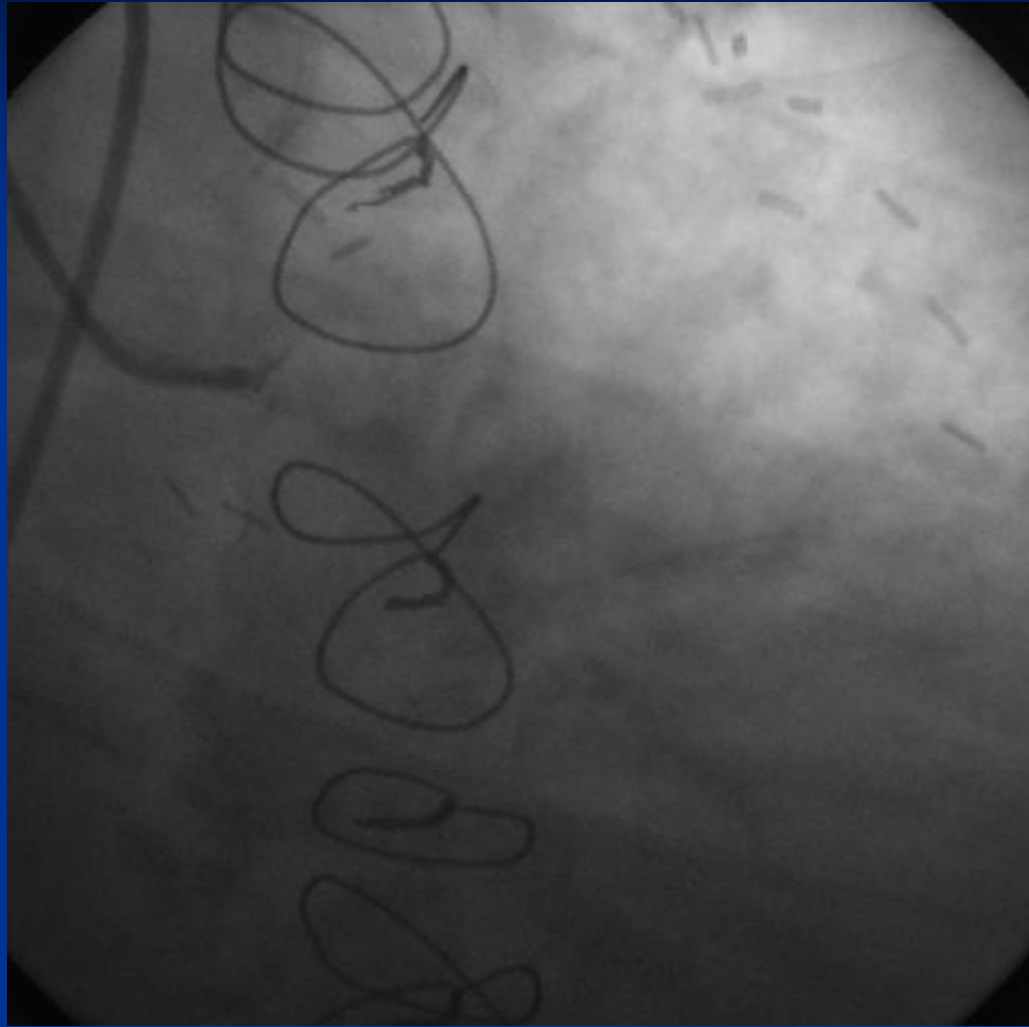




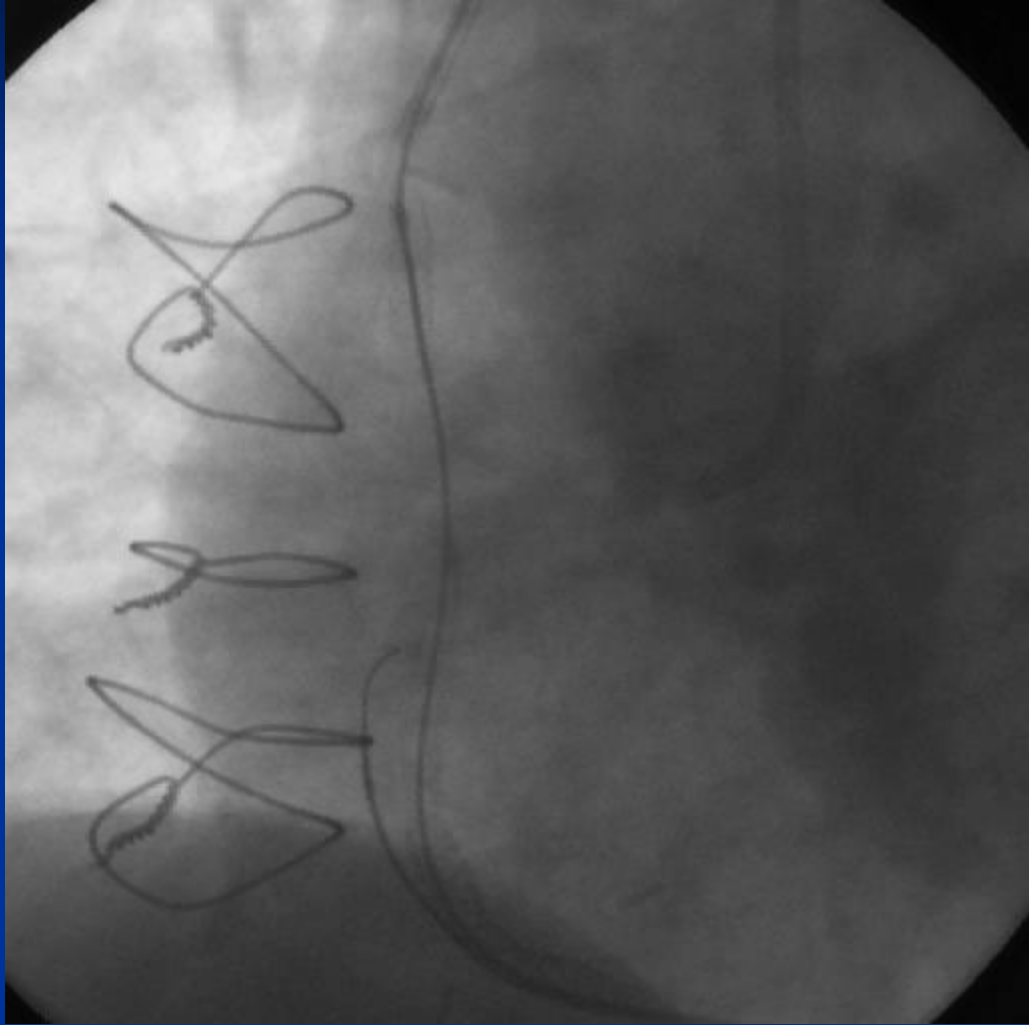


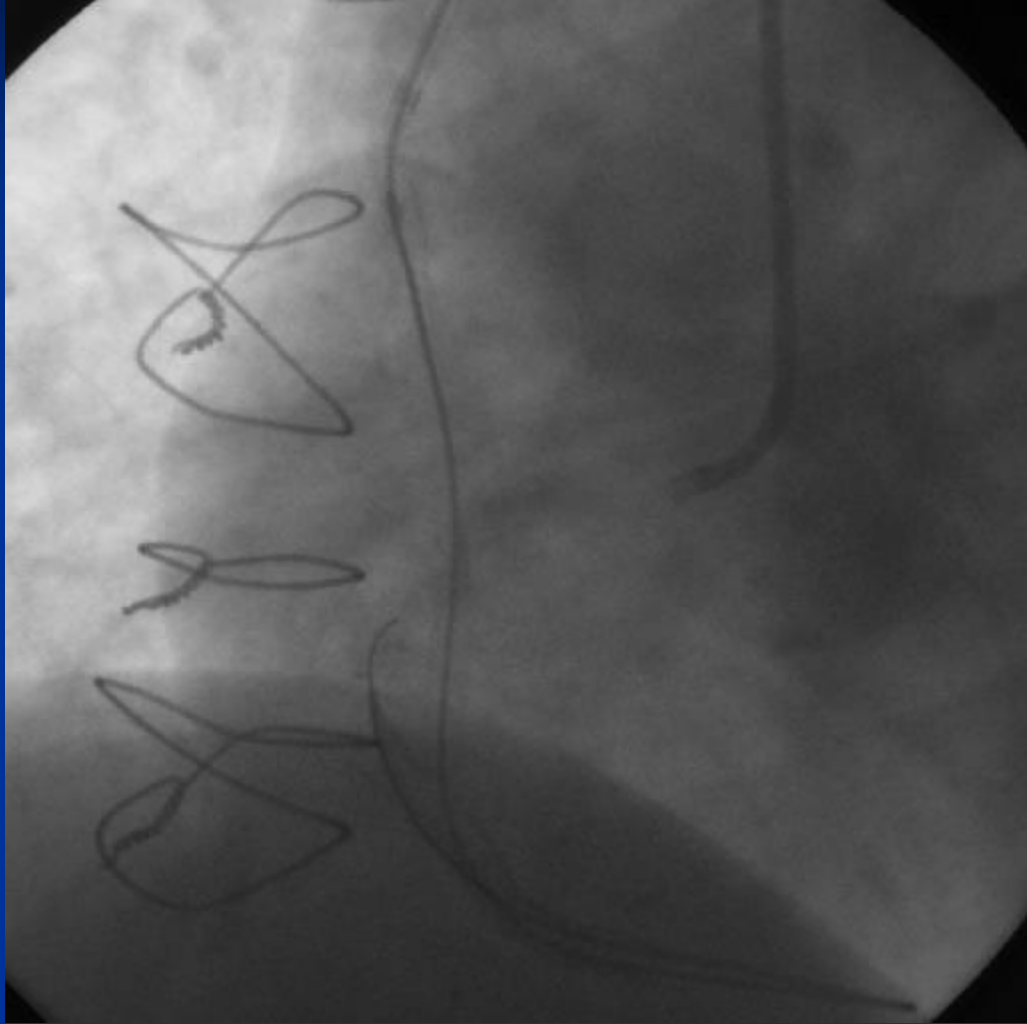


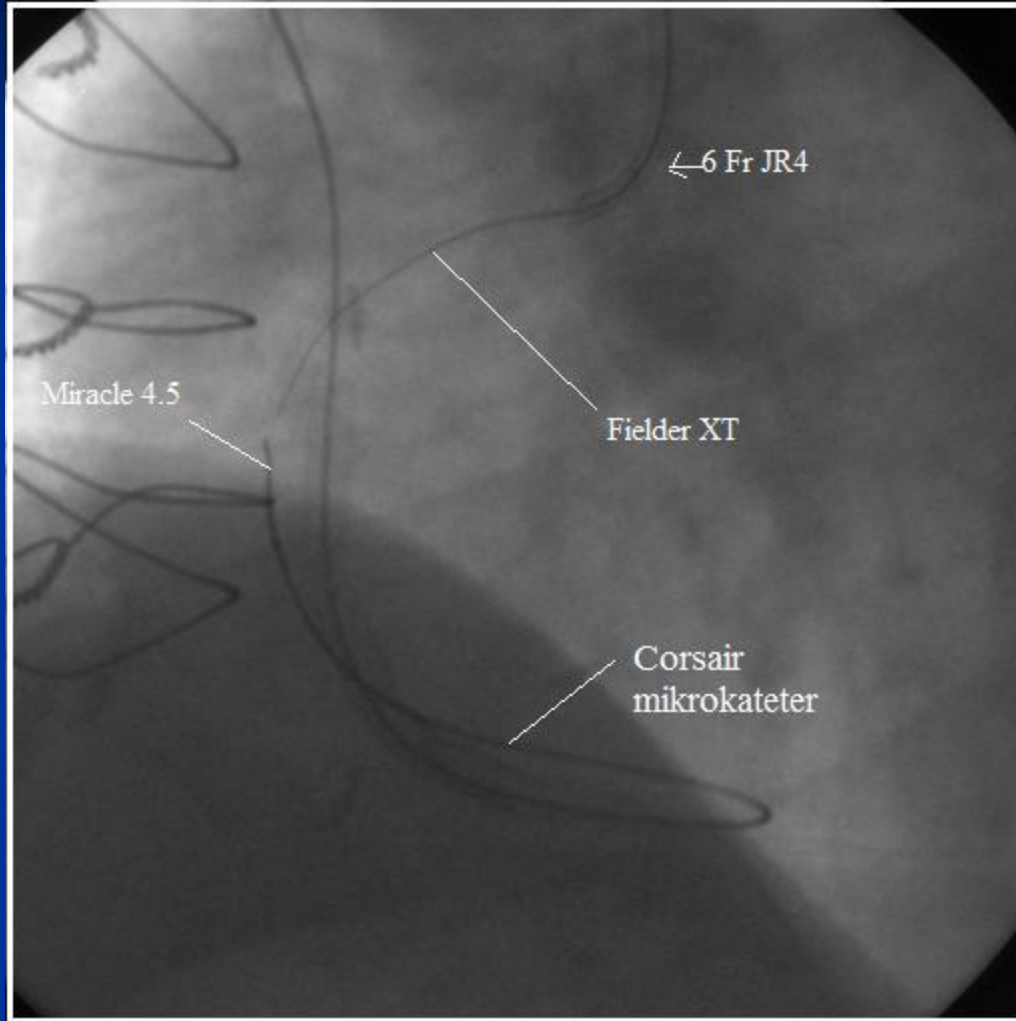


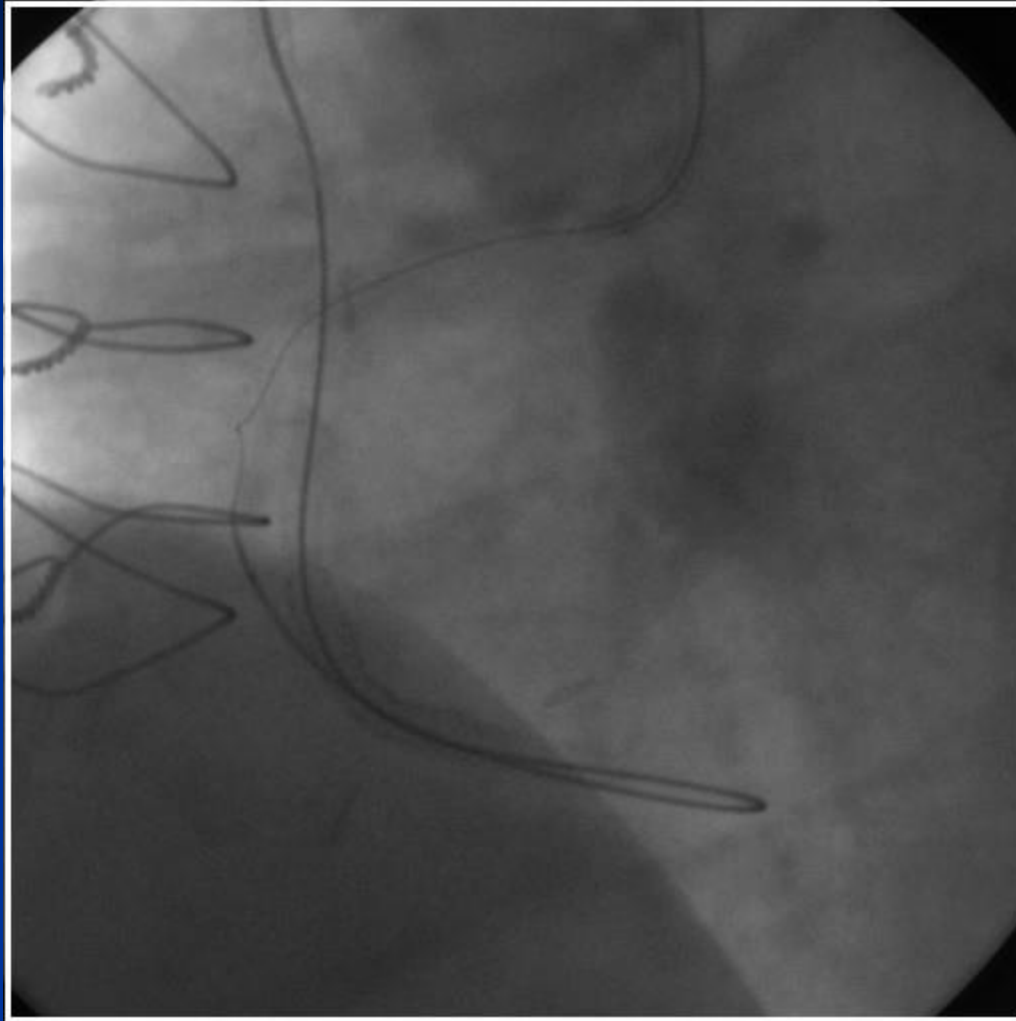


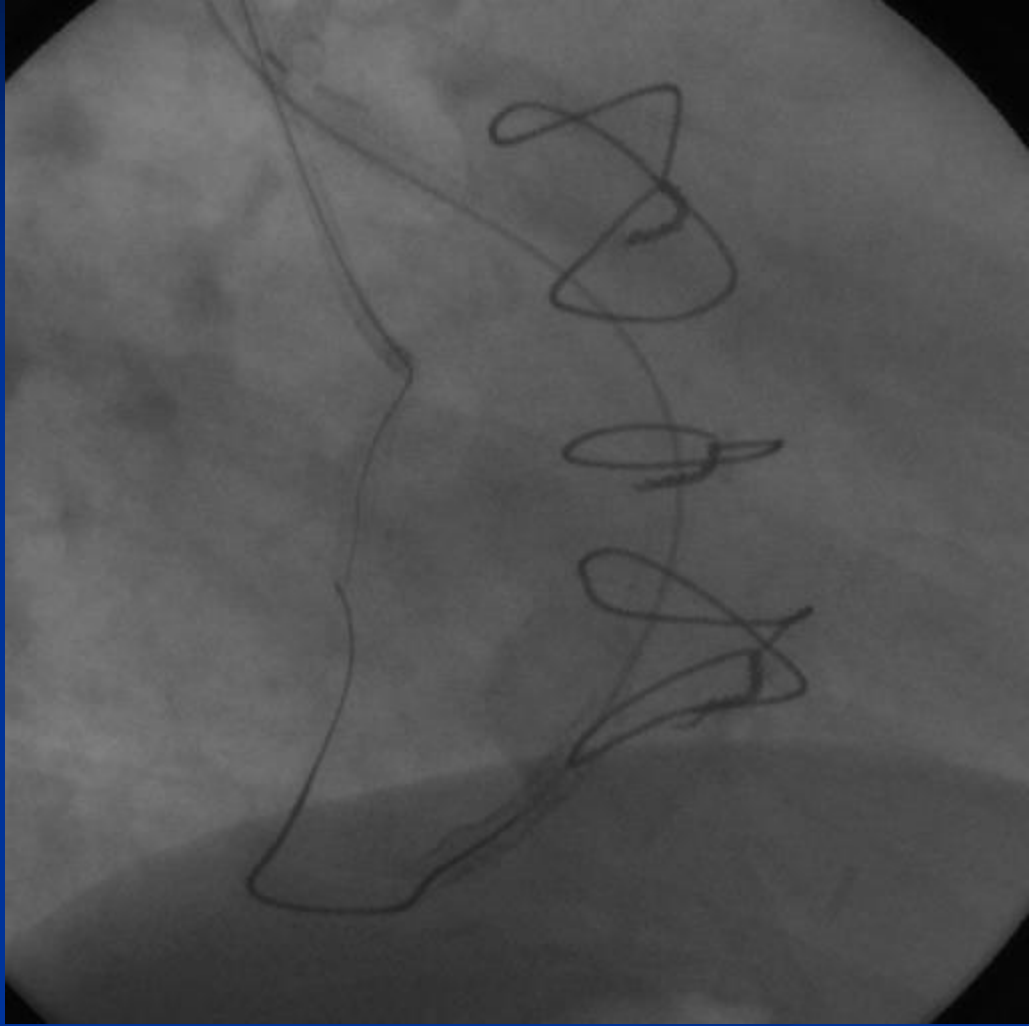- Corsair mikrokater ile Ao-RCA greftinden nativ RCA distaline ulaşıldı.
- Fielder XT, Miracle ,4.5,6 gr guidewire ile lezyon geçilemedi

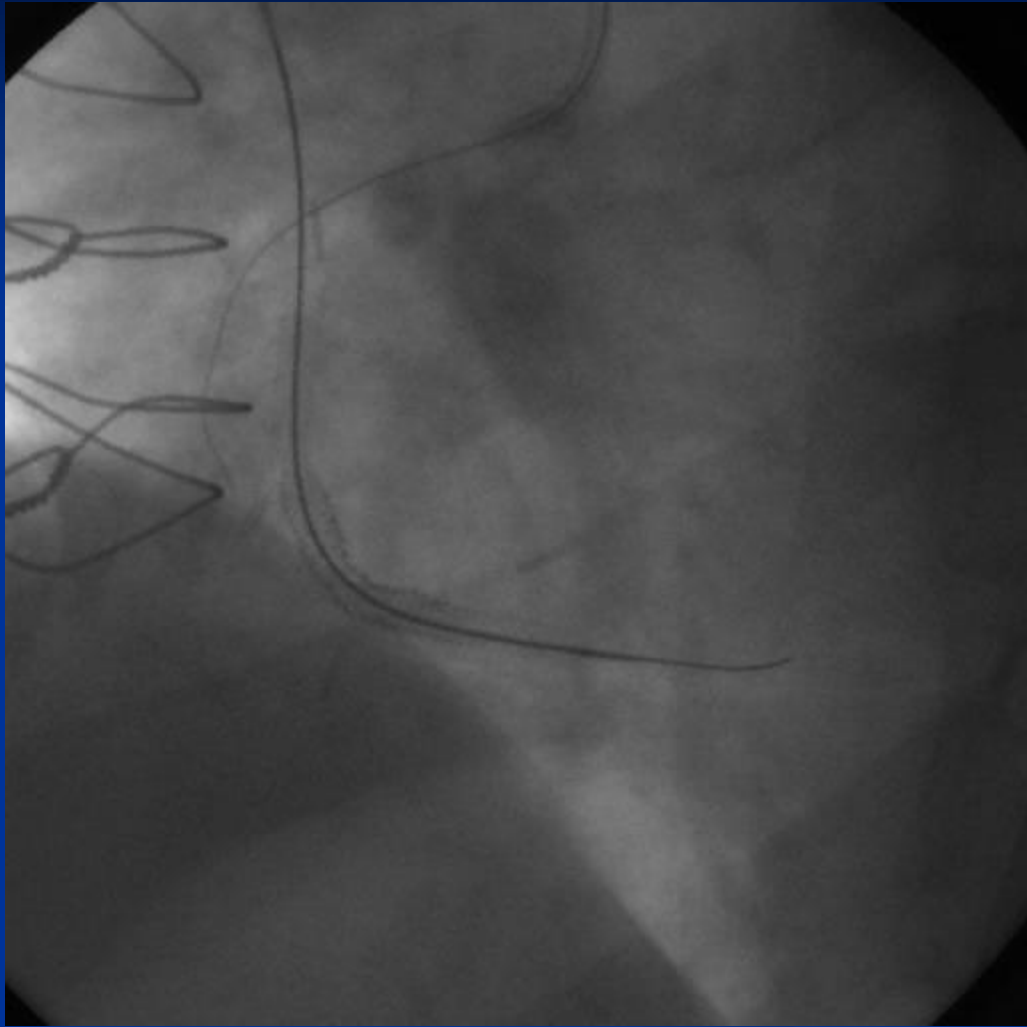




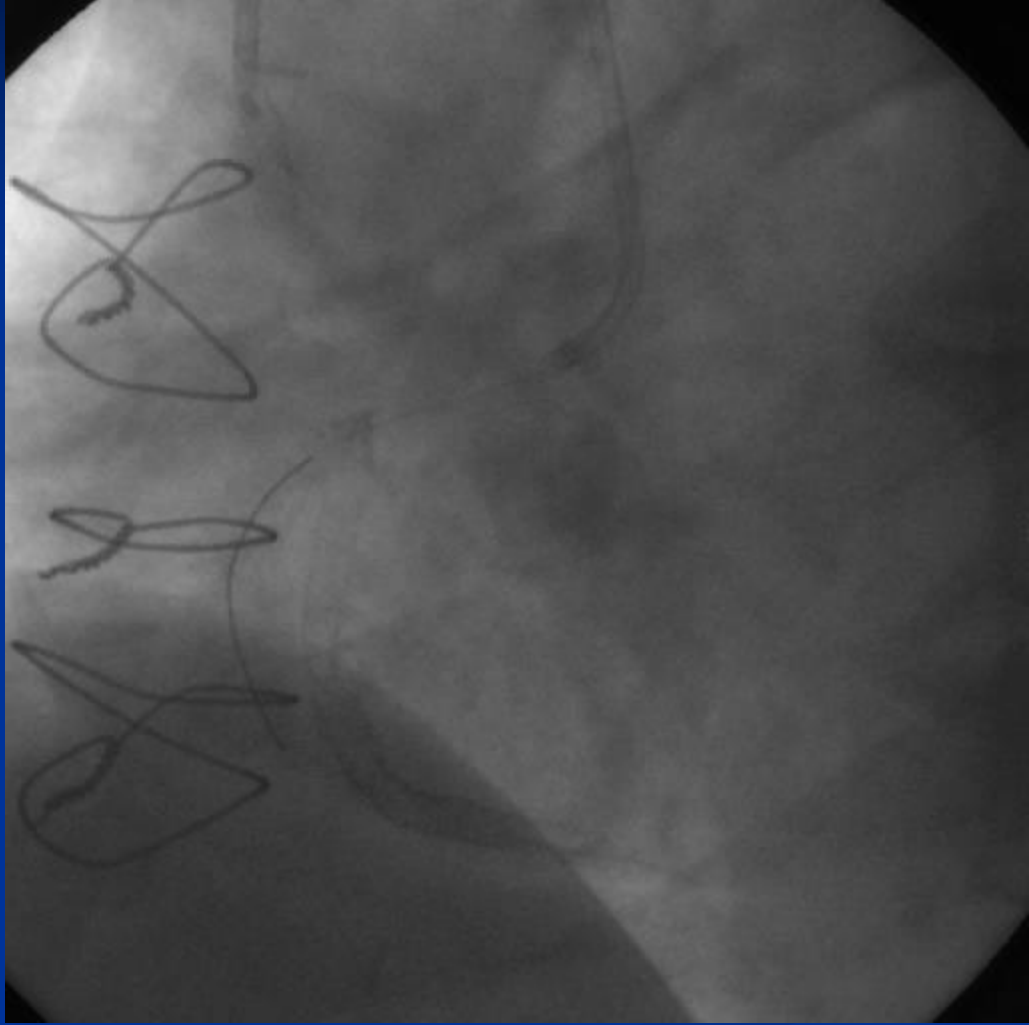


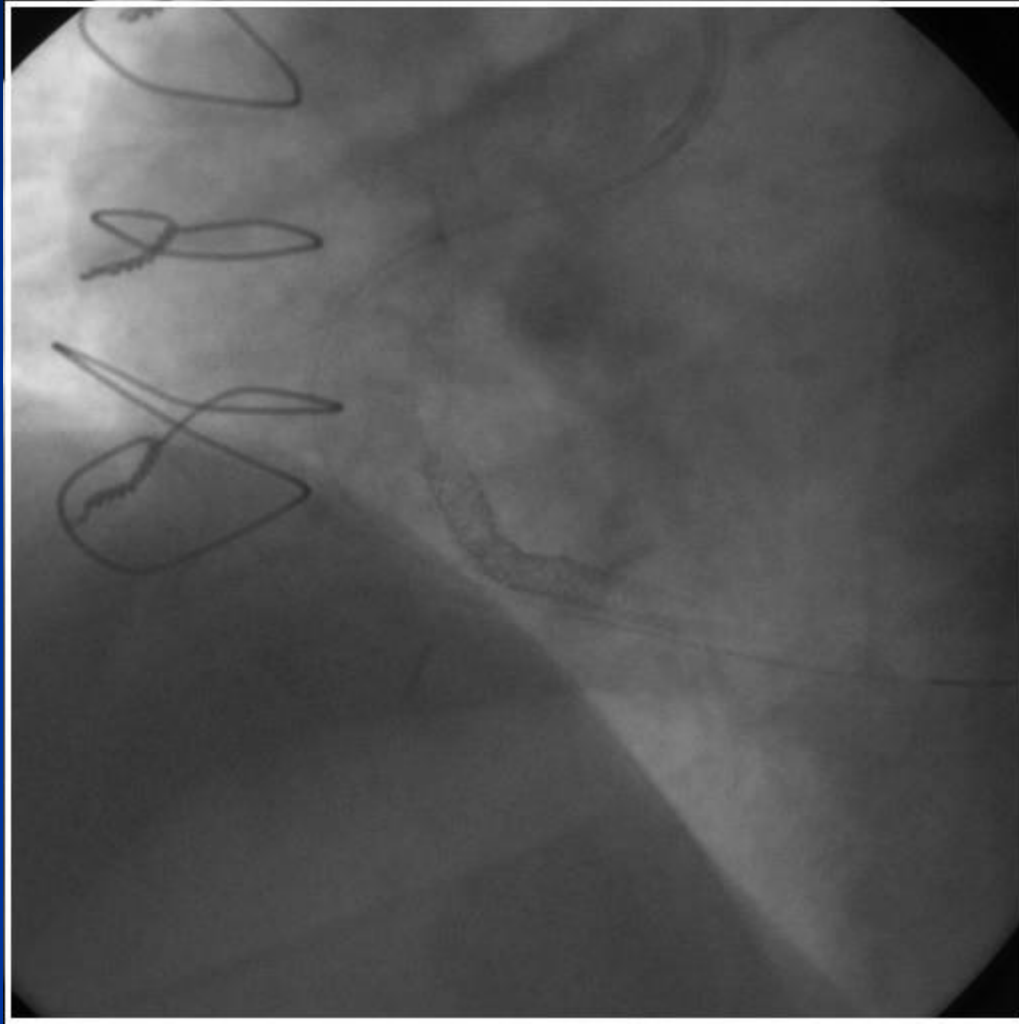


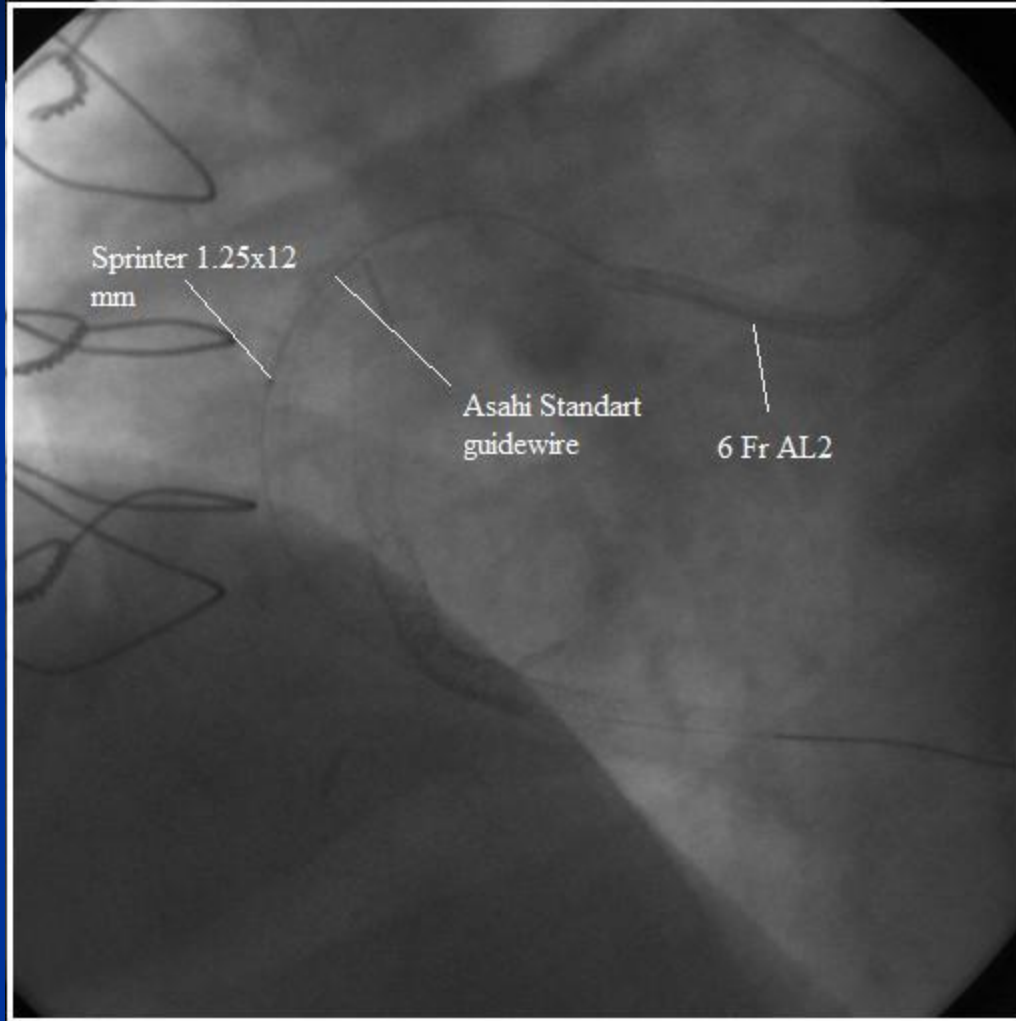


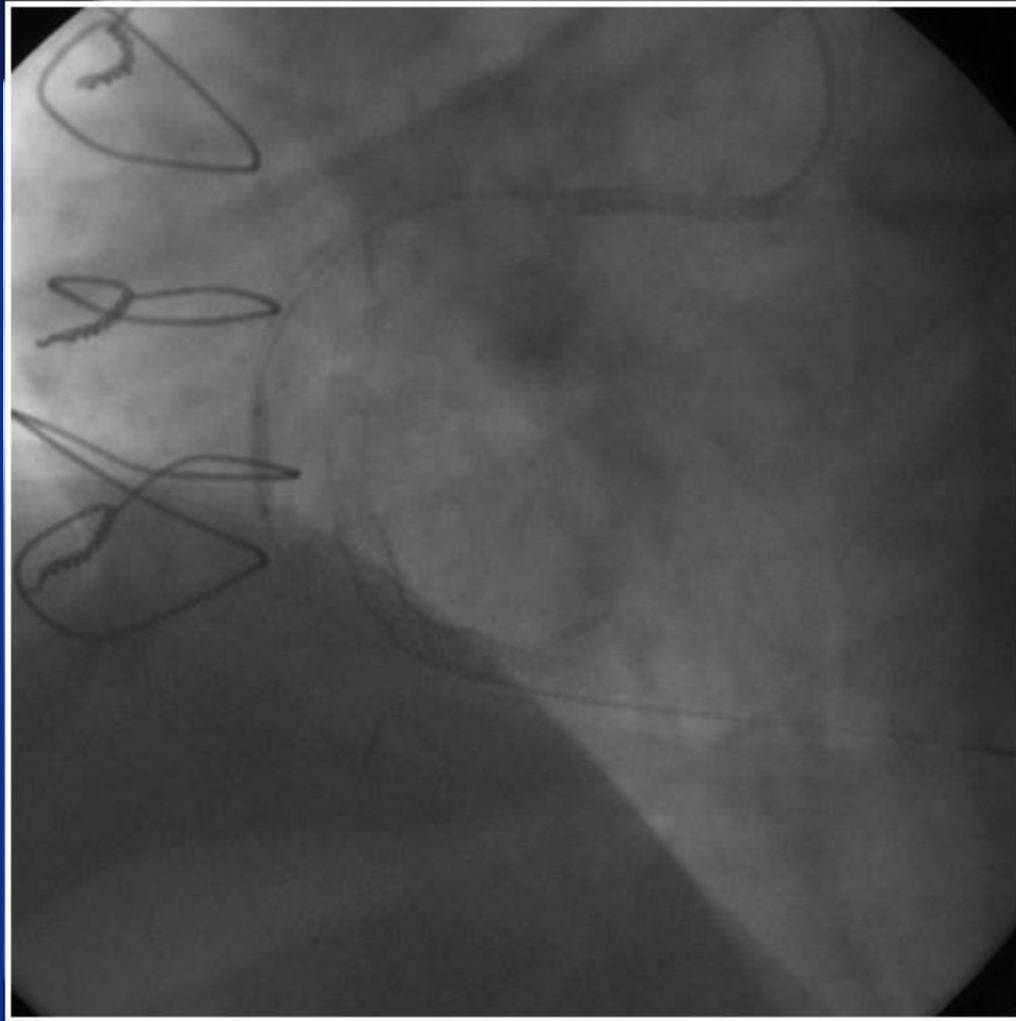


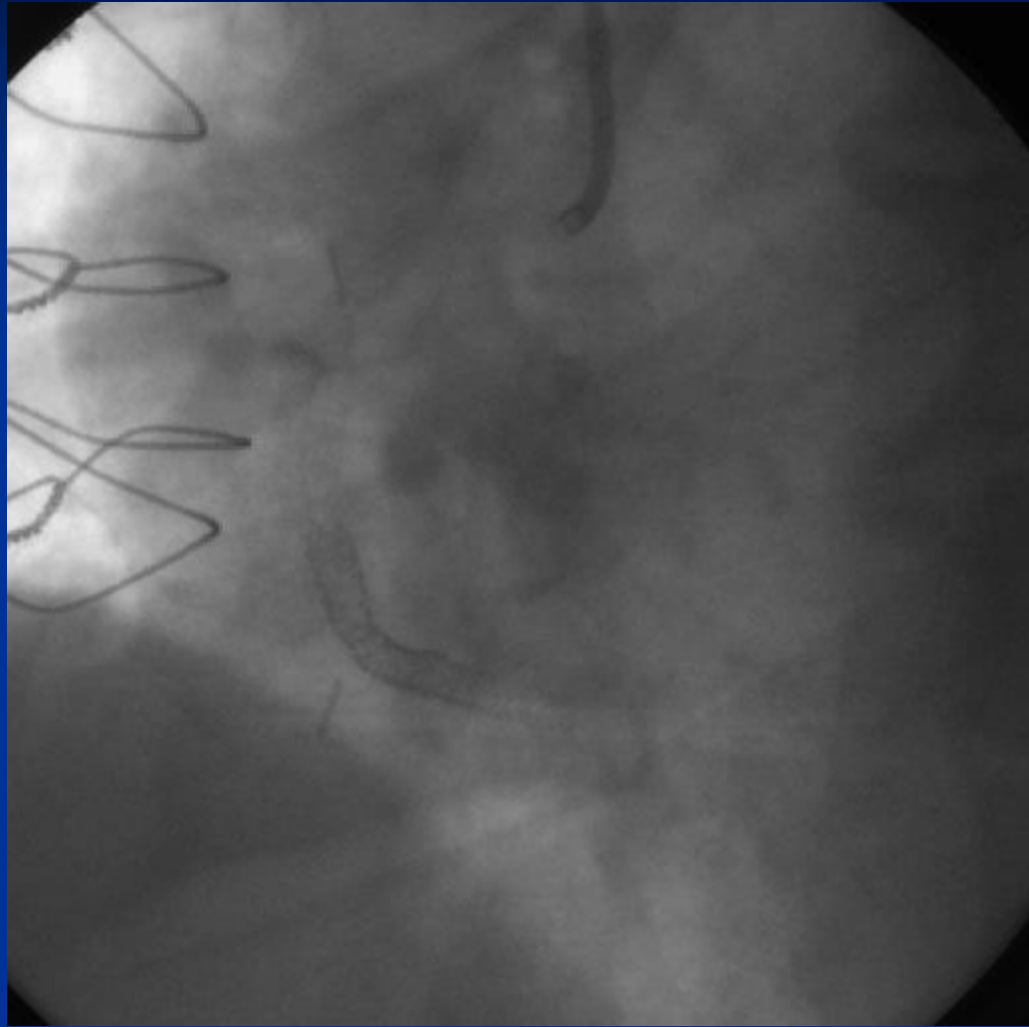
- Hastanın göğüs ağrısı ve sıkıntı hissi olması üzerine akımı sağlamak için Corsair kateter geri çekildi ve Asahi Standart guidewire yerleştirildi



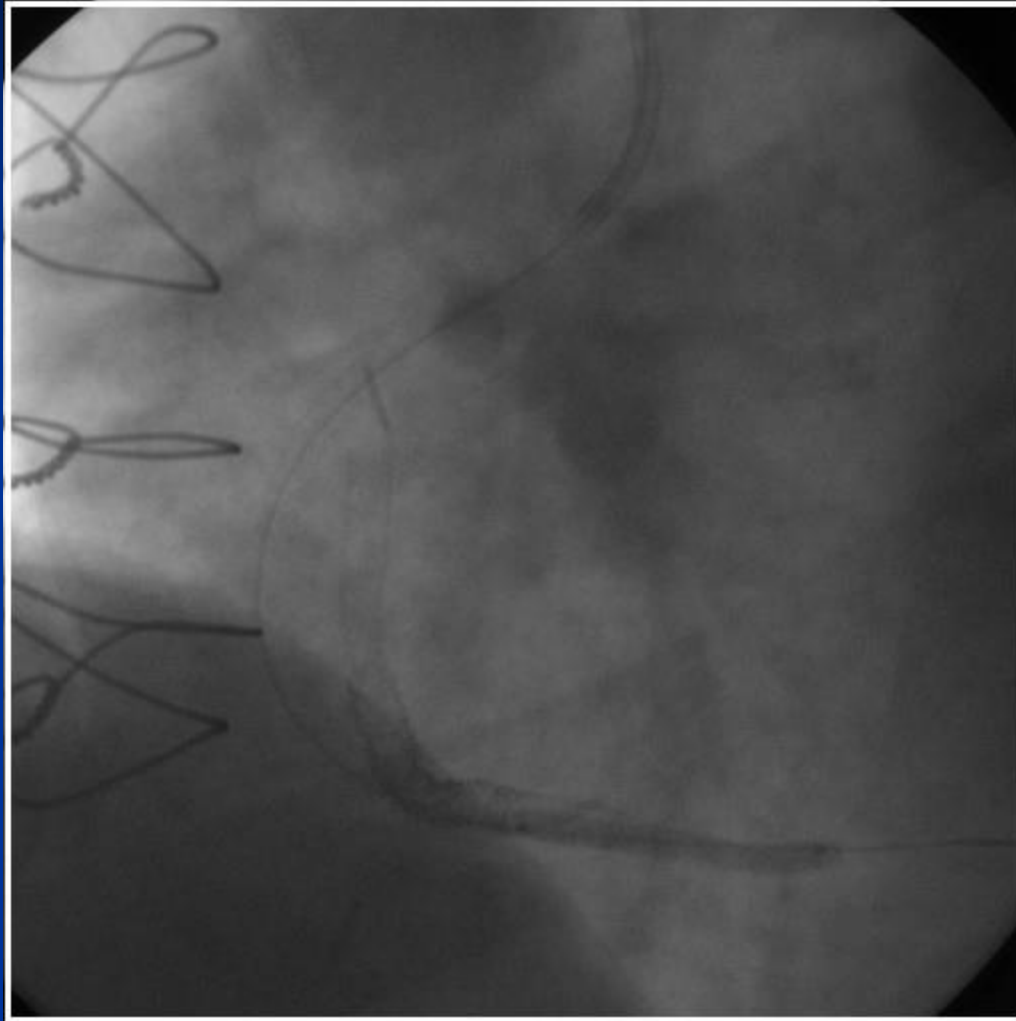


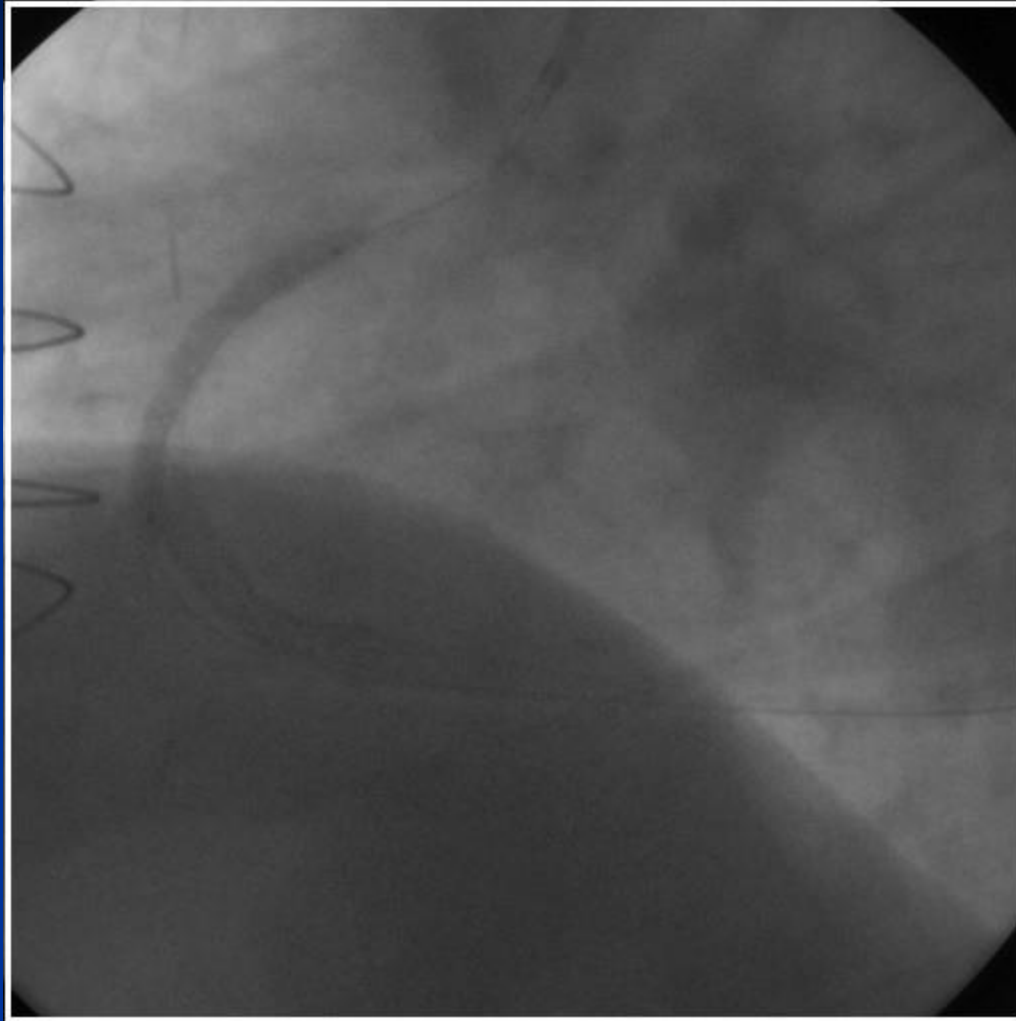


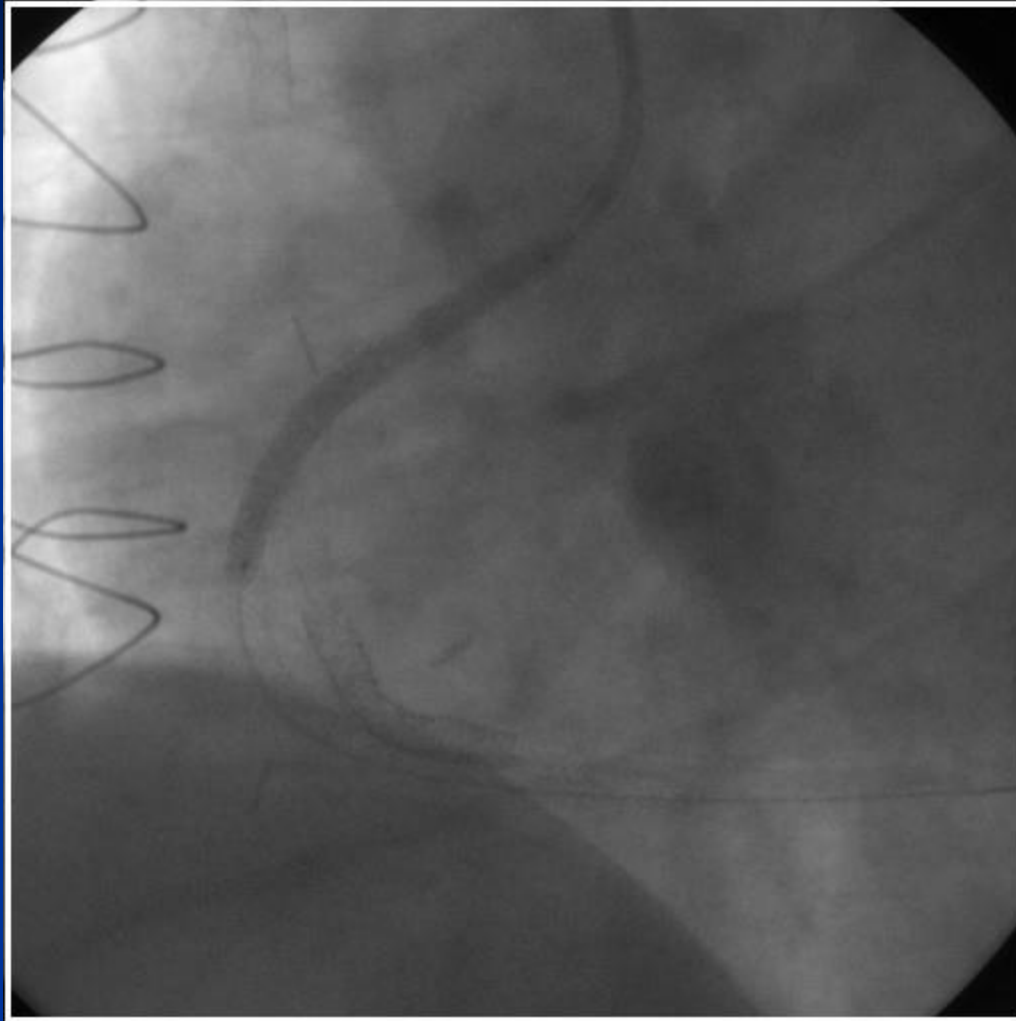


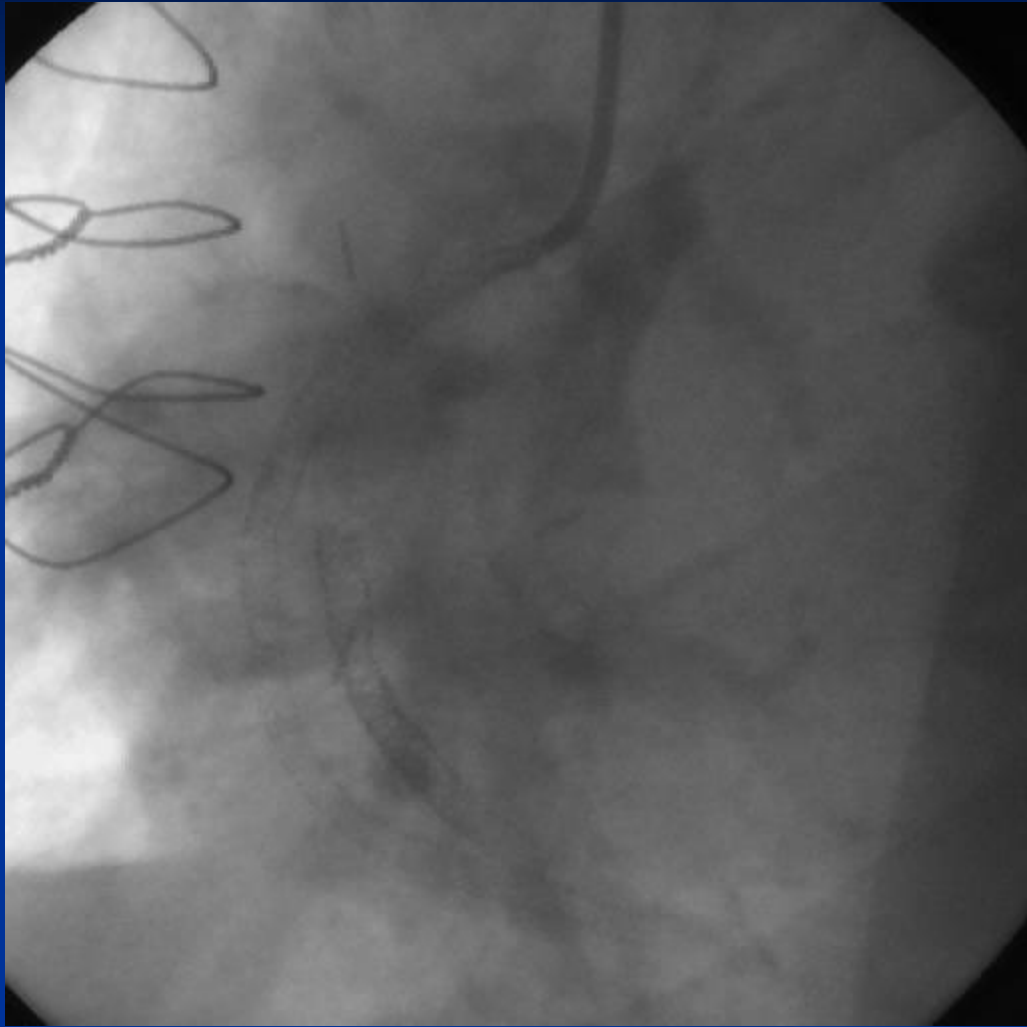


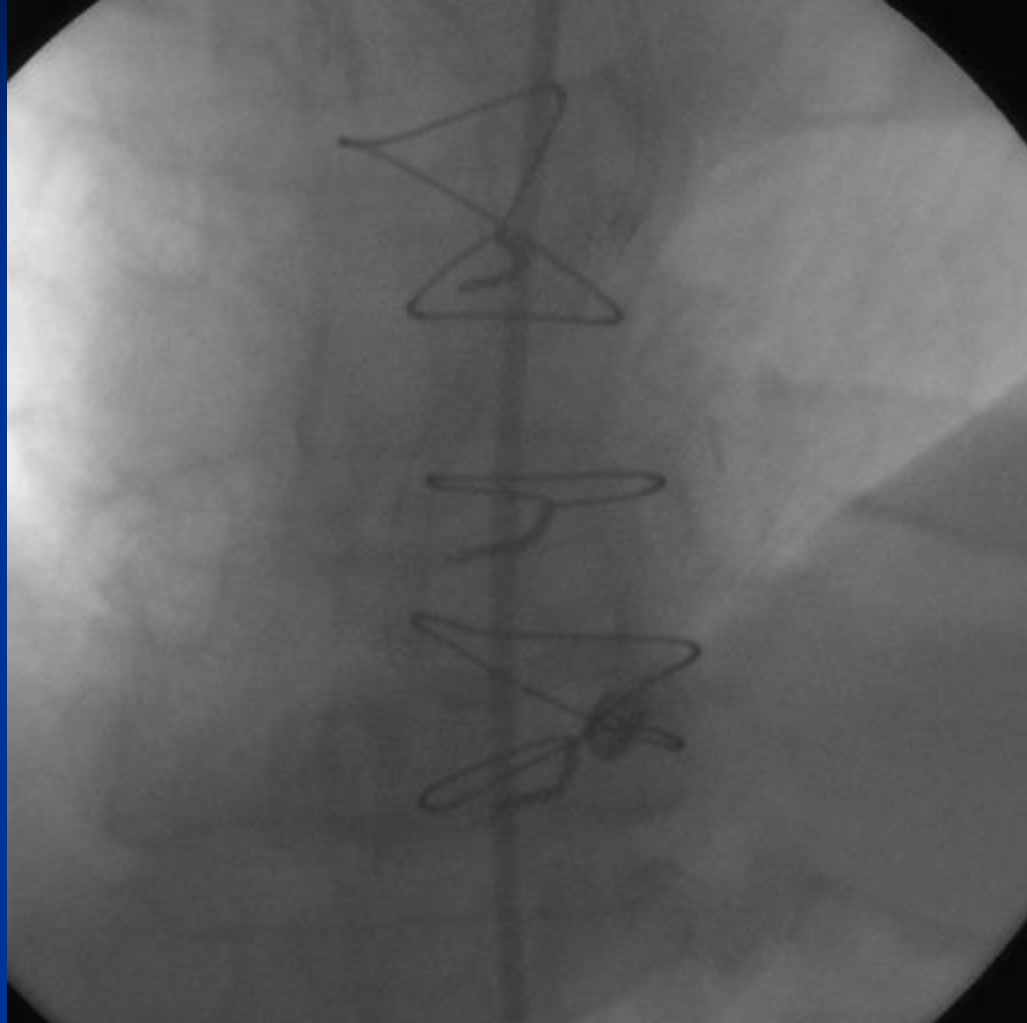
- Lezyon 2.0 ve 2.5 mm balon ile dilate edildikten sonra distalden başlanarak 3.0x38 mm, 3.0x28 mm ve 3.5x38 mm Everolimus salınımlı stent implante edildi



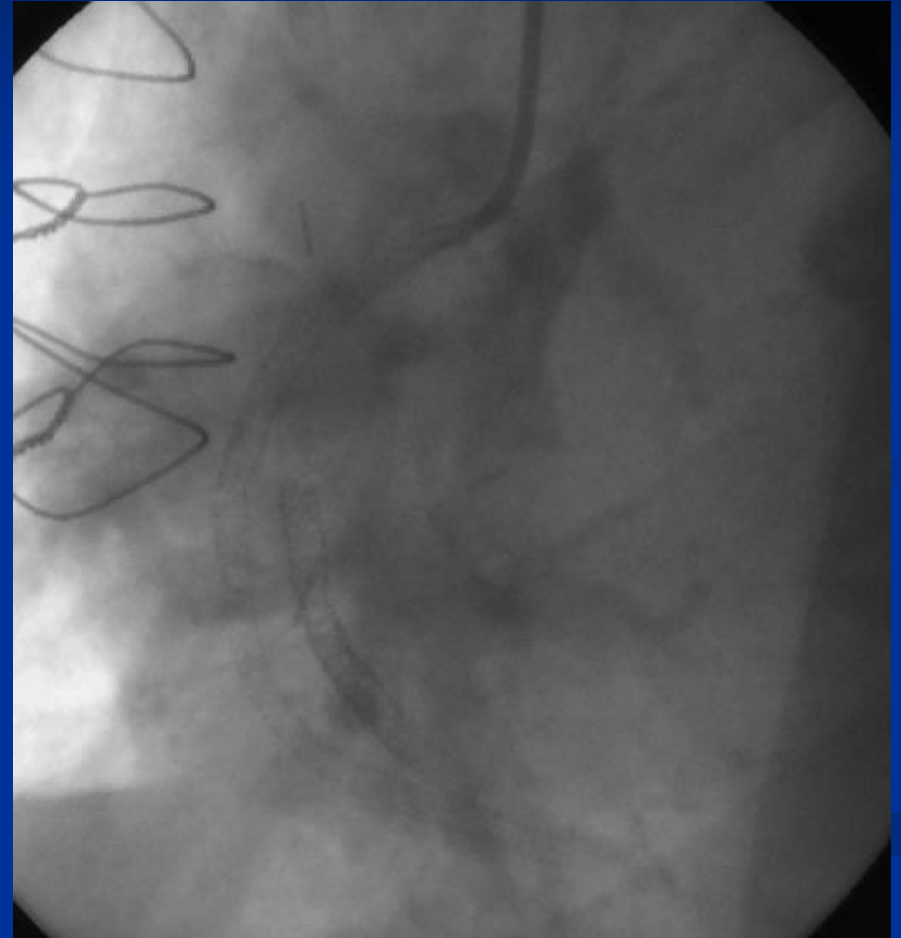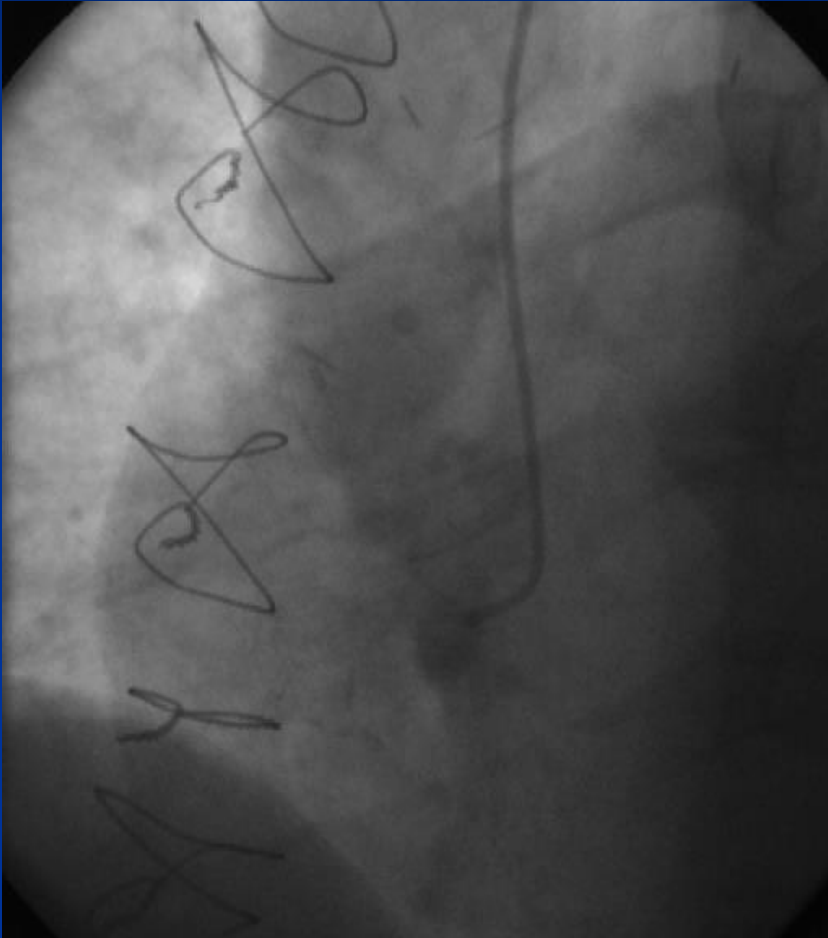








250 cc Kontrast+55 dk floro



- 4. ay klinik takipte hasta asemptomatik ve efor testinde iskemi yok.

SABRINIZ İÇİN TEŞEKKÜRLER