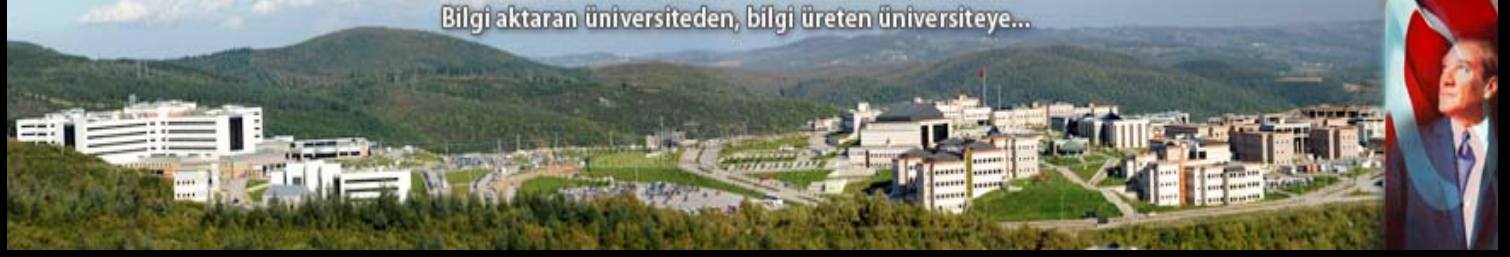



KOCAELİ
ÜNİVERSİTESİ

Bilgi aktaran üniversiteden, bilgi üreten üniversiteye...



SAĞ KORONER ARTERDEKİ KRONİK TOTAL OKLÜZYONA PKG UYGULANAN BİR OLGU

Doçent Dr. Teoman Kılıç
Kocaeli Üniversitesi Tıp Fakültesi
Kardiyoloji Ana Bilim Dalı
İnvazif Kardiyoloji Araştırma ve Uygulama Birimi

-OLGU-

Demografi

- 52 yaş
- Erkek

Özgeçmiş ve Risk Faktörleri

- Diabetes Mellitus, 6 yıl
- Hipertansiyon, 6 yıl
- Hiperlipidemi, 6 yıl
- Sigara, 1.5 paket/gün, 20 yıl

Soygeçmiş

- Baba 50 yaşında ani ölüm

Kullandığı ilaçlar

- ASA 100 mg
- Amlodipin 10 mg
- Metformin 1000 mg
- Gliklazid 80 mg

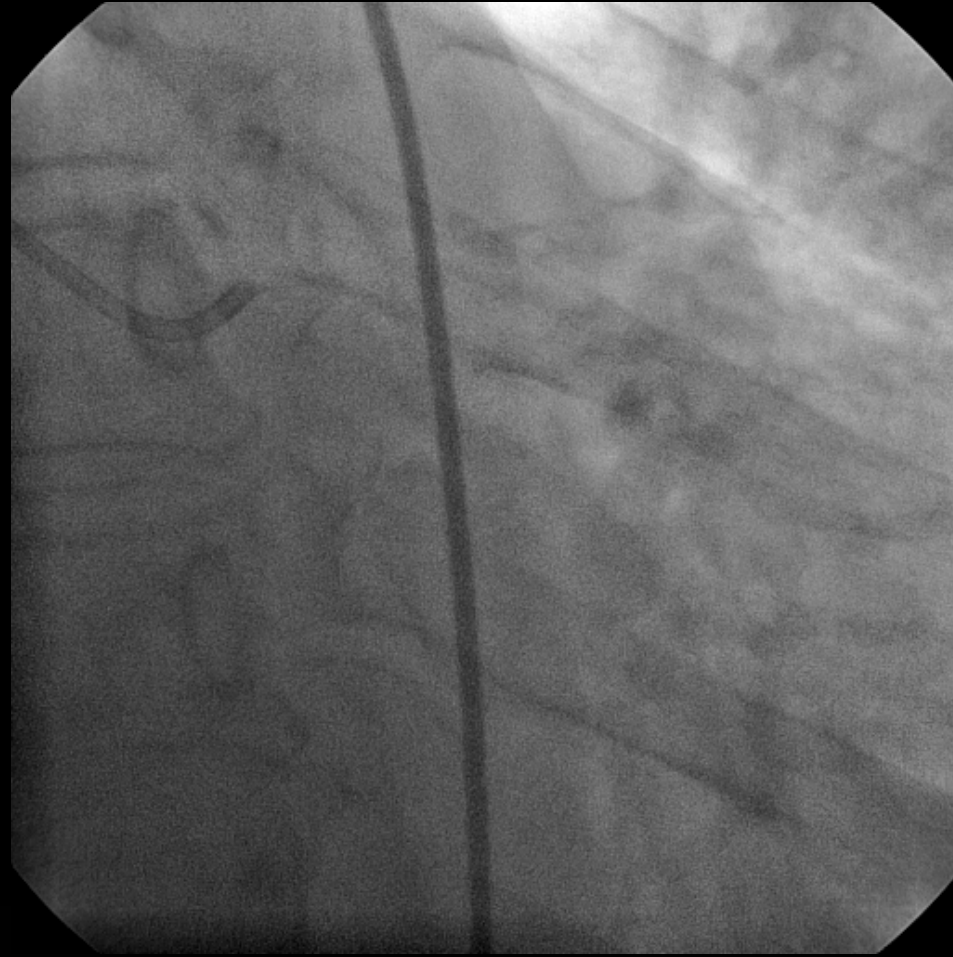-KLİNİK 1-

- 2010 yılından beri sağda daha belirgin olmak üzere her iki el bileğinden başlayan parmaklarda uyuşma ve son 1 yıldır halsizlik yakınmaları oluyormuş.
- Nöroloji kliniğine başvuran ve **Karpal Tünel sendromu** tanısı alan hastaya Ortopedi tarafından operasyon planlanmış.

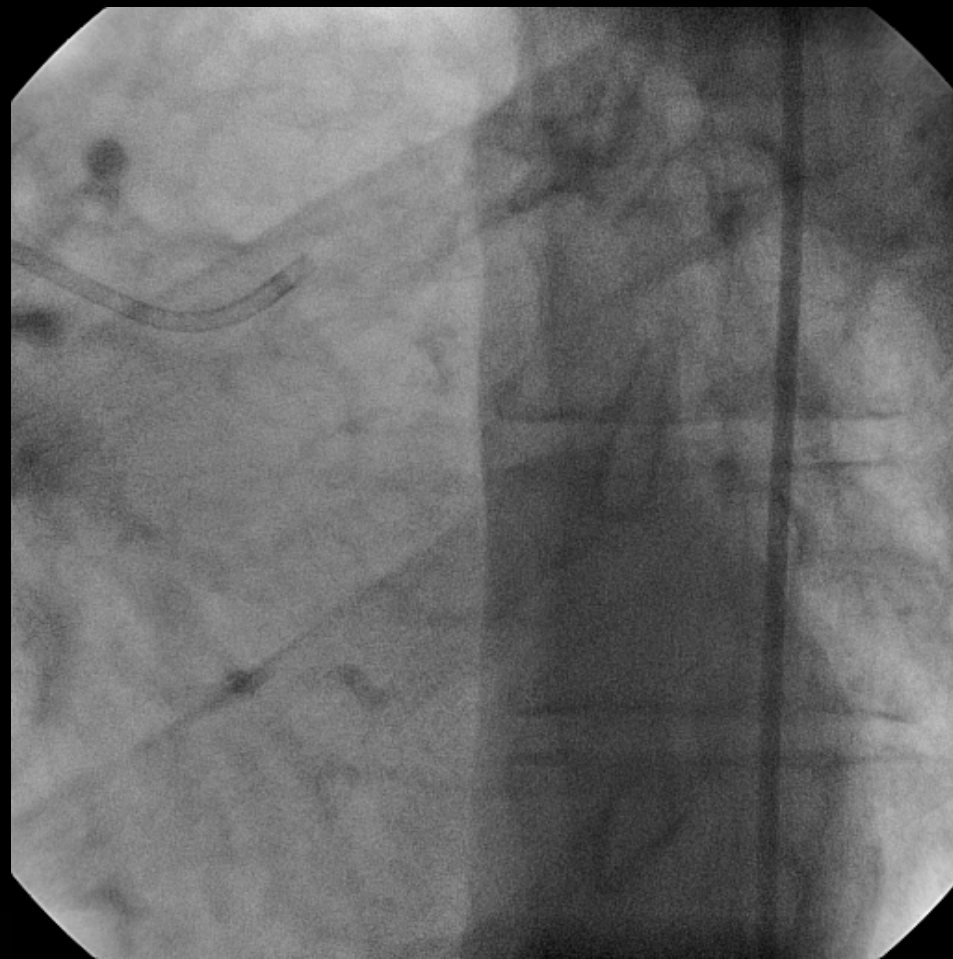
-OLGU-

- Preoperatif tetkiklerinde EKG'de inferiyor derivasyonlarda Q dalgası ve T negatifliđi Ekokardiyografi tetkikinde bölgesel duvar hareket bozukluđu (İnferiyor ağır hipokinezi) saptanan hastadan Miyokard perfüzyon sintigrafisi istendi.
- MPS'de İnferiyor iskemi saptanması üzerine Diabet+sessiz iskemi tanıları ile koroner anjiyografi planlandı.

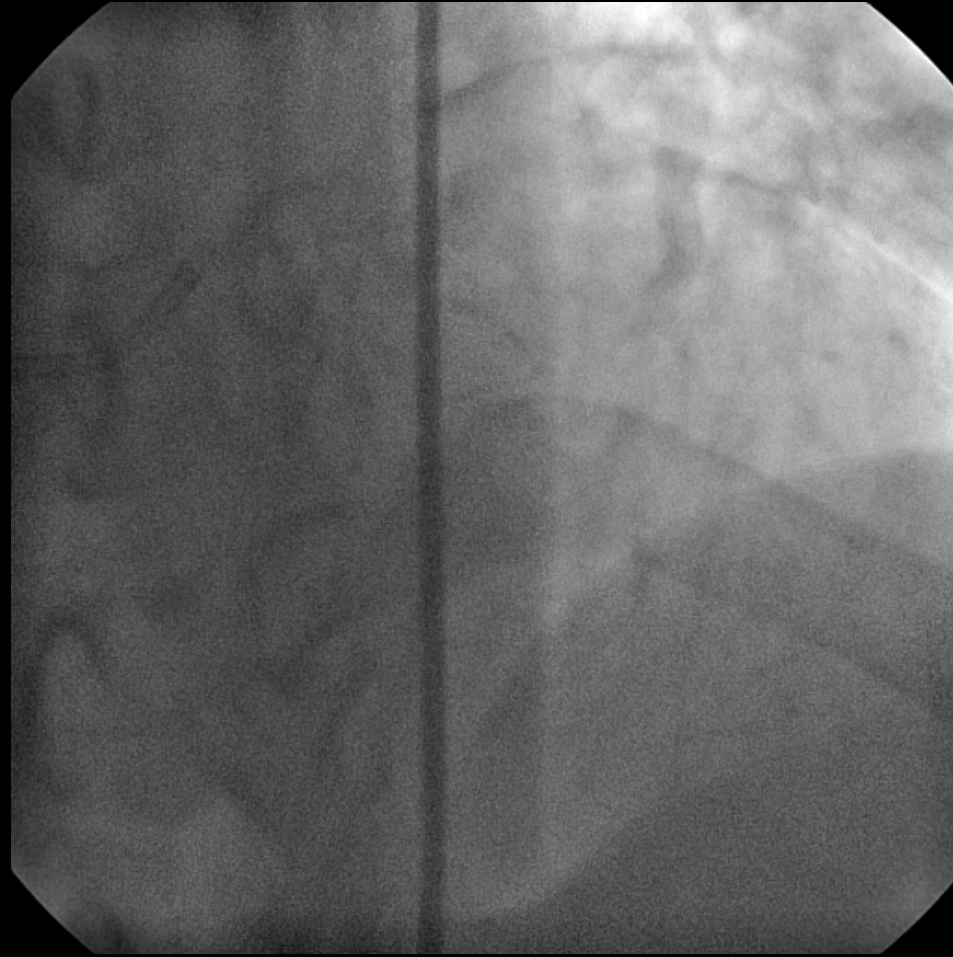-KORONER ANJİYOGRAFI-



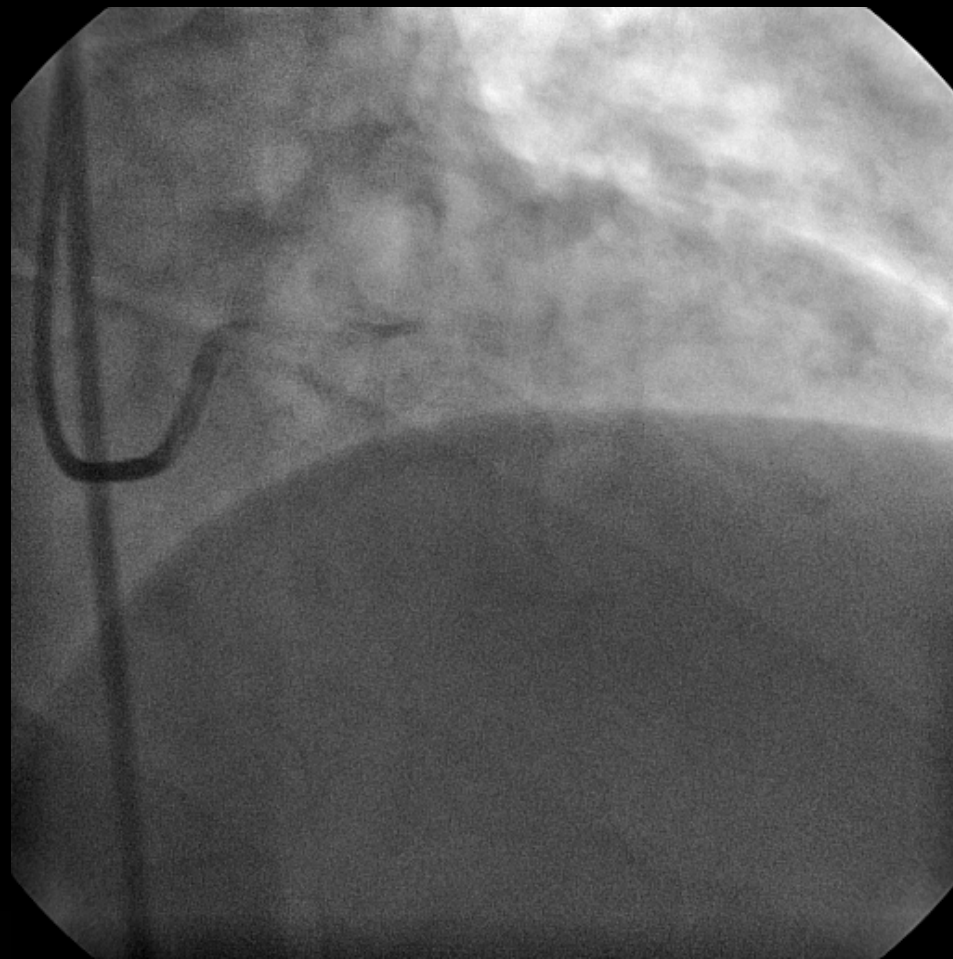-KORONER ANJIYOGRAFI-



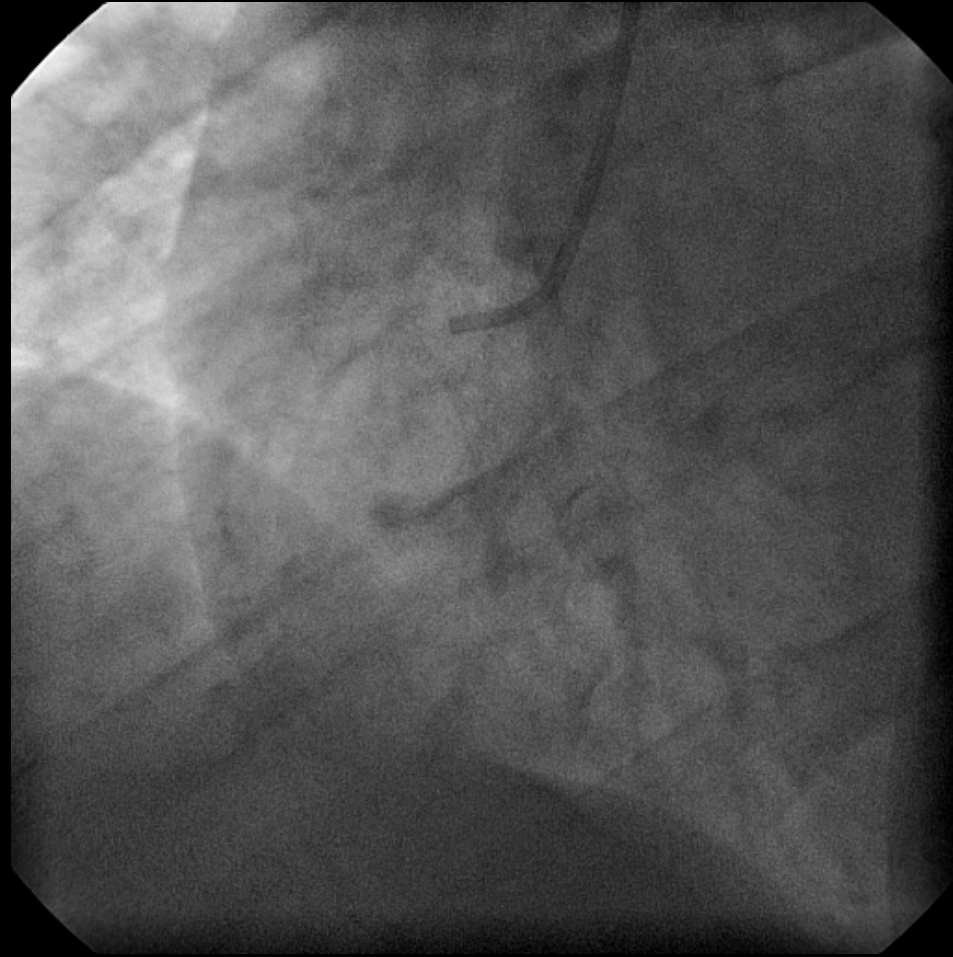
-KORONER ANJIYOGRAFI-



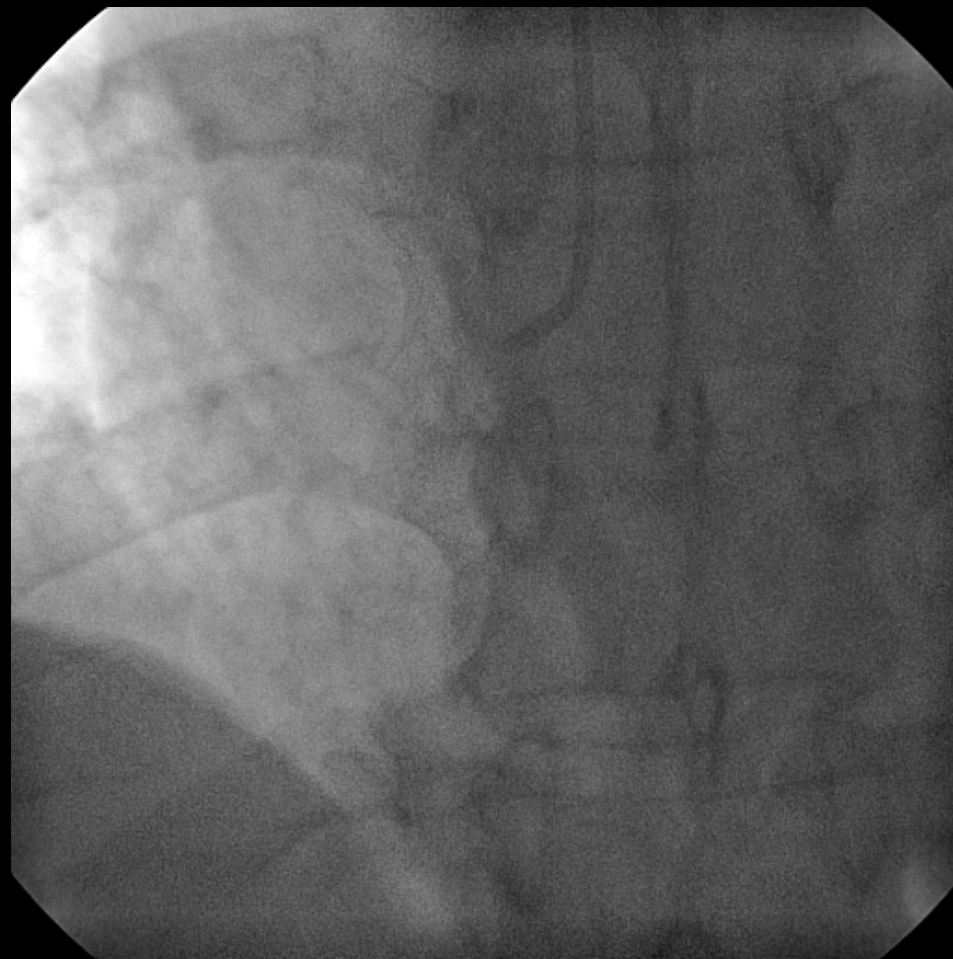
-KORONER ANJIYOGRAFI-



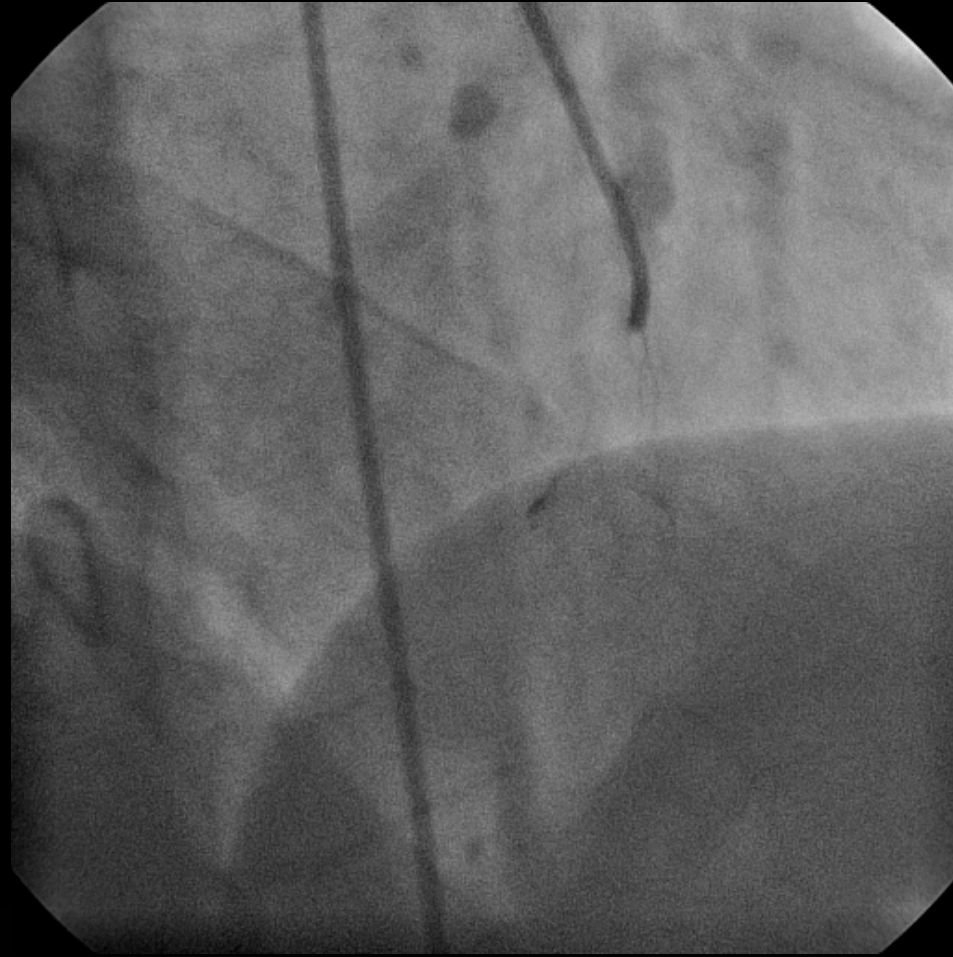
-KORONER ANJIYOGRAFI-



-KORONER ANJIYOGRAFI-



-KORONER ANJİYOGRAFI-



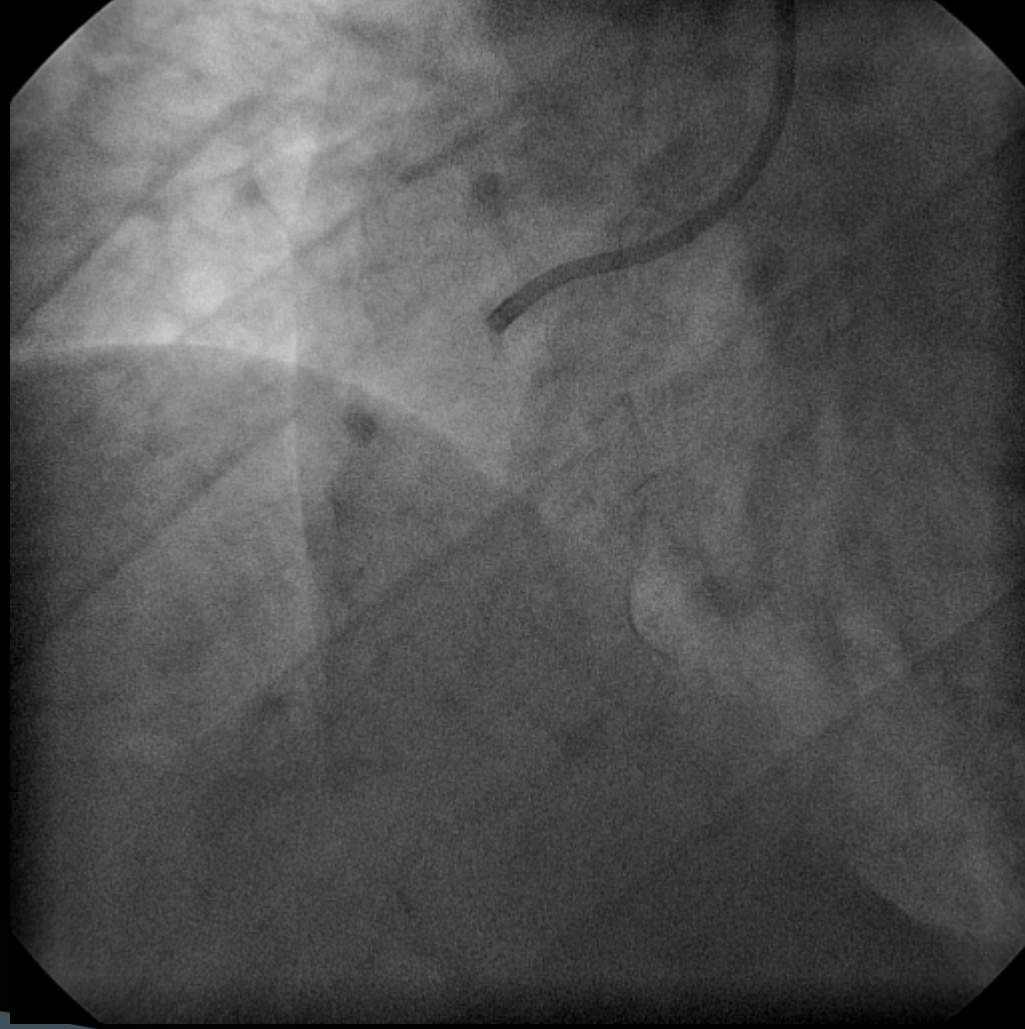
**SAĞ KORONER ARTERDE
KRONİK TOTAL OKLÜZYONA
PERKÜTAN GİRİŞİM**

ANTEGRAD GİRİŞİM

Operatörler: Prof. Dr E Ural, Doç. Dr T Kılıç

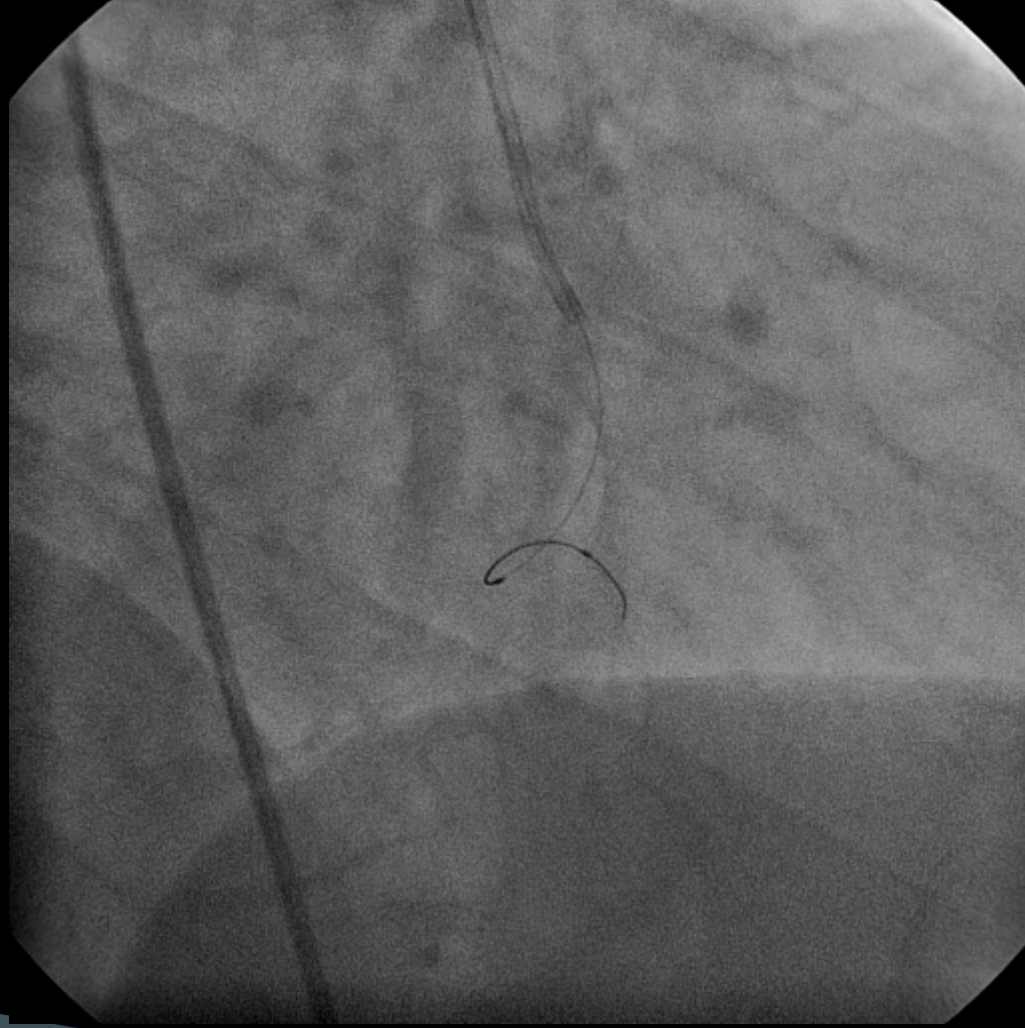
ANTEGRAD GİRİŞİM

Operatörler: Prof. Dr E Ural, Doç. Dr T Kılıç



ANTEGRAD GİRİŞİM

Operatörler: Prof. Dr E Ural, Doç. Dr T Kılıç

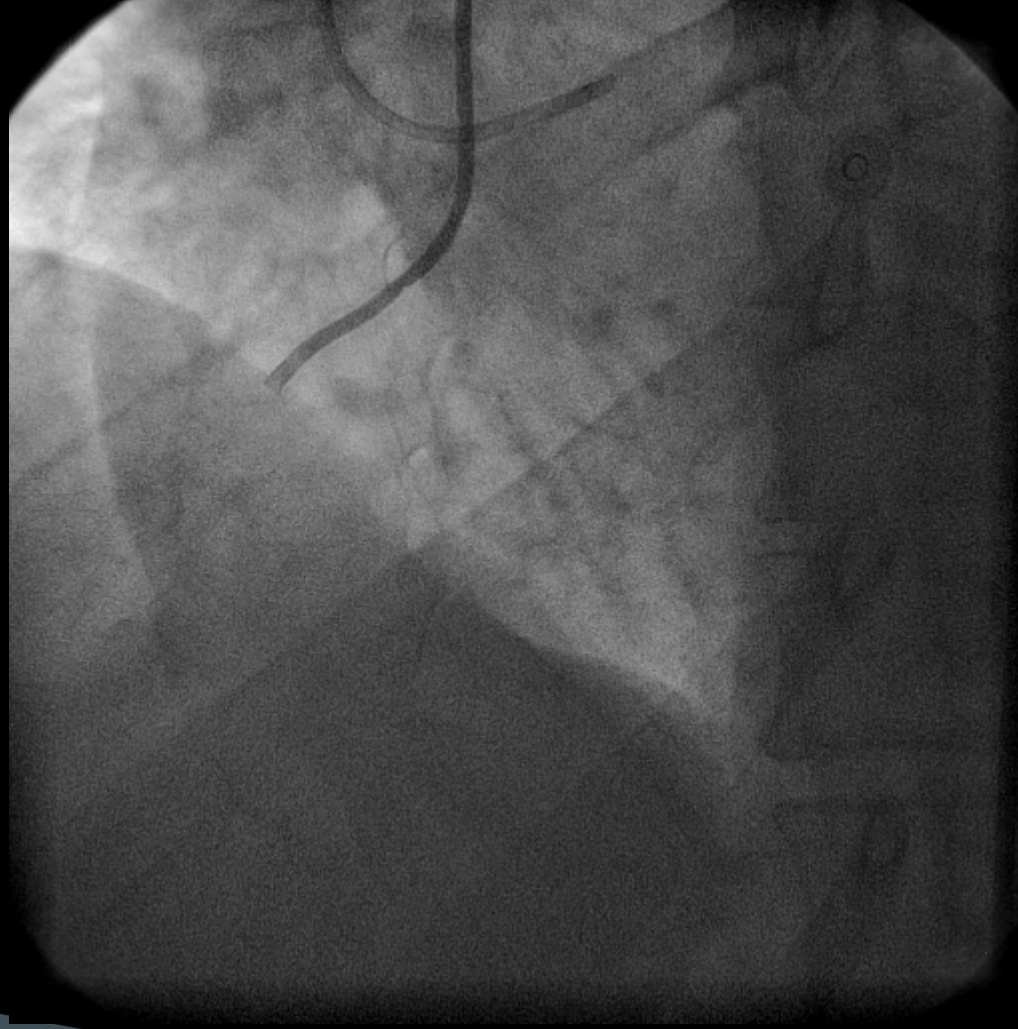


RETROGRAD GİRİŞİM

Operatörler: Prof. Dr E Ural, Doç. Dr T Kılıç

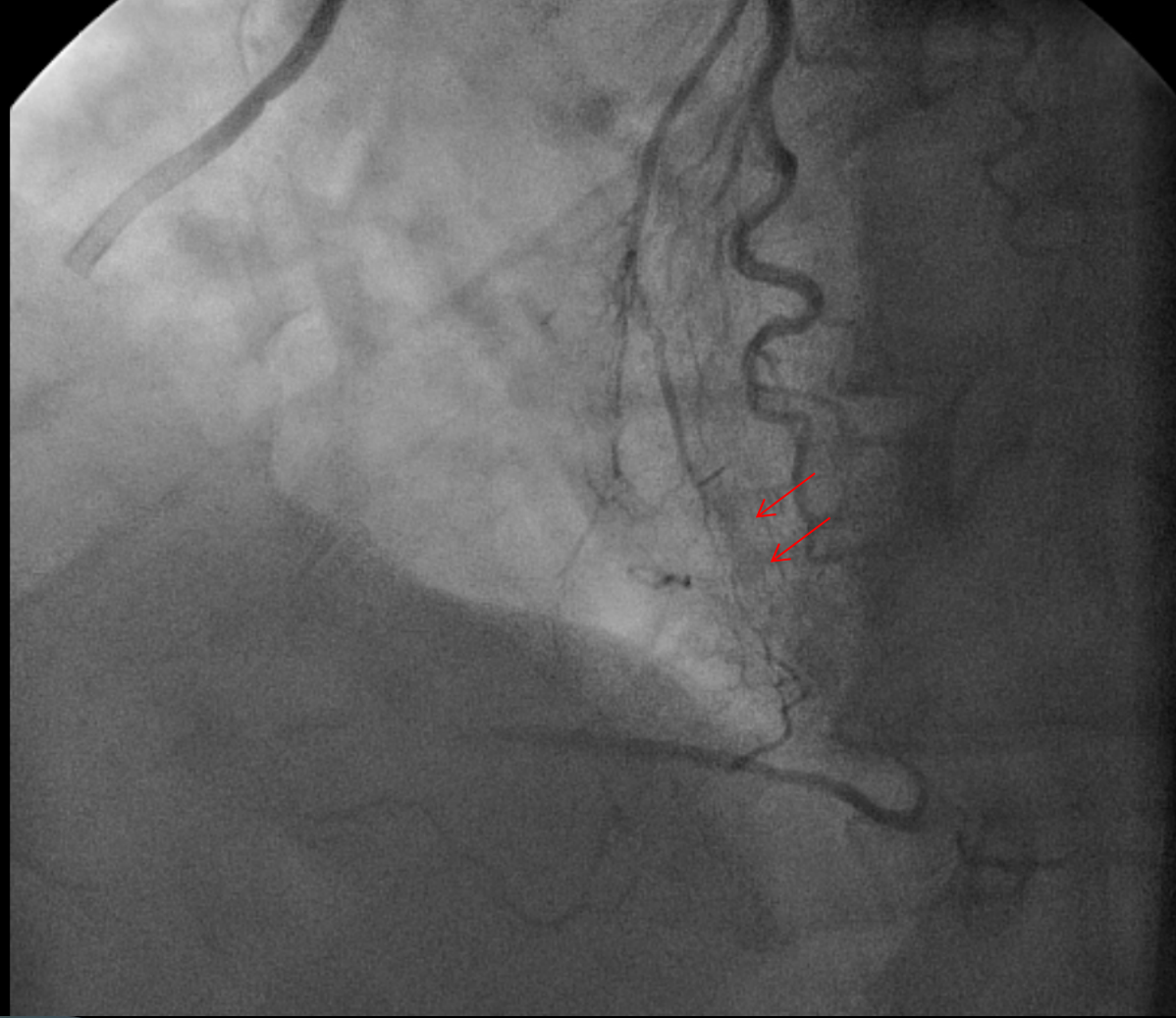
RETROGRAD GİRİŞİM

Operatörler: Prof. Dr E Ural, Doç. Dr T Kılıç

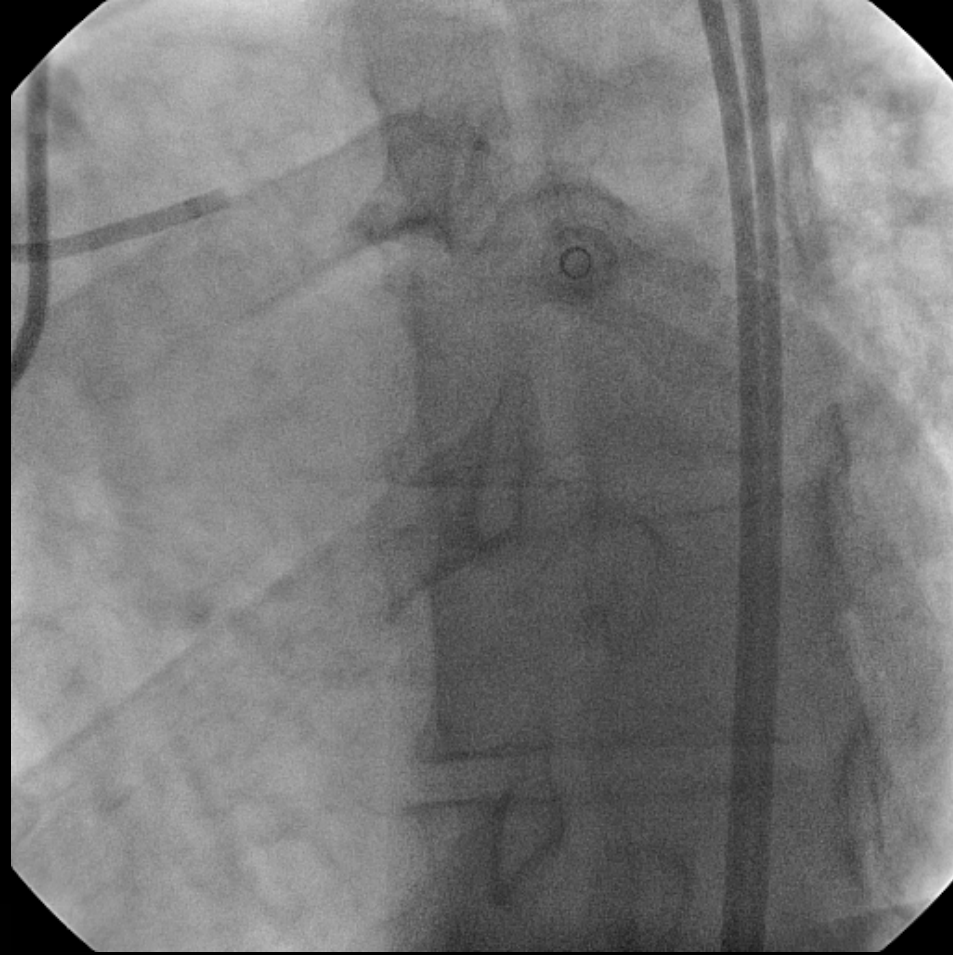


RETROGRAD GİRİŞİM

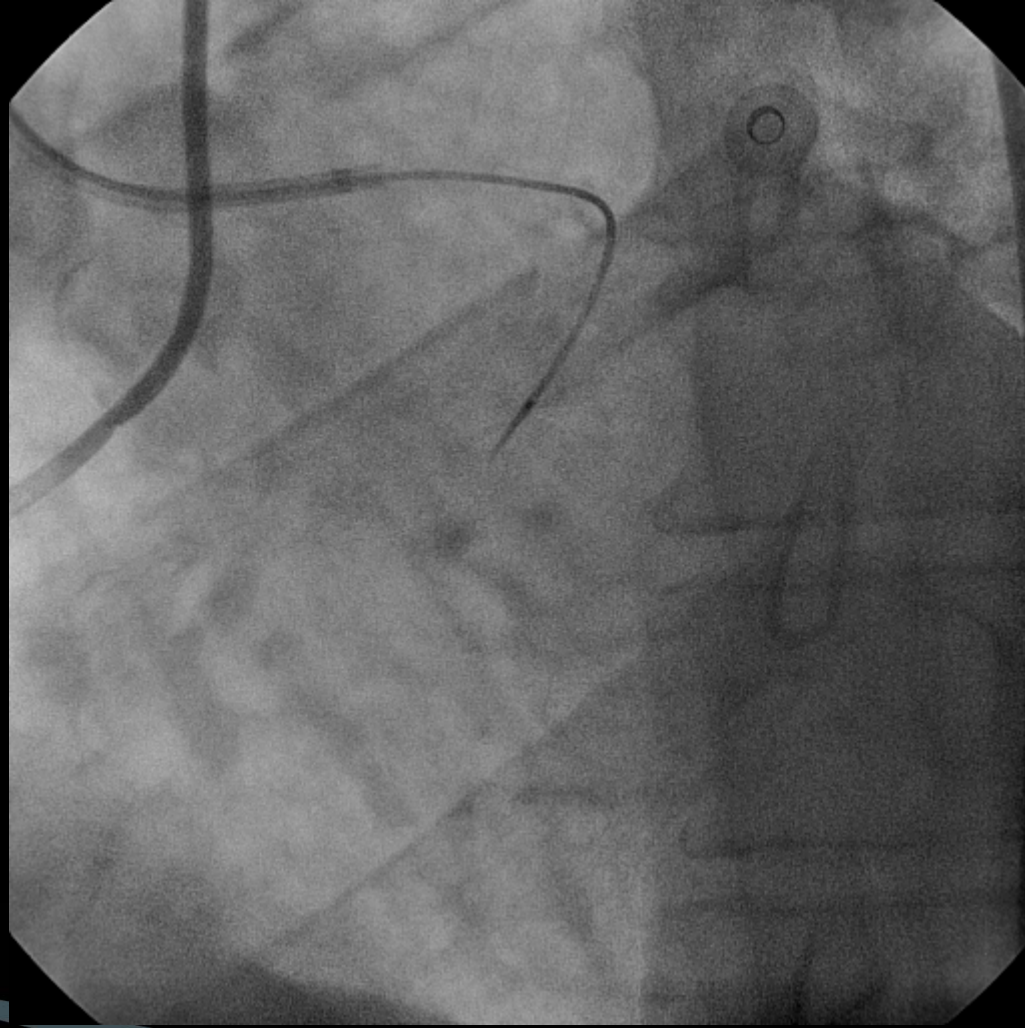
Operatörler: Prof. Dr E Ural, Doç. Dr T Kılıç



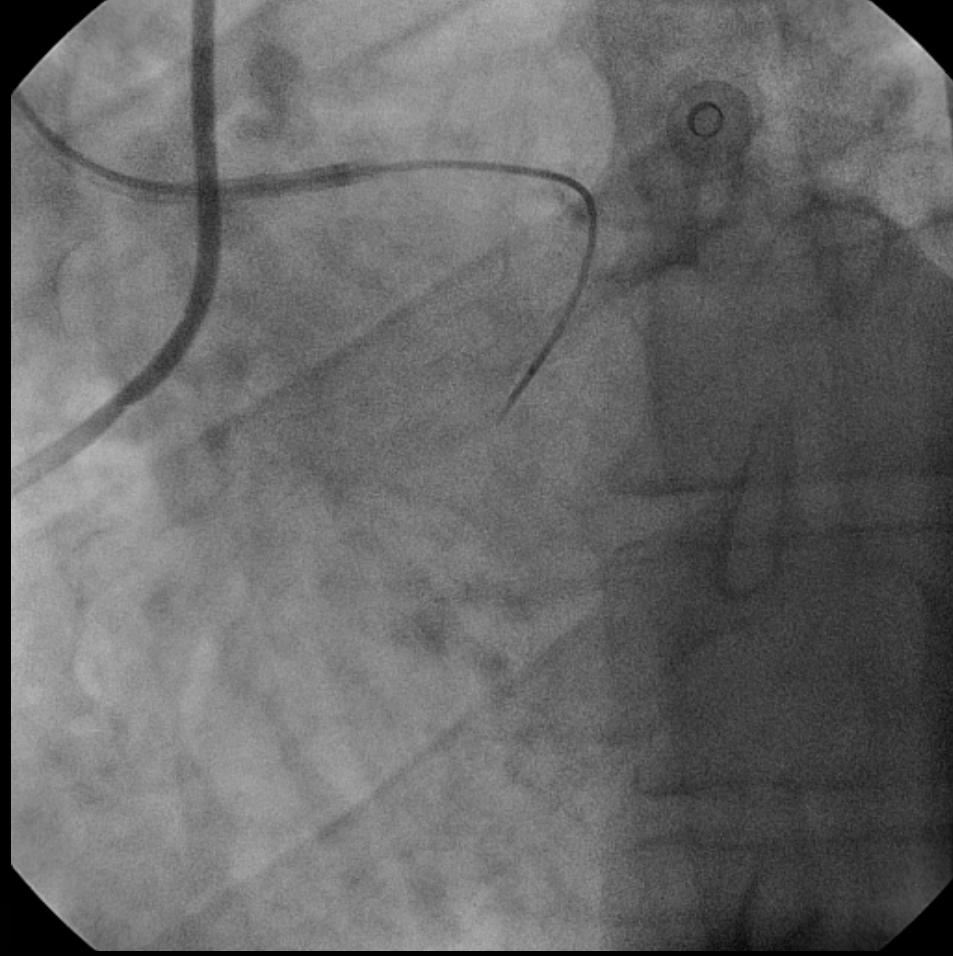
RETROGRAD GİRİŞİM



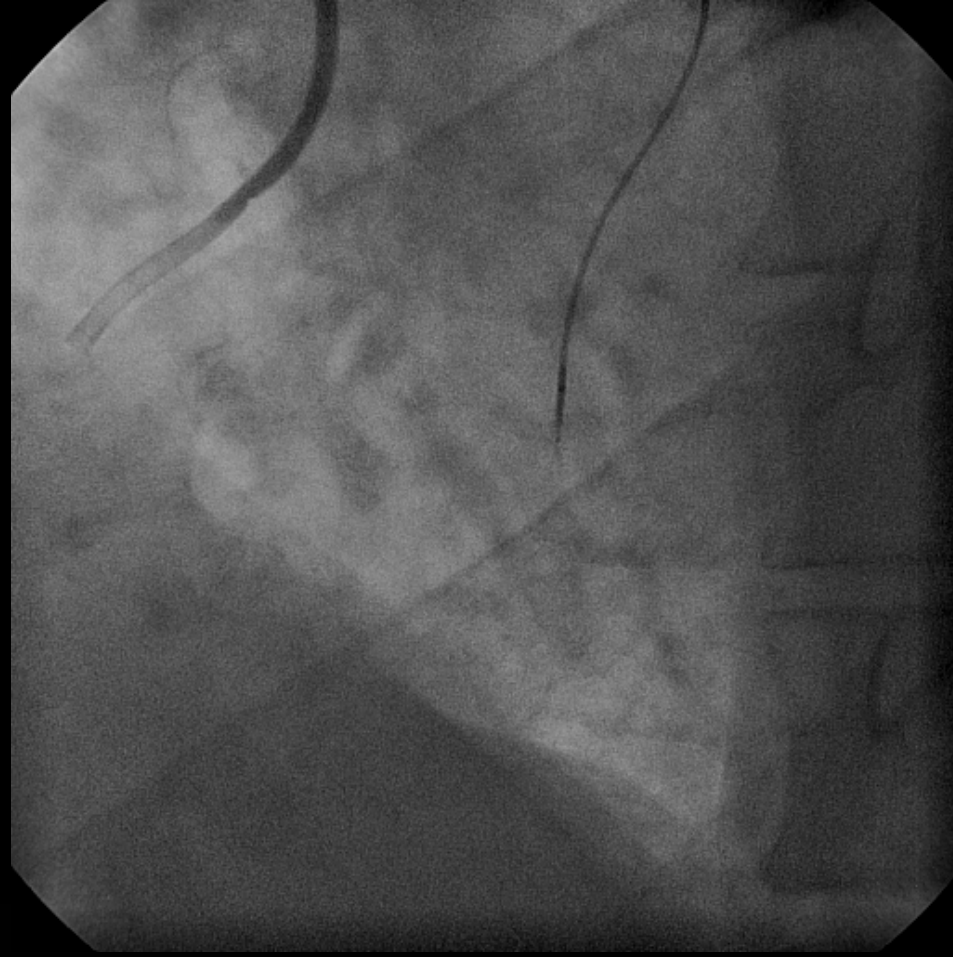
RETROGRAD GİRİŞİM



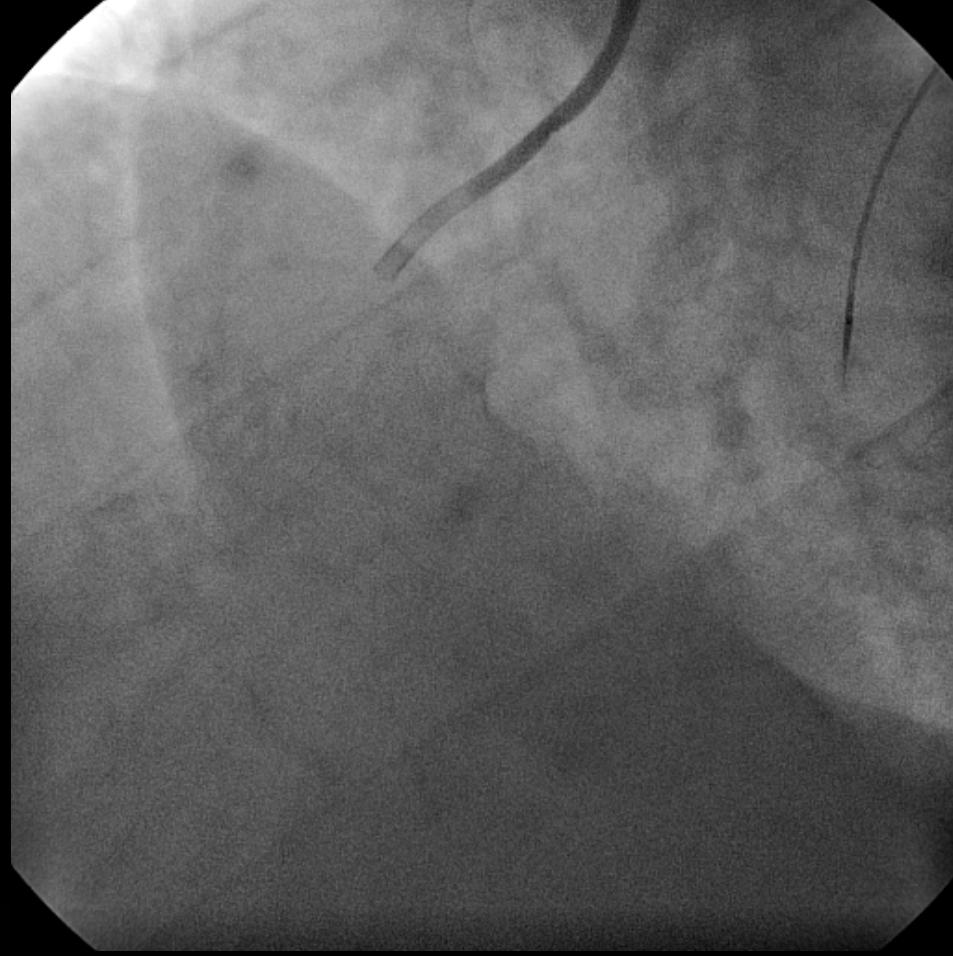
RETROGRAD GİRİŞİM



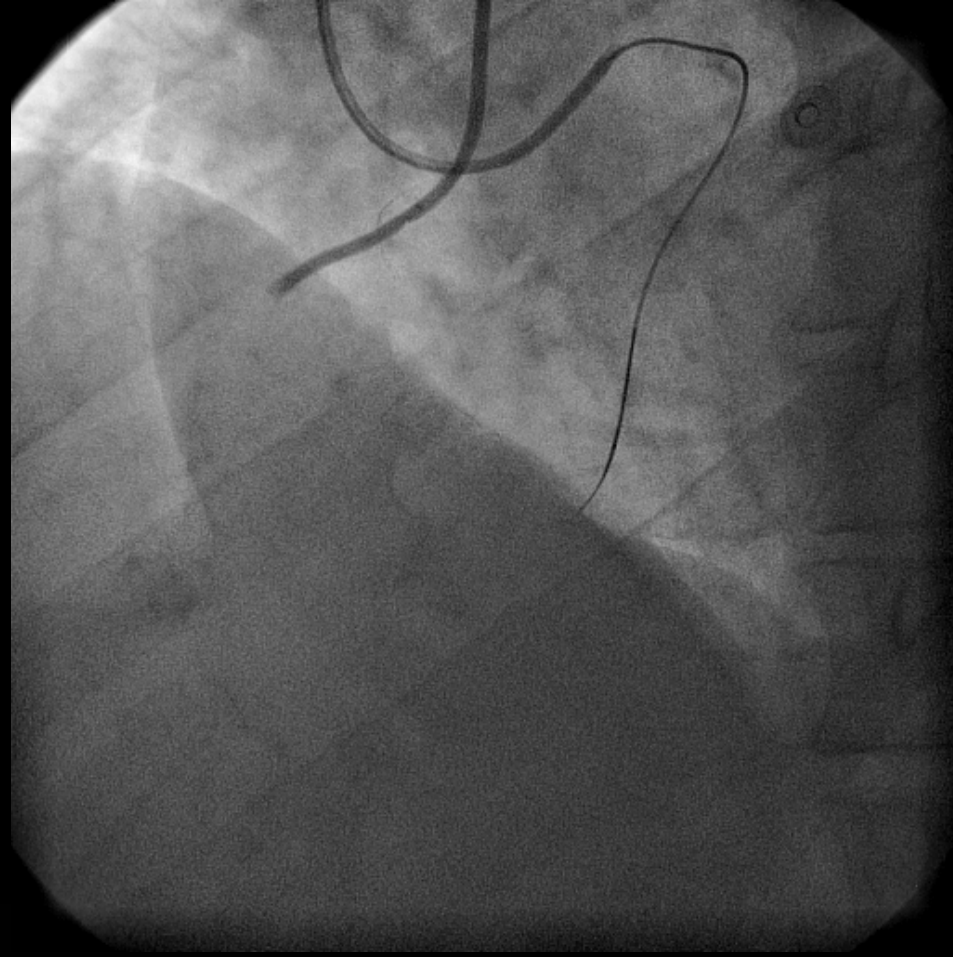
RETROGRAD GİRİŞİM



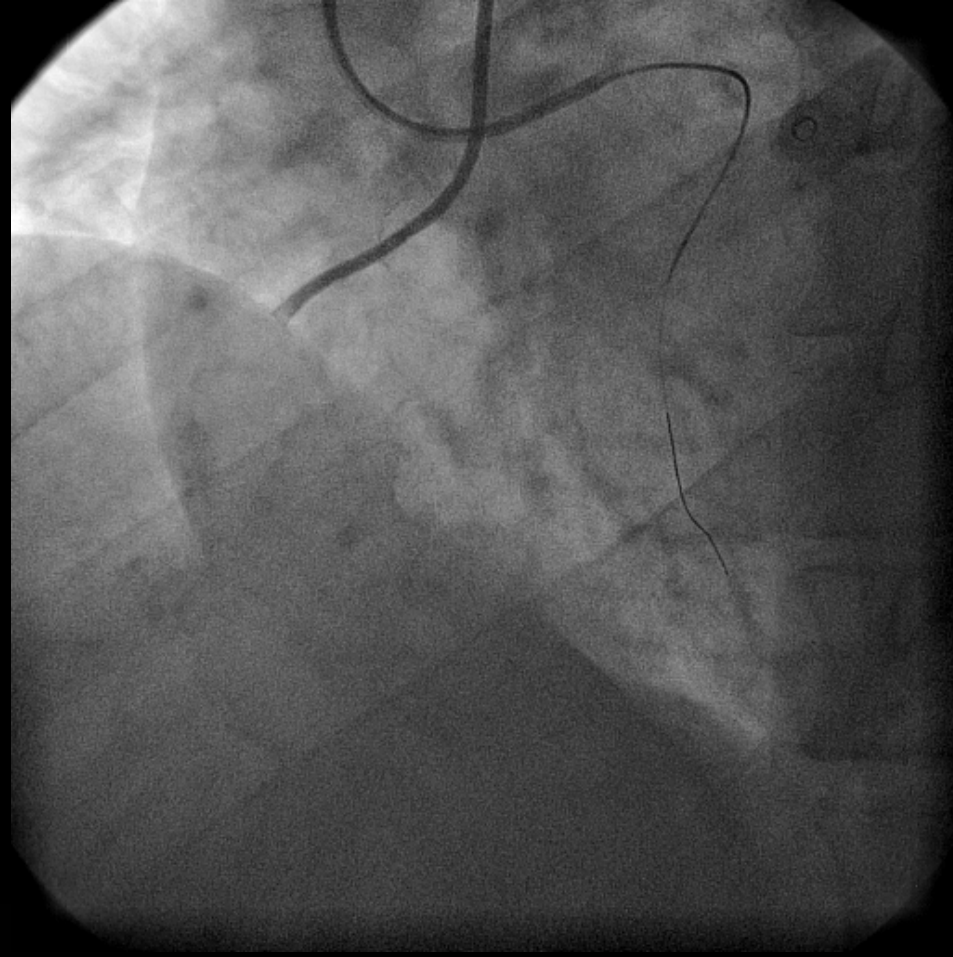
RETROGRAD GİRİŞİM



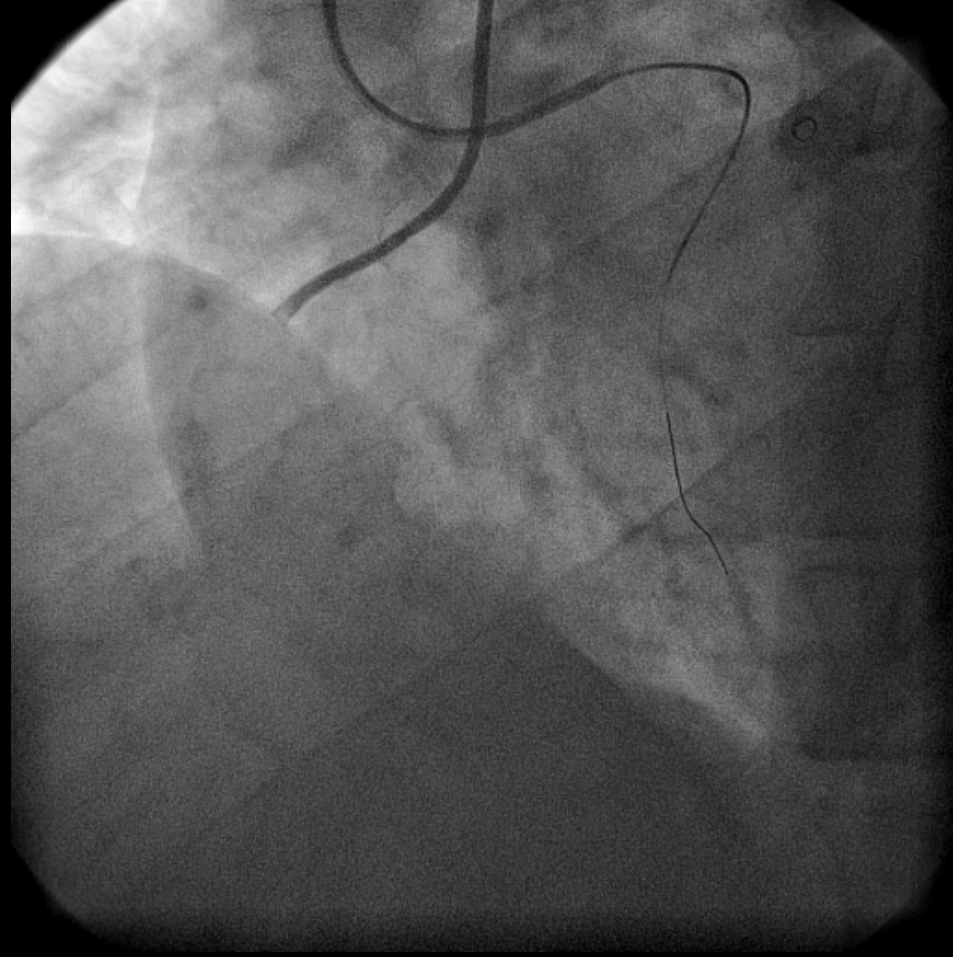
RETROGRAD GİRİŞİM



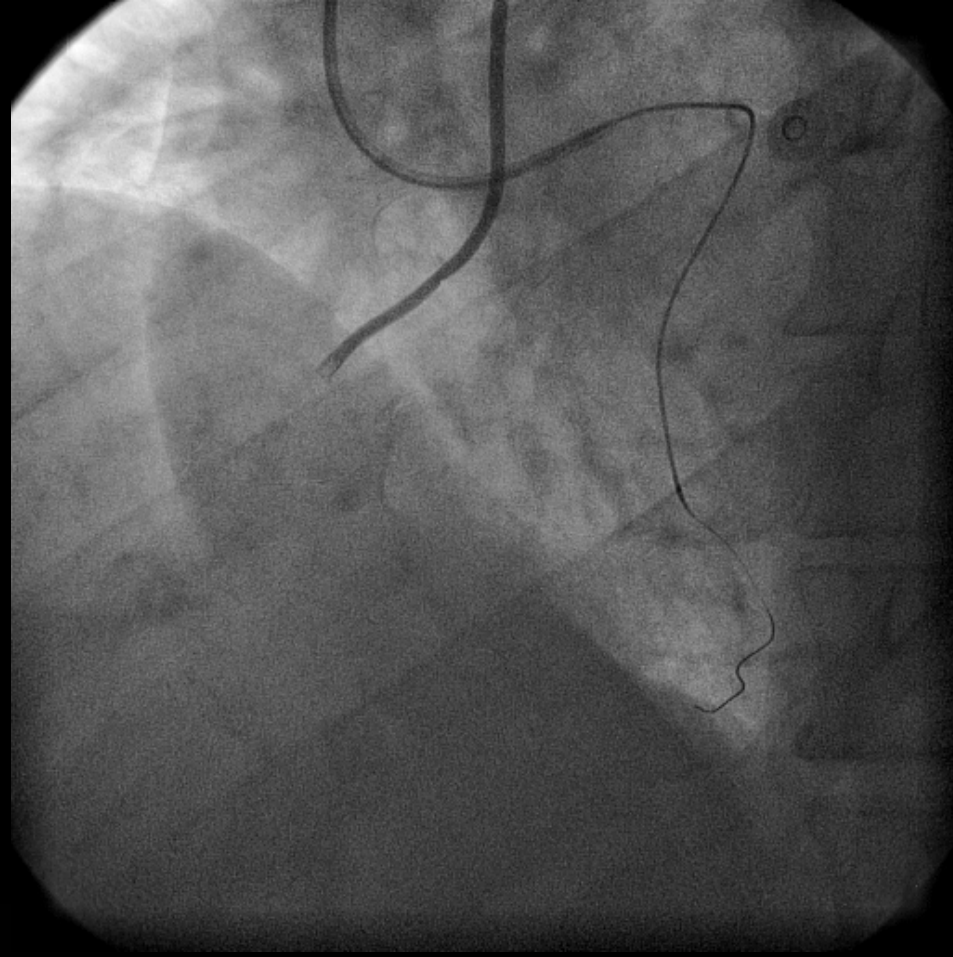
RETROGRAD GİRİŞİM



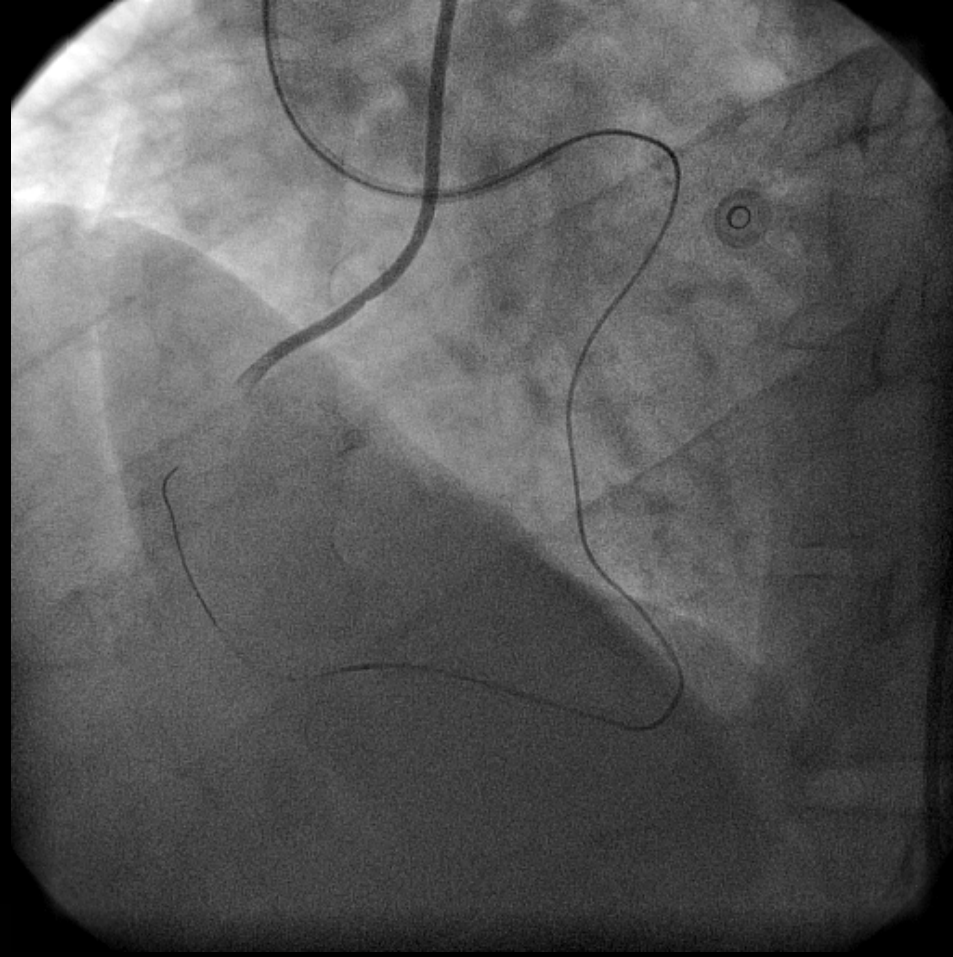
RETROGRAD GİRİŞİM



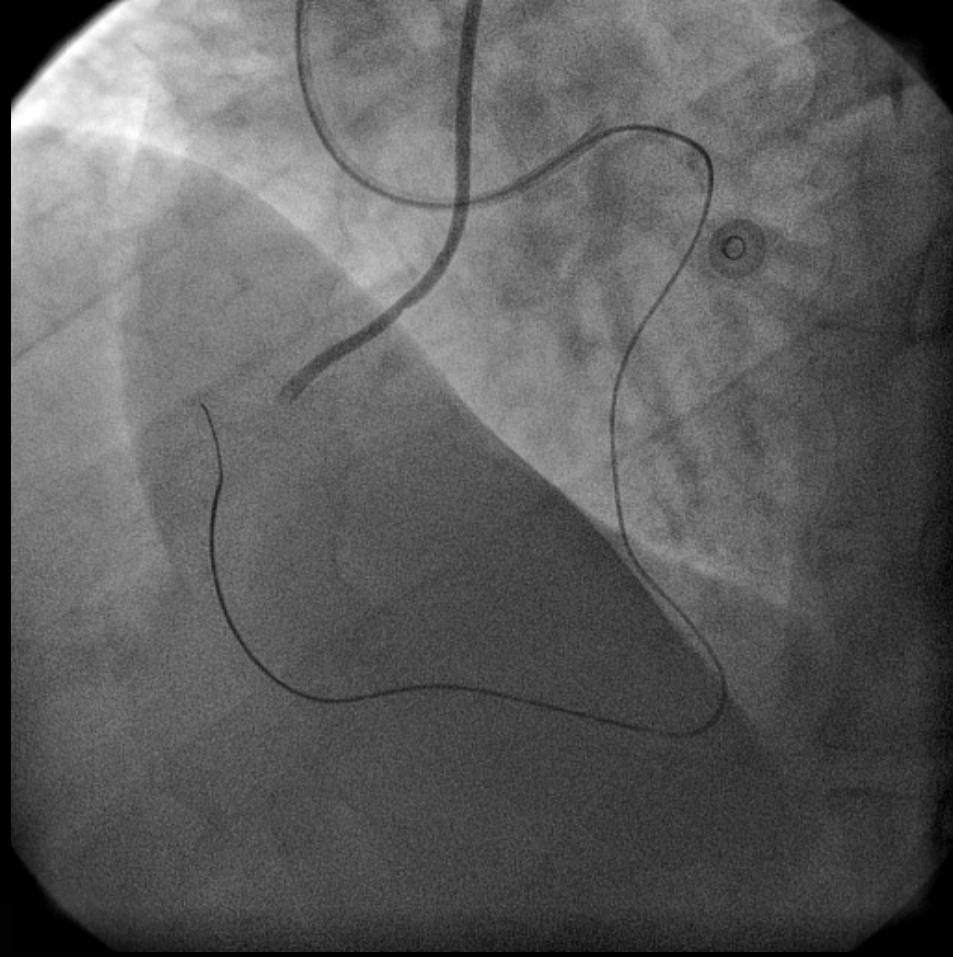
RETROGRAD GİRİŞİM



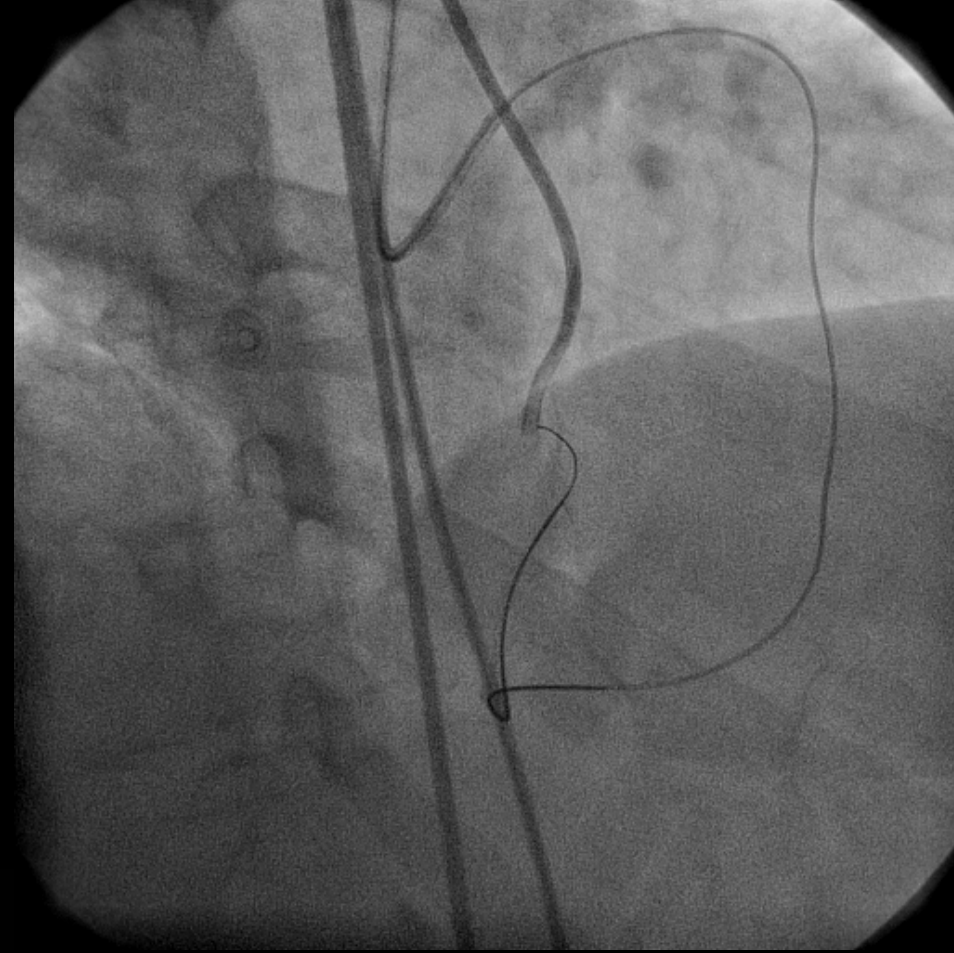
RETROGRAD GİRİŞİM



RETROGRAD GİRİŞİM

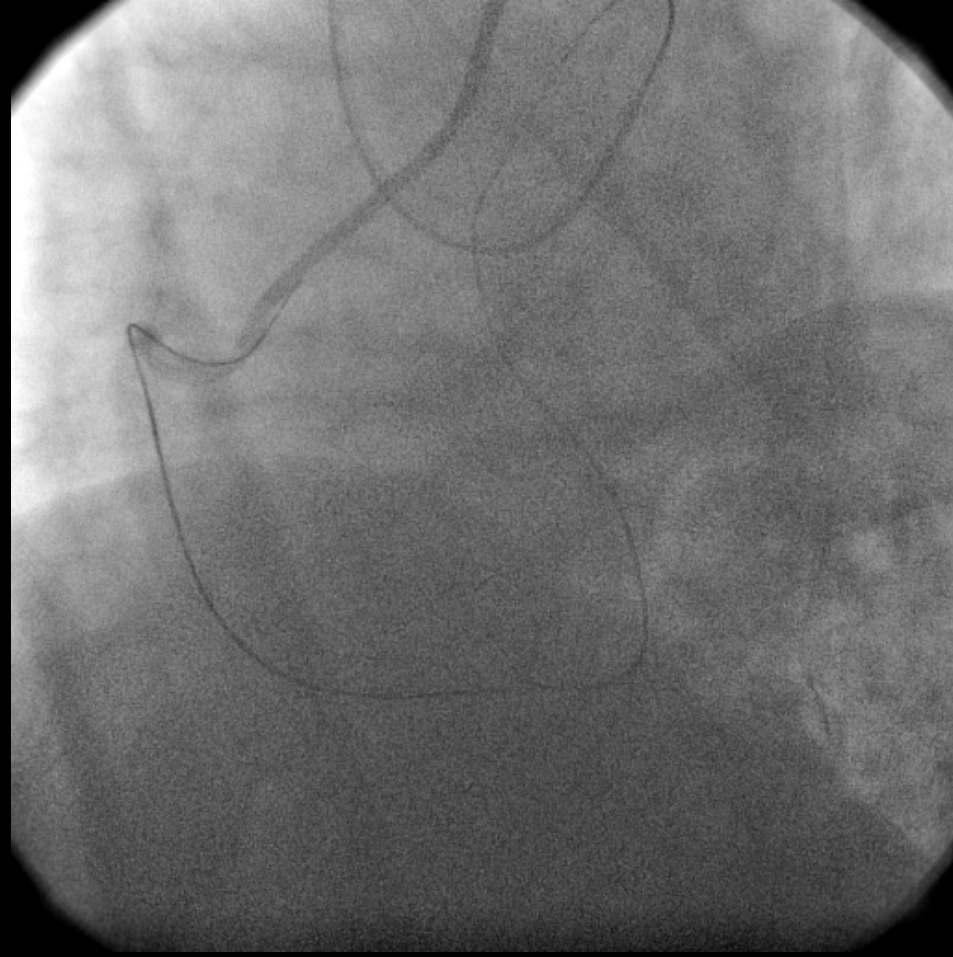


RETROGRAD GİRİŞİM

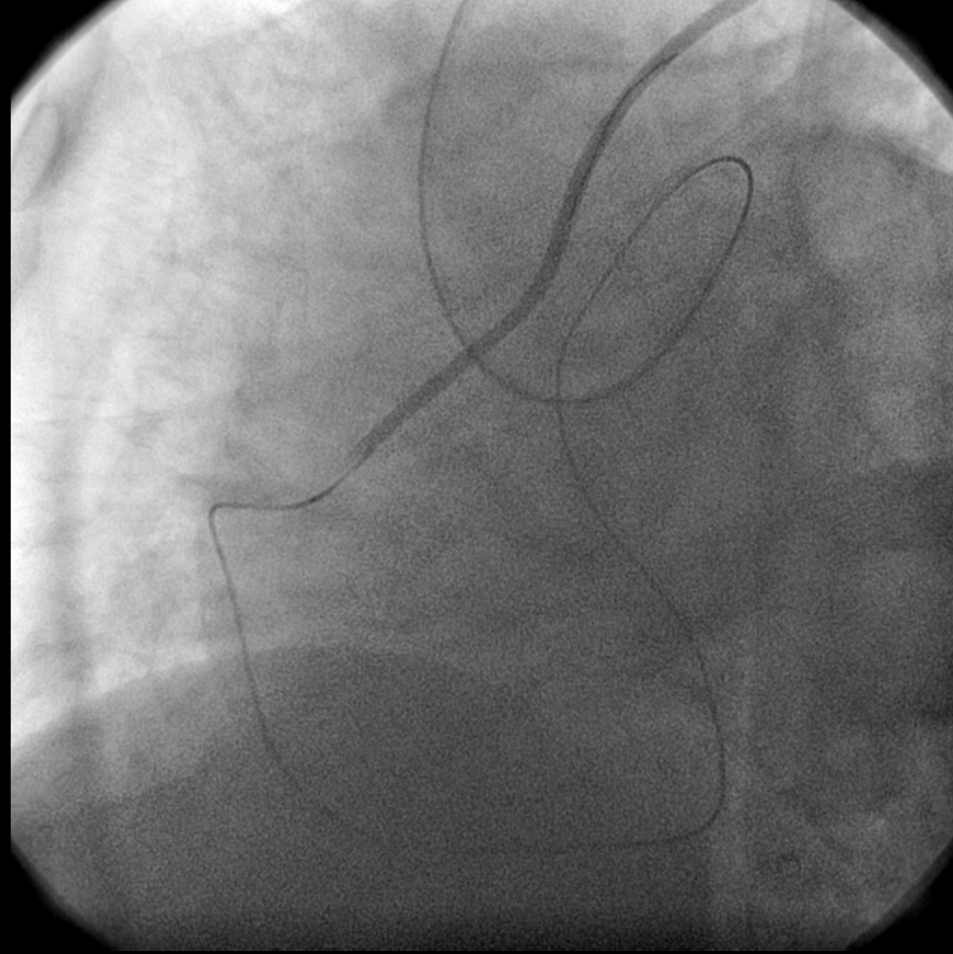


RETROGRAD GİRİŞİM

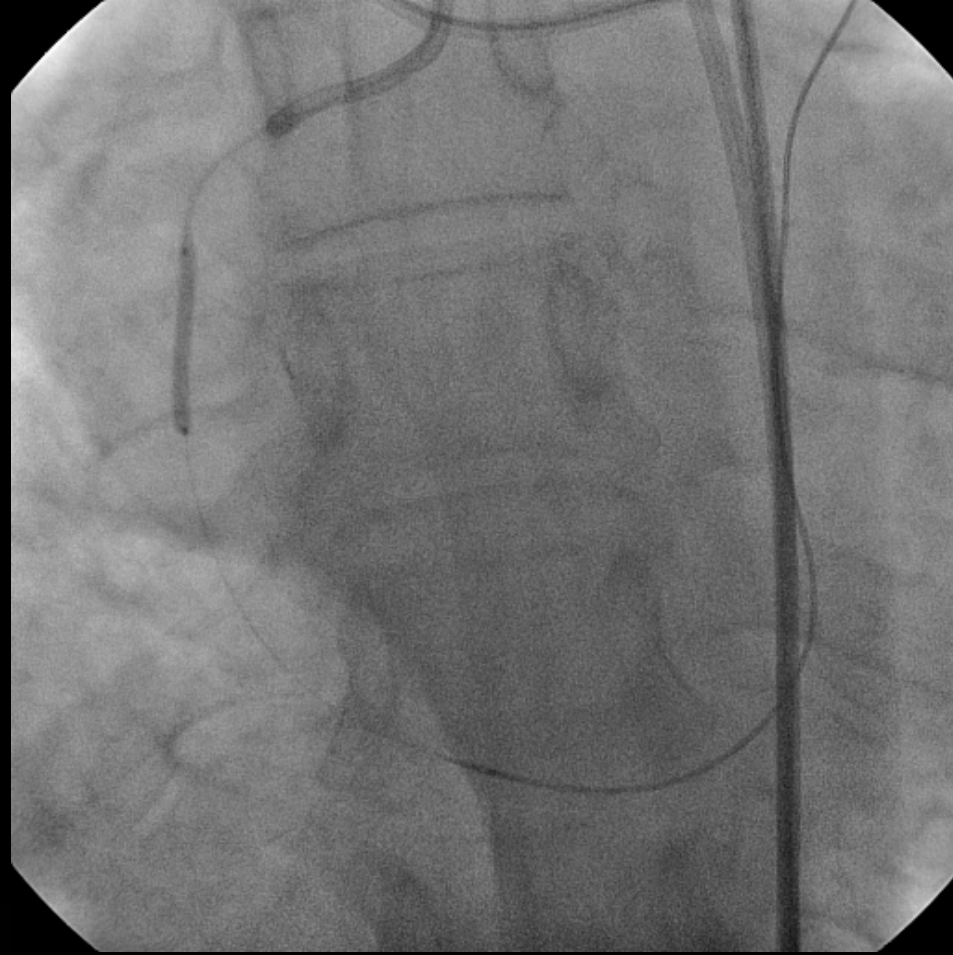
RETROGRAD GİRİŞİM



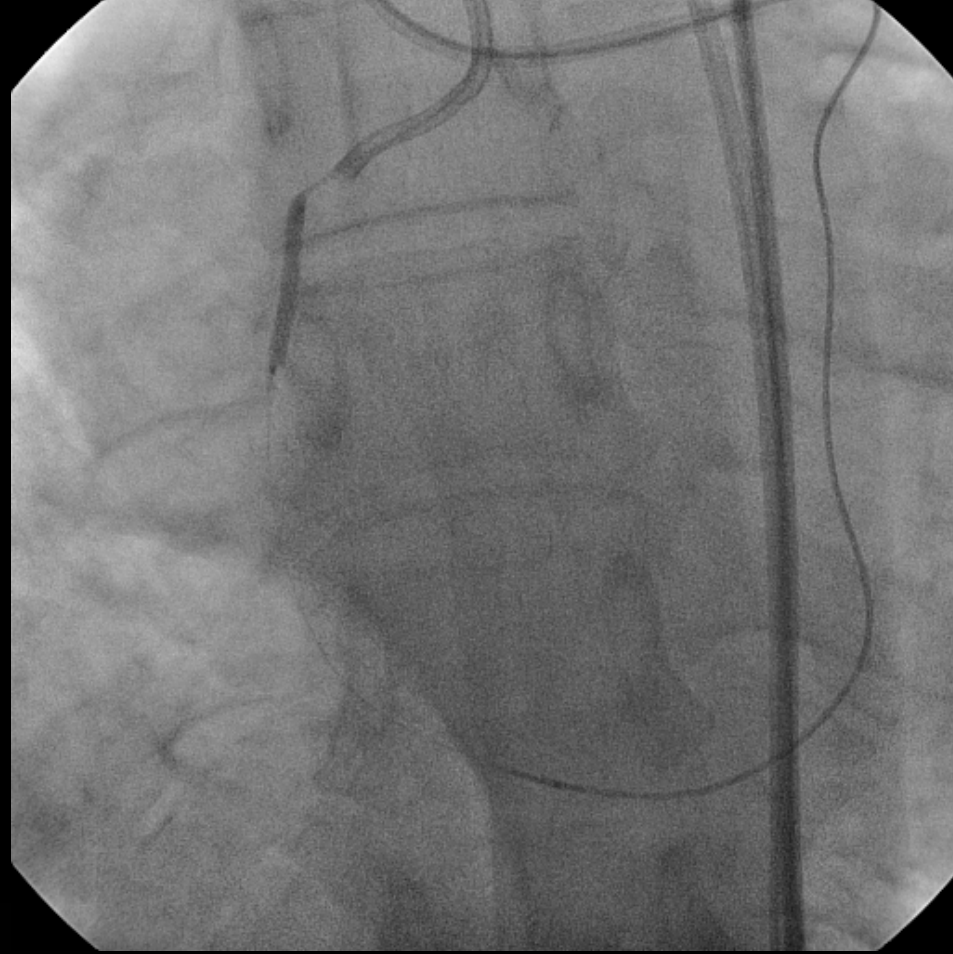
RETROGRAD GİRİŞİM



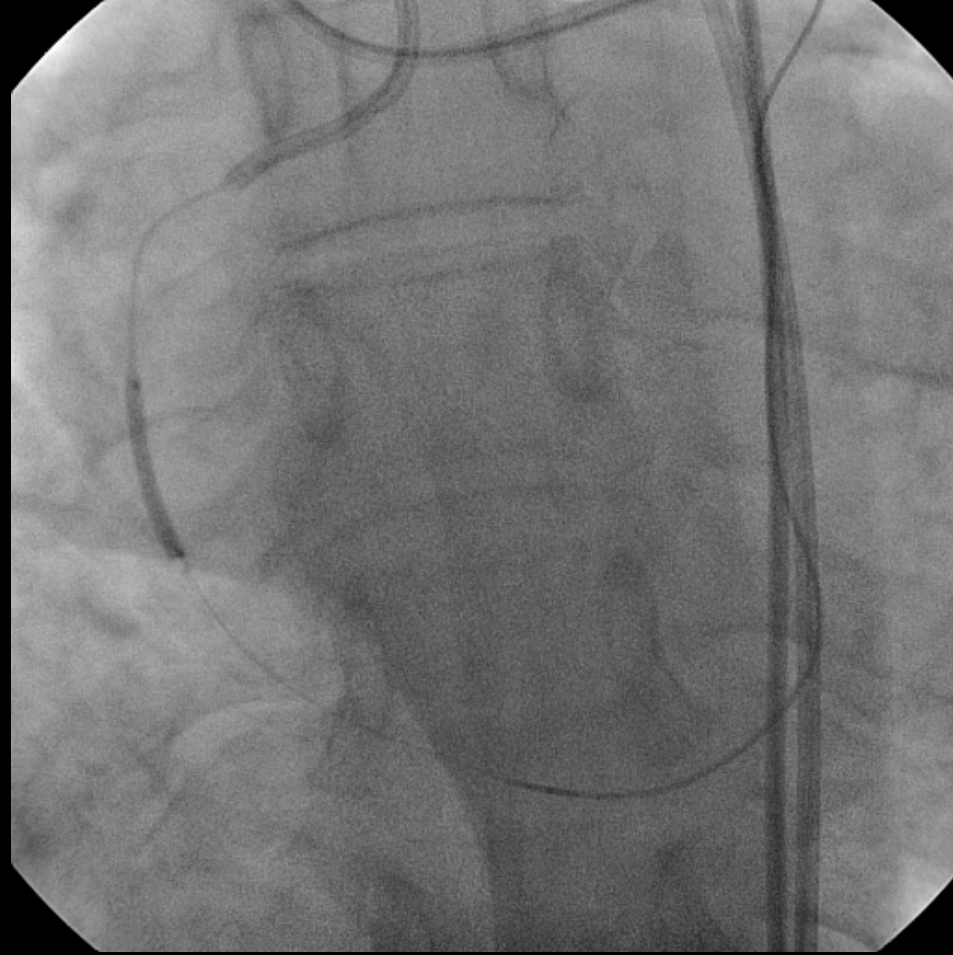RETROGRAD GİRİŞİM



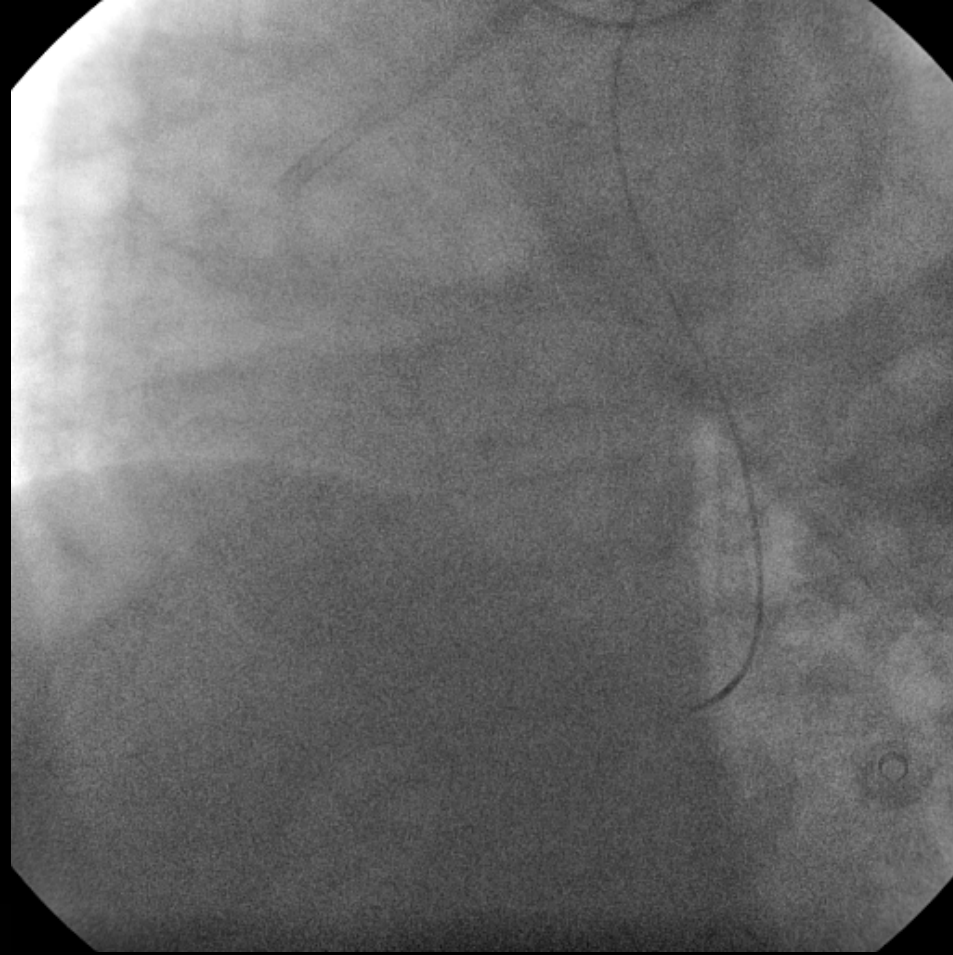
RETROGRAD GİRİŞİM



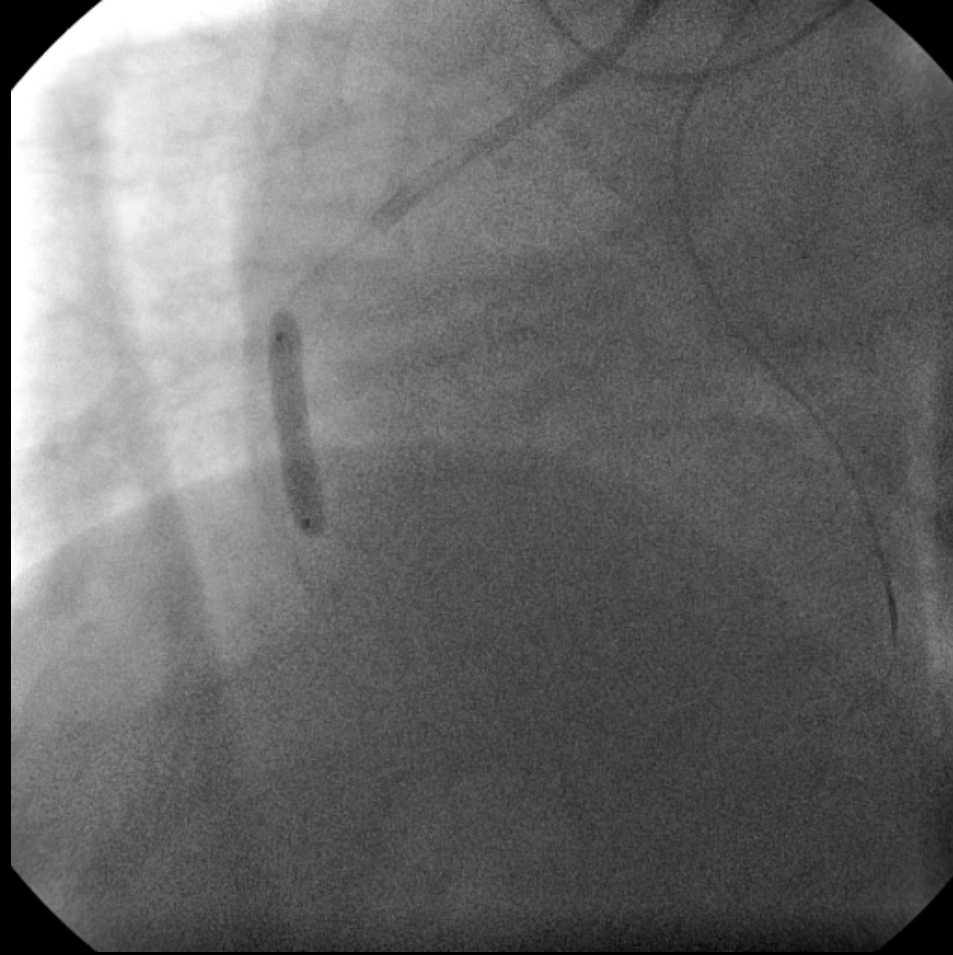
RETROGRAD GİRİŞİM



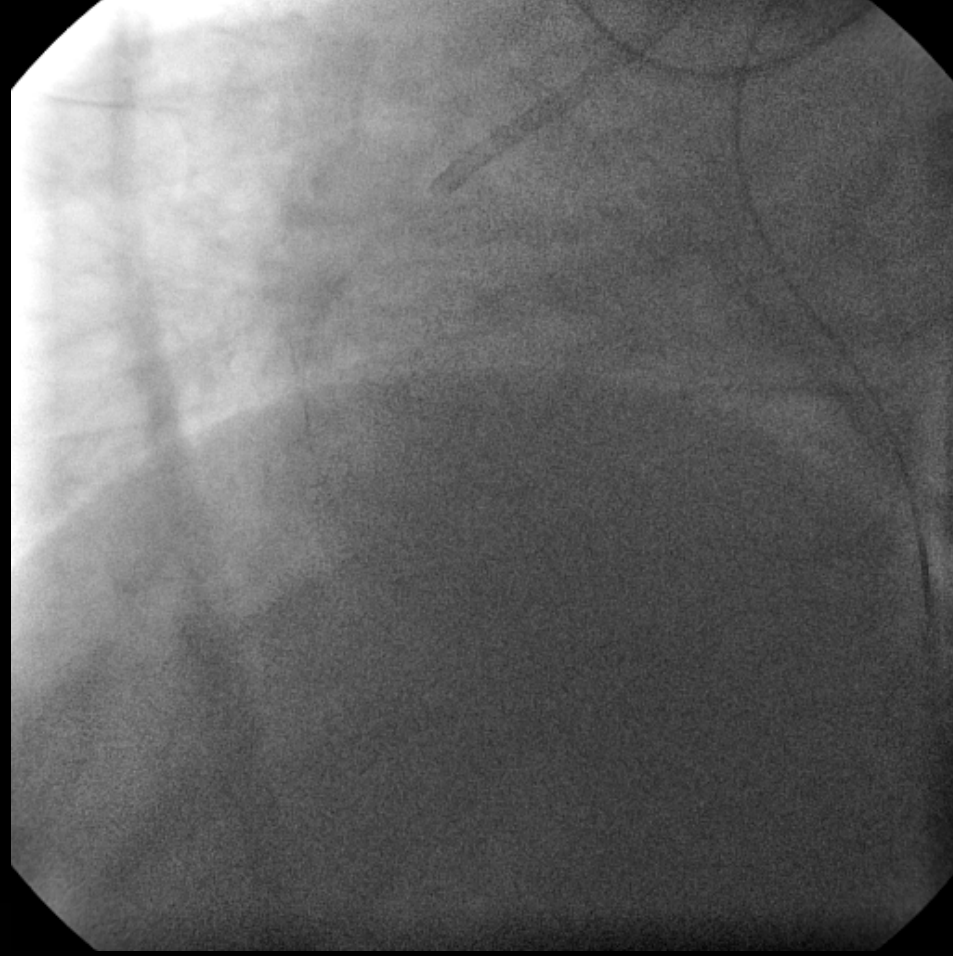
RETROGRAD GİRİŞİM



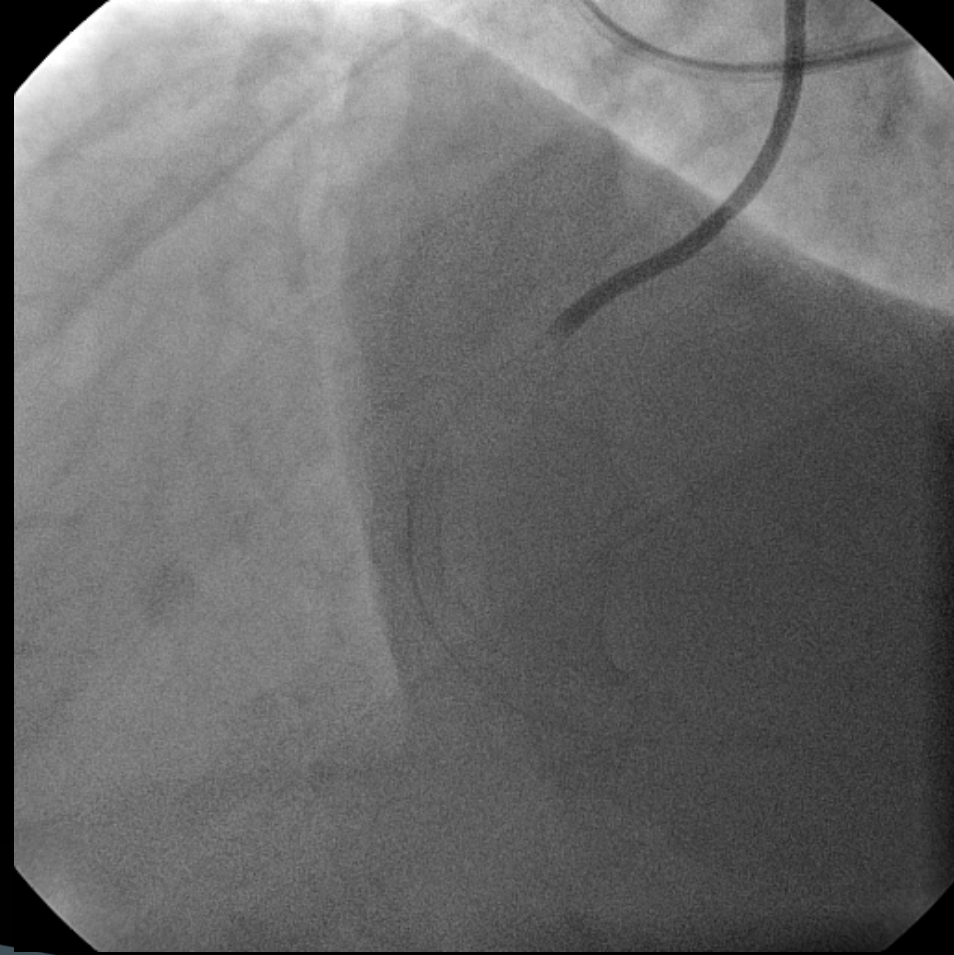
RETROGRAD GİRİŞİM



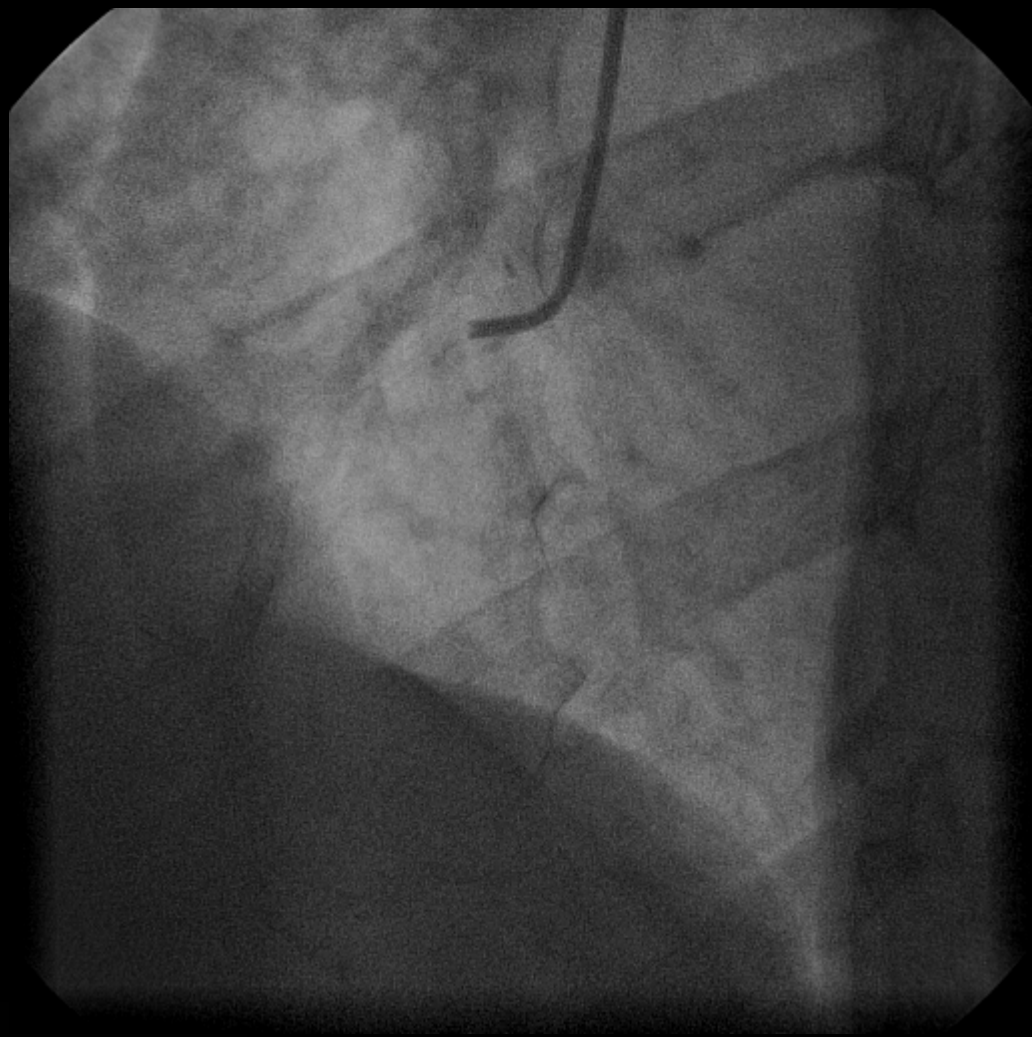
RETROGRAD GİRİŞİM



İşlem süresi:65 dakika
Fluoroskopi skopi süresi:55 dakika
Kontrast miktarı:75 ml



**1 YIL SONRA
KONTROL KORONER ANJİYOGRAFİ**



SABRINIZ İÇİN TEŞEKKÜRLER

KTO DA ANTEGRAD PERKÜTAN REKANALİZASYONUN ZOR OLACAĞININ ÖNGÖRDÜRÜCÜLERİ

- ▶ Uzun süreli oklüzyon
- ▶ Lezyon uzunluğu
- ▶ Kalsifikasyon
- ▶ Ucu sivri veya giderek sivrileşen bir güdükten ziyade keskin sivri olmayan (kör) bir oklüzyon varlığı (Antegrad akımın yokluğu)
- ▶ Oklüzyonun olduğu noktada yan dal varlığı
- ▶ Bridge kollaterallerin varlığı
- ▶ Distal damar yatağının hiç görülmeysisi
- ▶ Damarın tortuöz olduğu yerde oklüzyon
- ▶ Ostiyal lokalizasyon
- ▶ Daha önce başarısız girişim