

LAD osteal CTO müdahalesi

Prof. Dr. Bülent Behlül Altunkeser

Doç. Dr. Nazif Aygöl

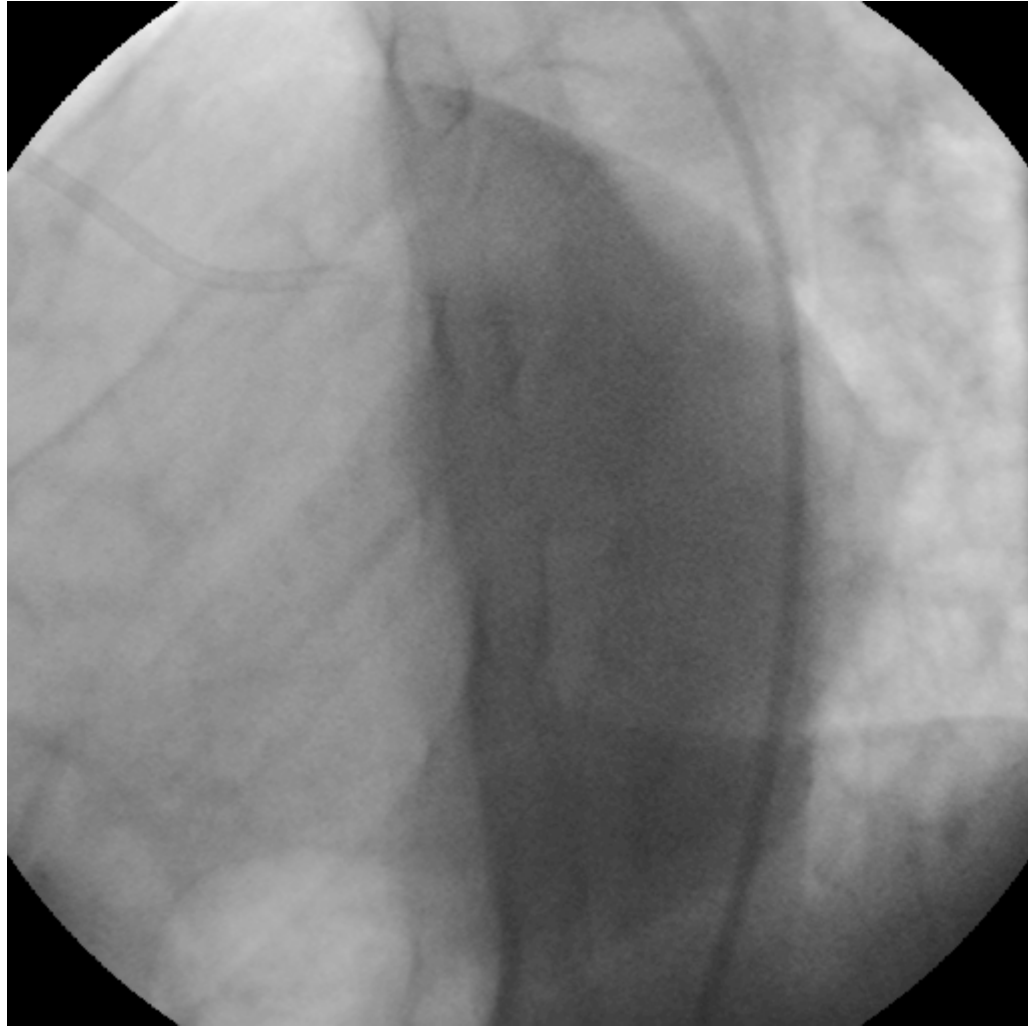
Selçuk Üniversitesi, Selçuklu Tıp Fakültesi

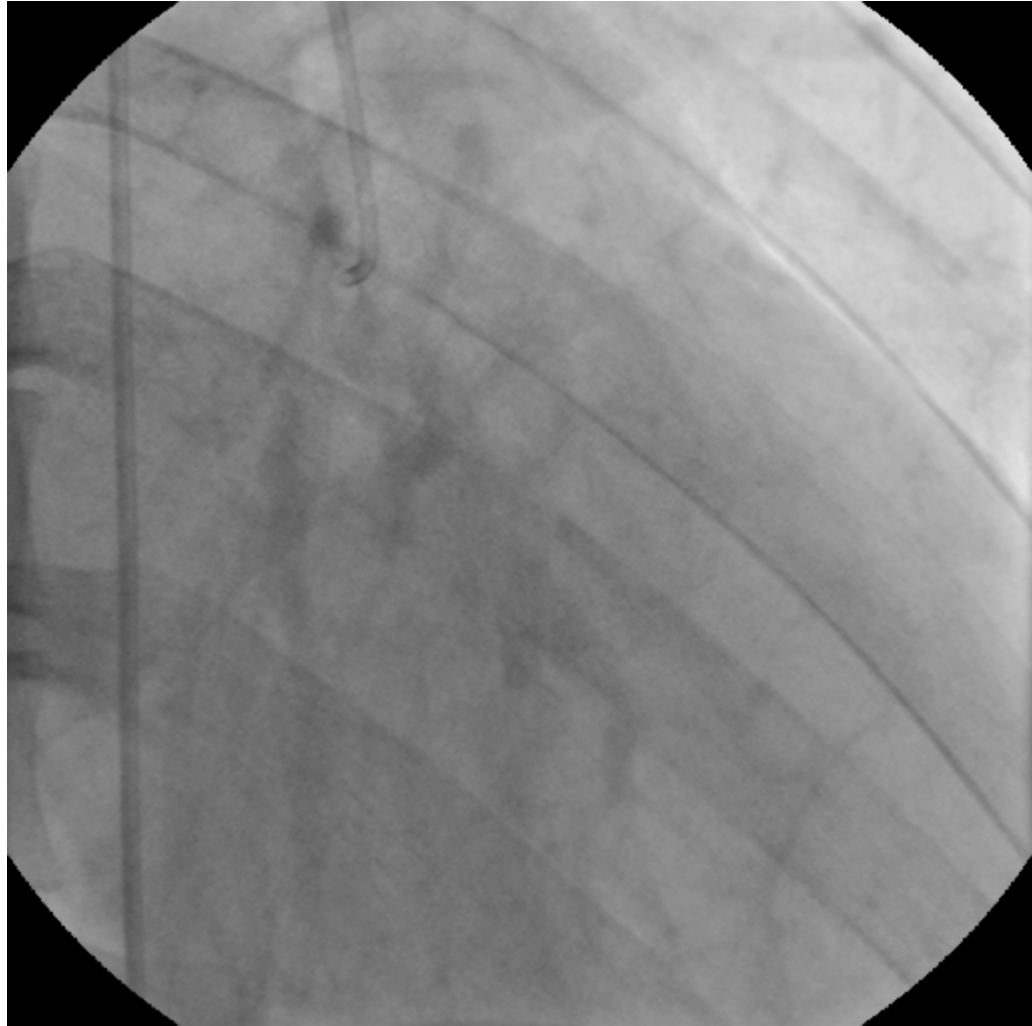
Konya

- 33 yaşında erkek hasta,
- 3 aydır 20 dakika süren tipik göğüs ağrısı,
- Risk faktörü: sigara, heredite
- EKG: V4-V6 arası T menfiliği,
- Lab: LDL-K: 143 mg/dL
- EKO: EF %40, anterior duvar hipo, akinezi, anterior septum akinetik, inferior duvar orta-apikali hipo, apikal segmentte küçük anevrizma

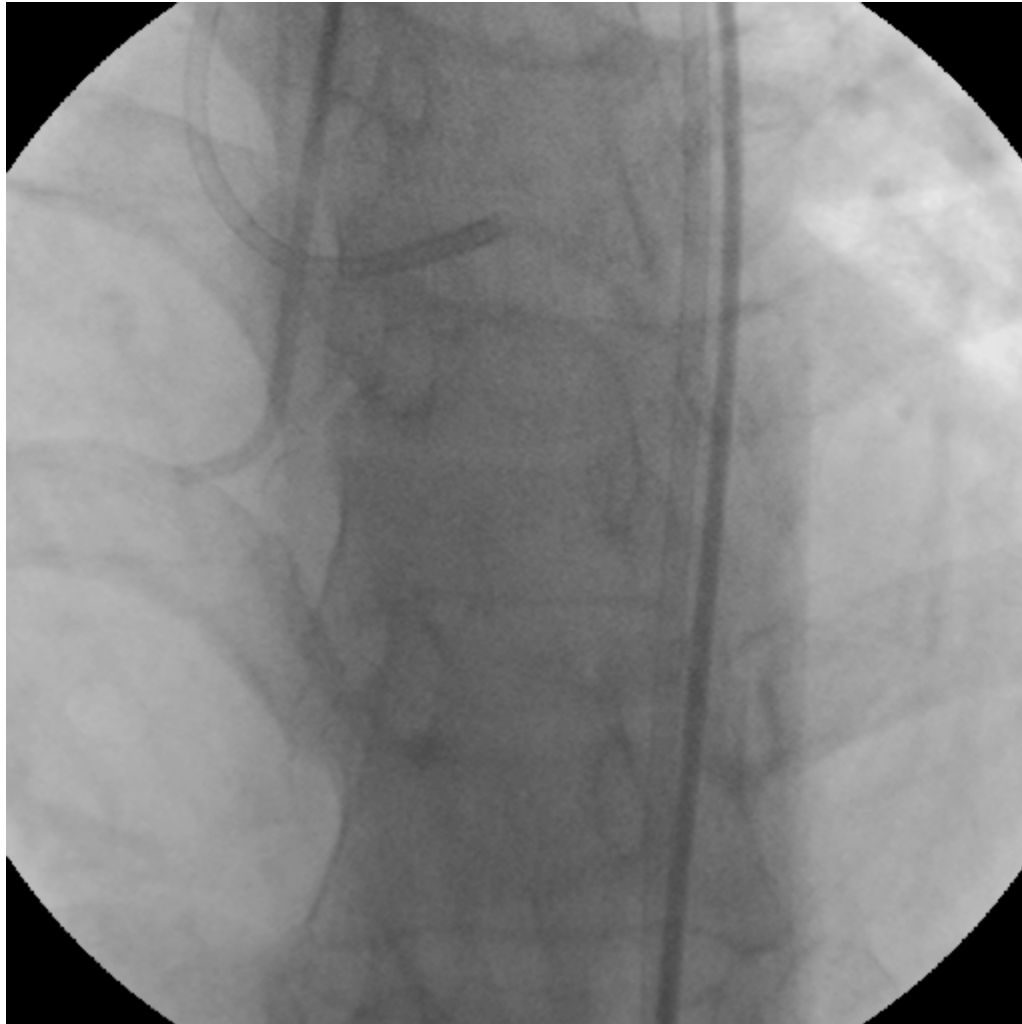
KAG

- LMCA: normal
- LAD: %100, hedef lezyon
- LCx: normal
- RCA: normal

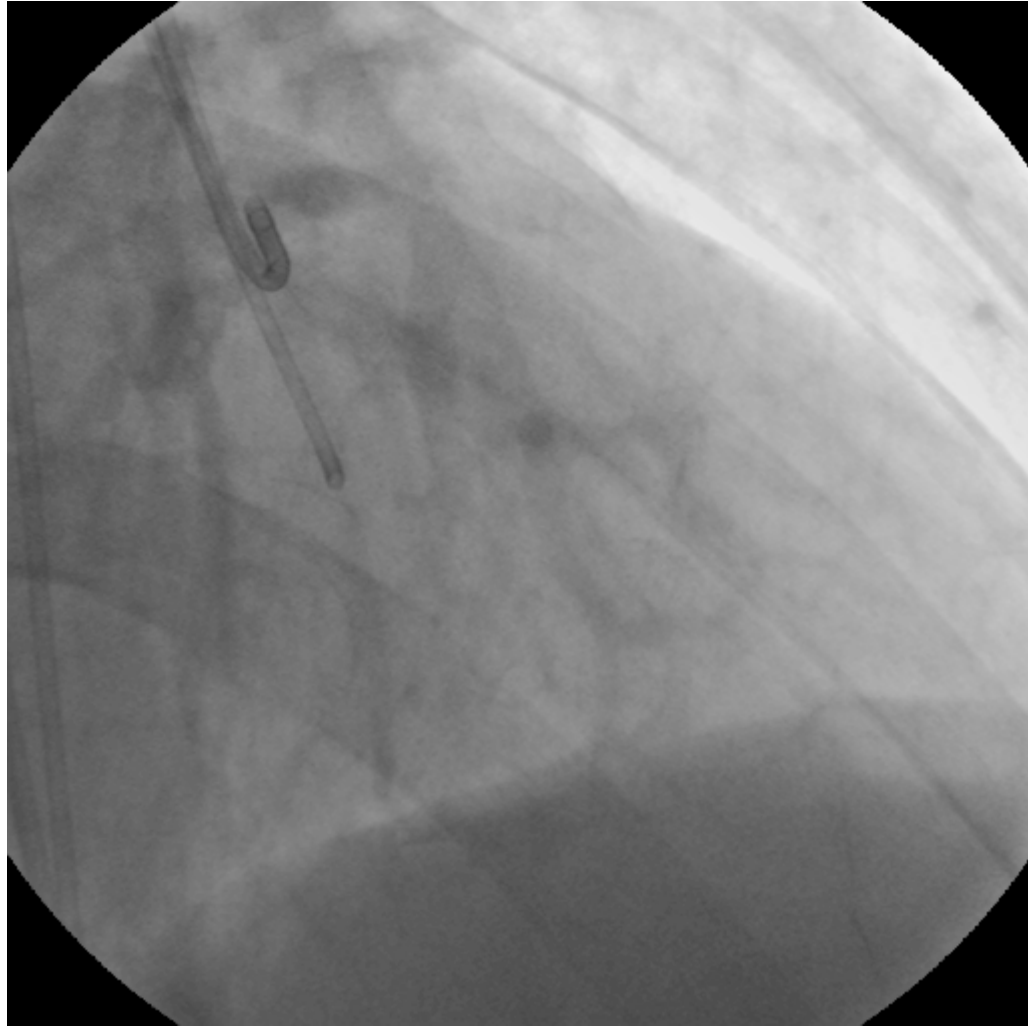


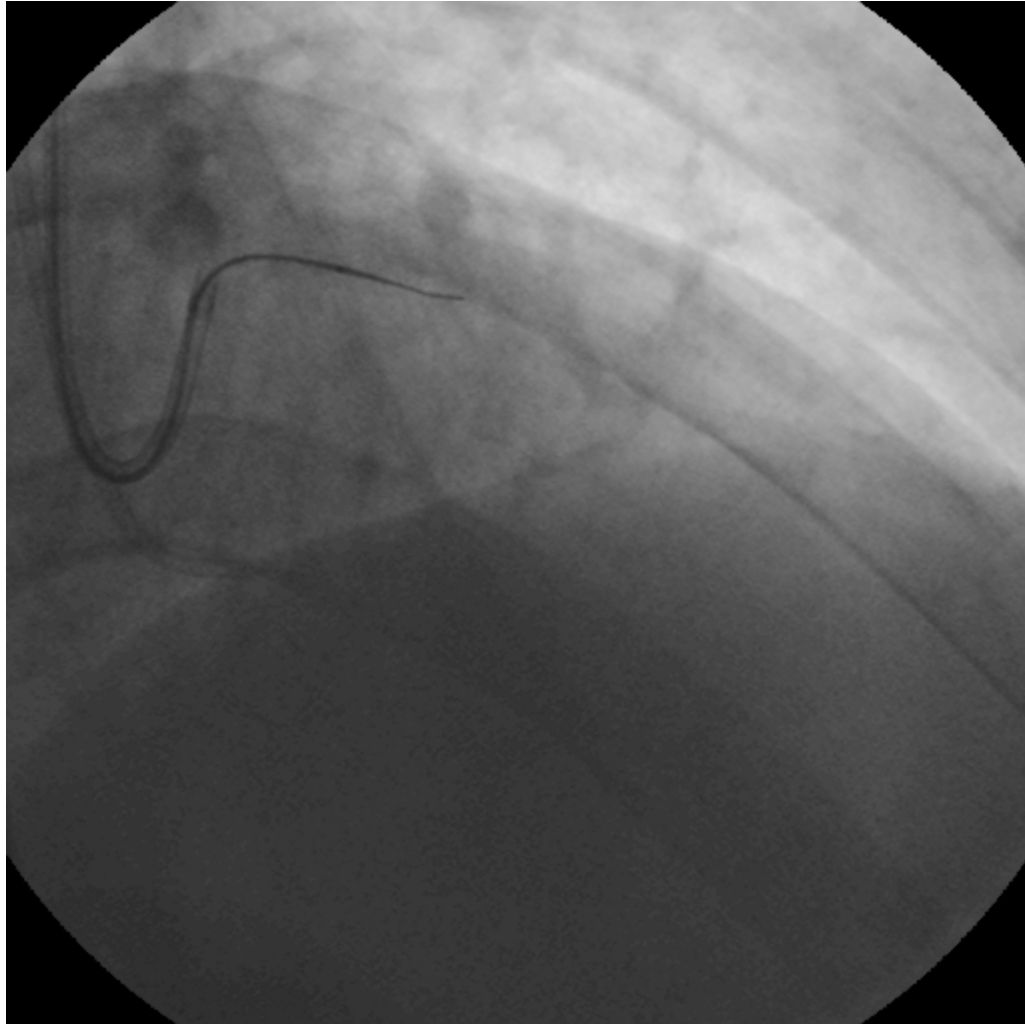


PCI

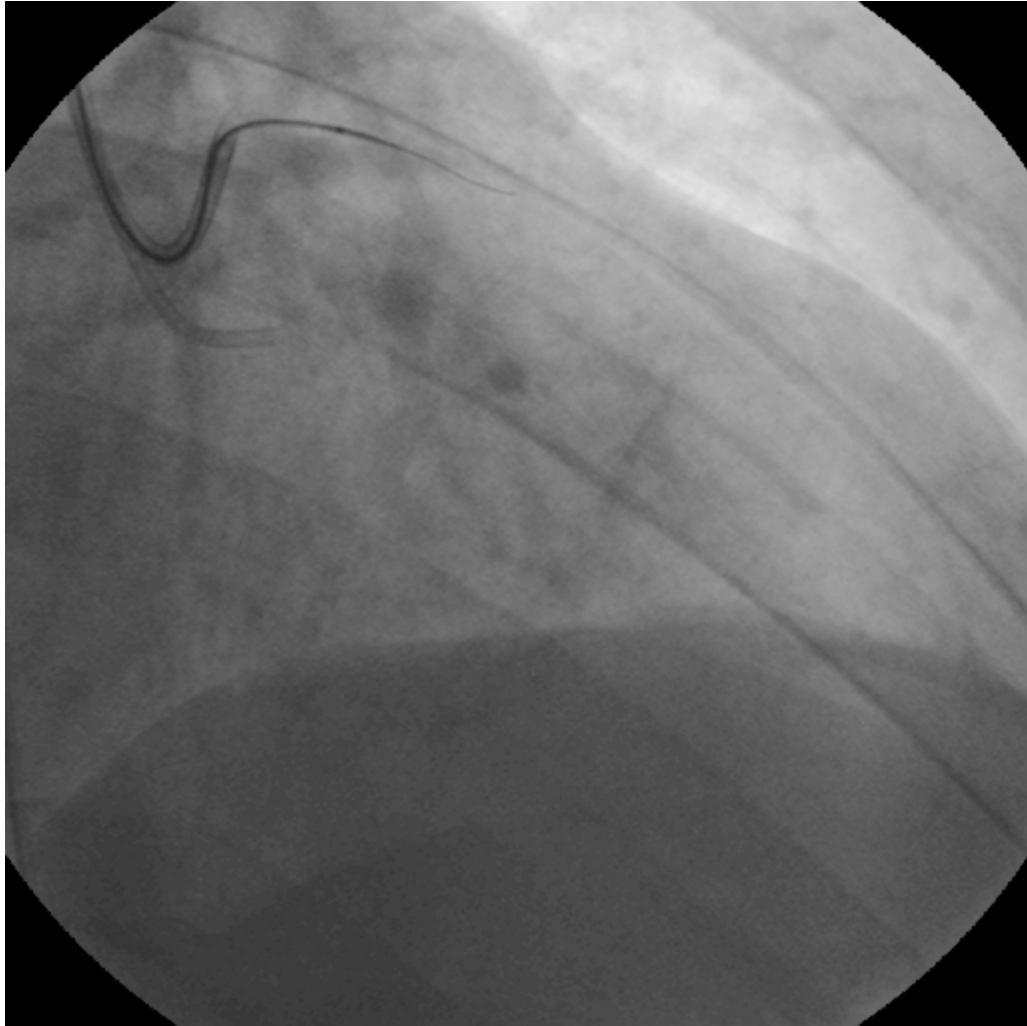


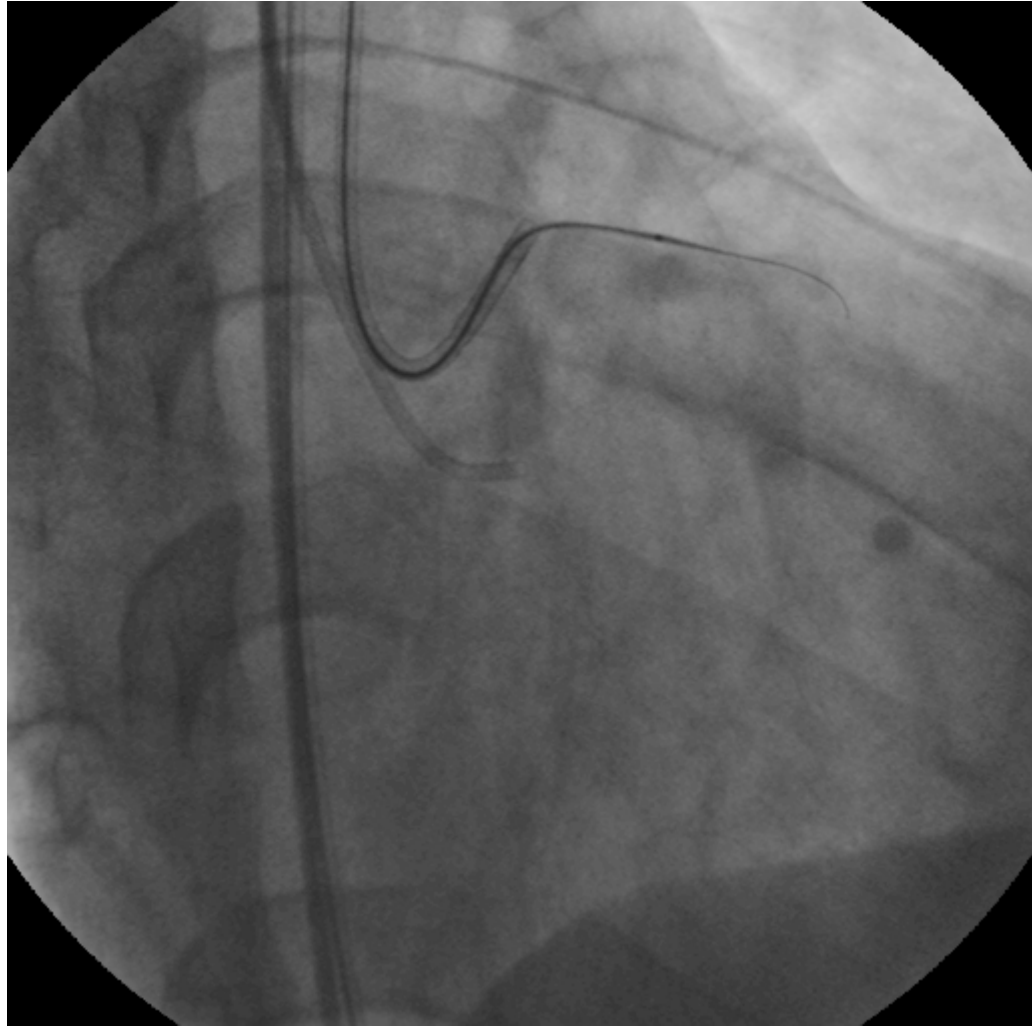
Sol EBU
Sağ diagnostik

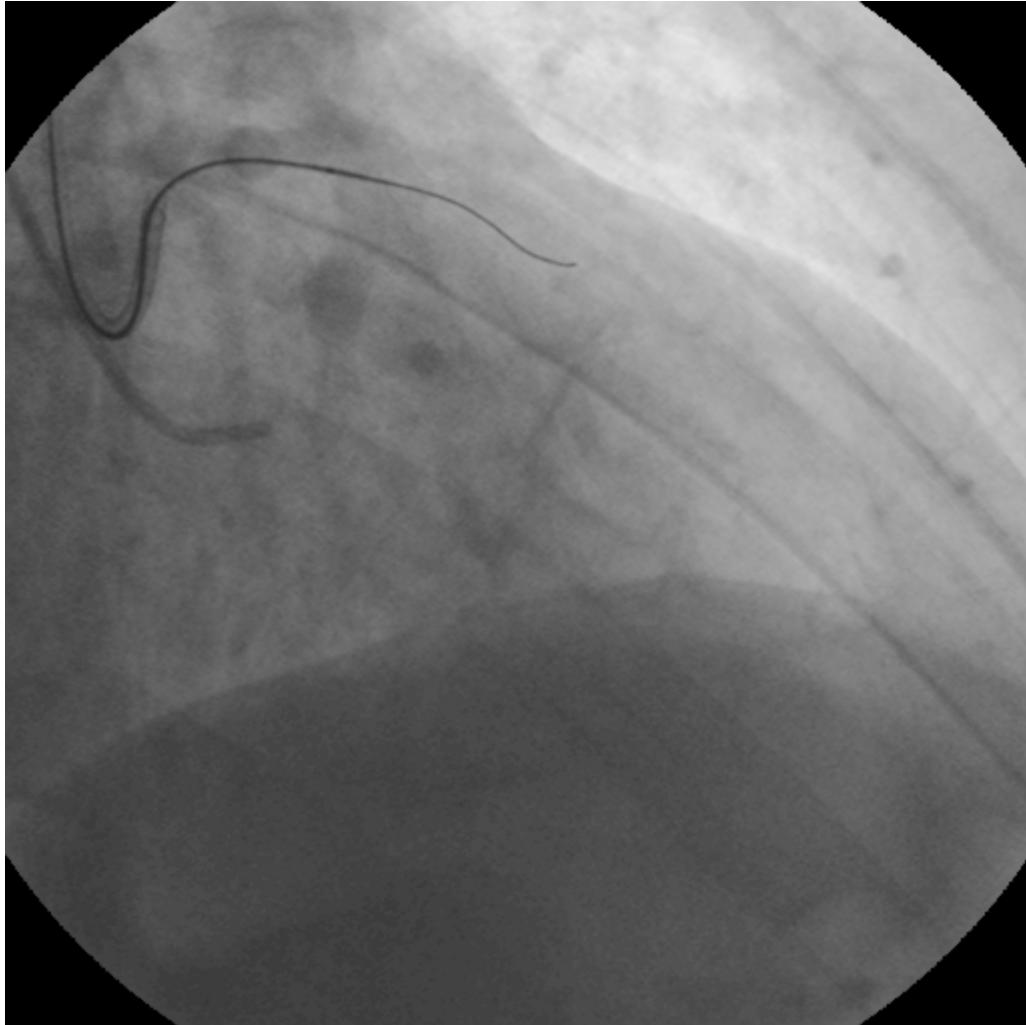




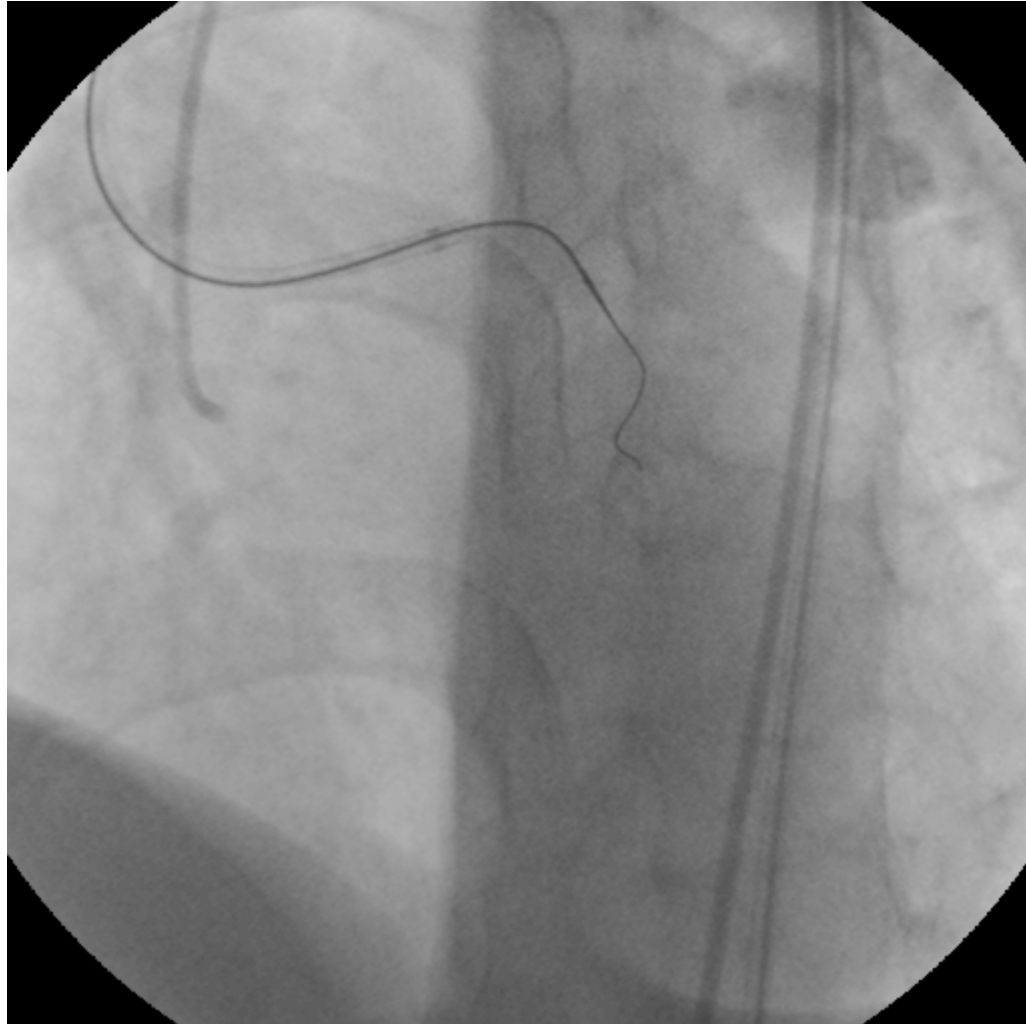
Corsair
Fielder XT



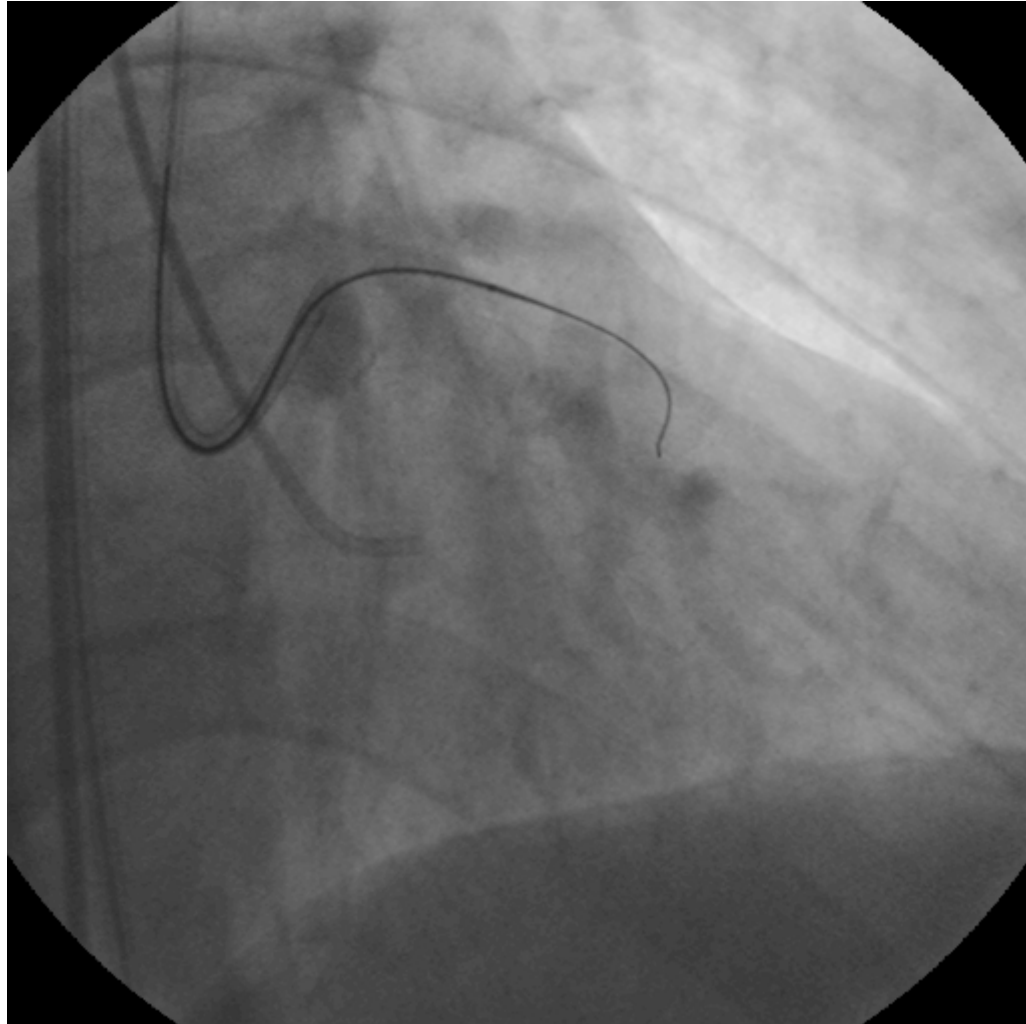




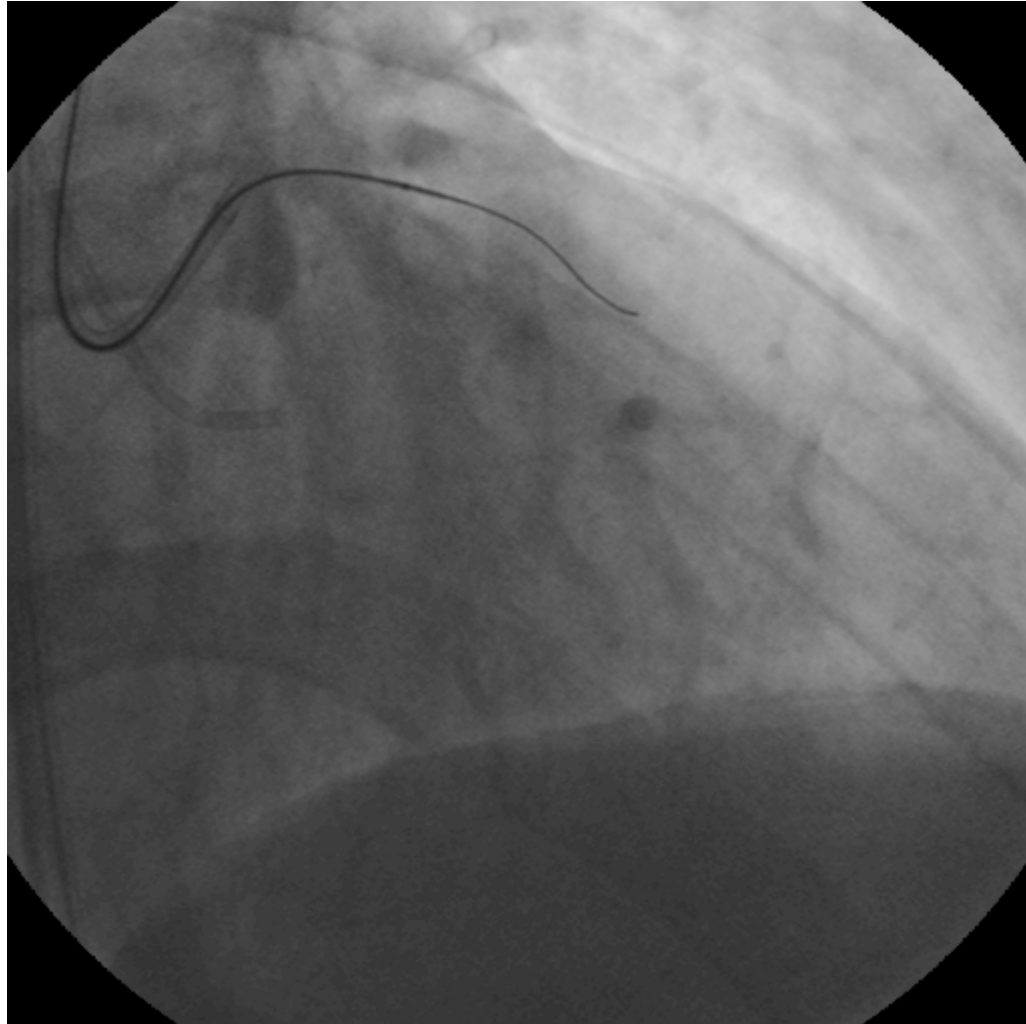
Rinato



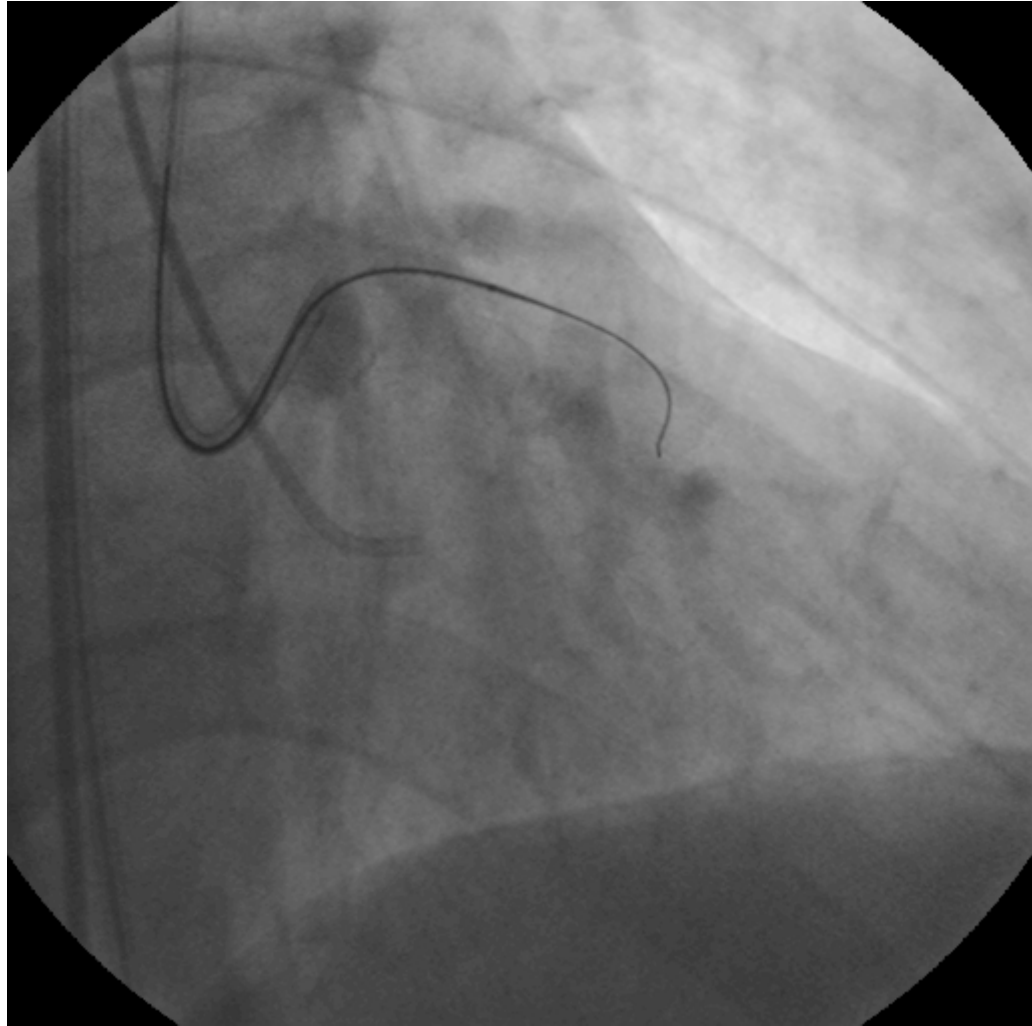
Rinato

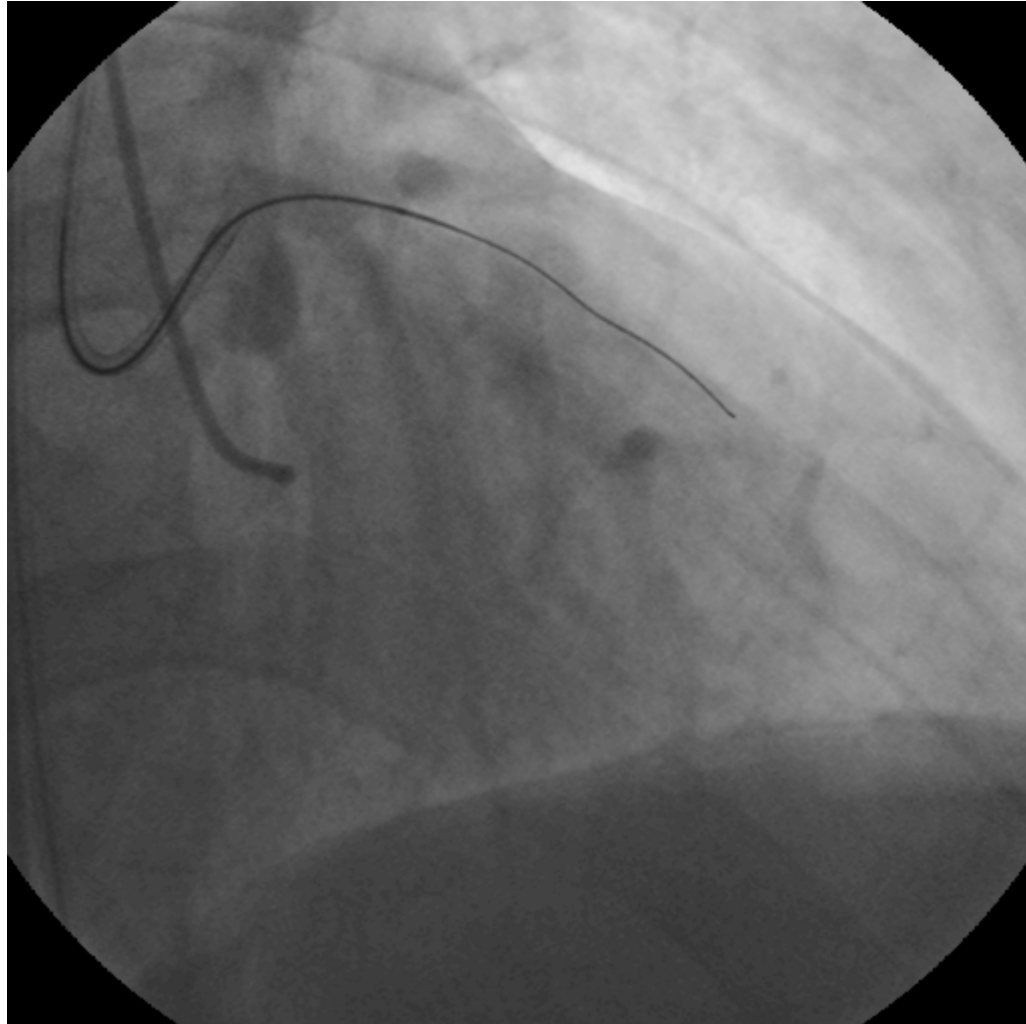


Rinato

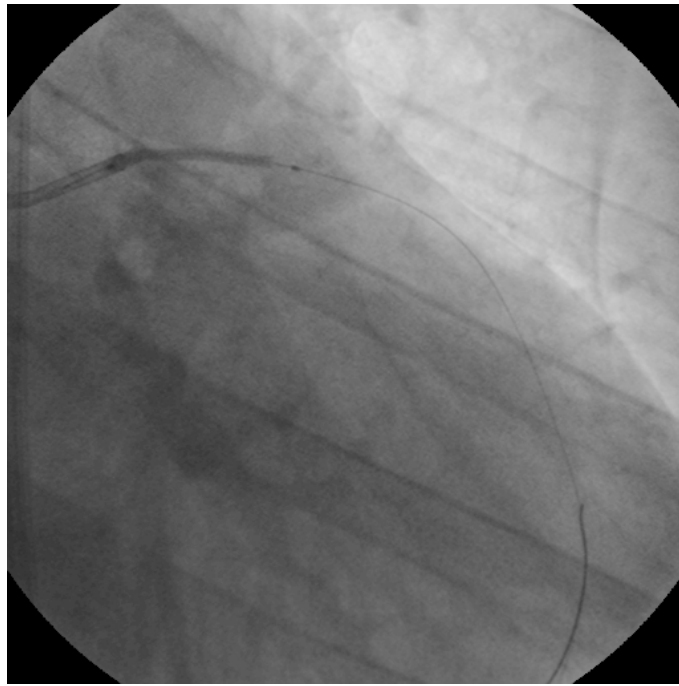
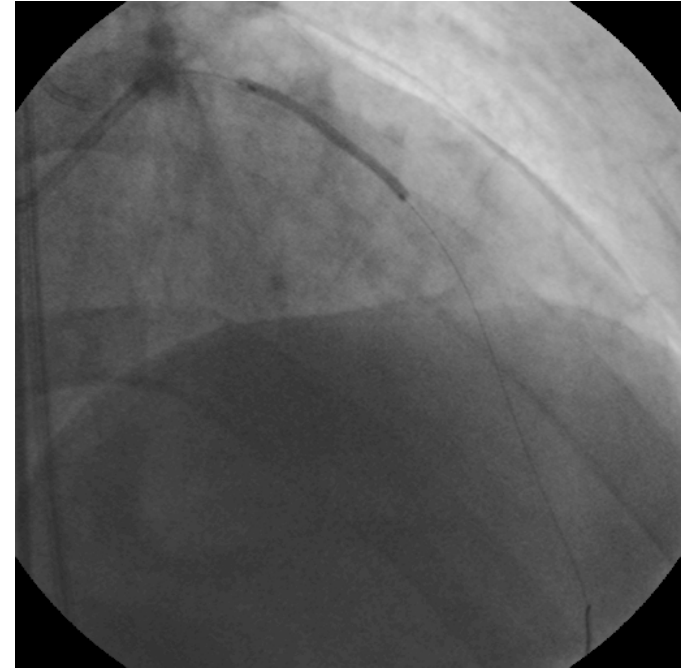
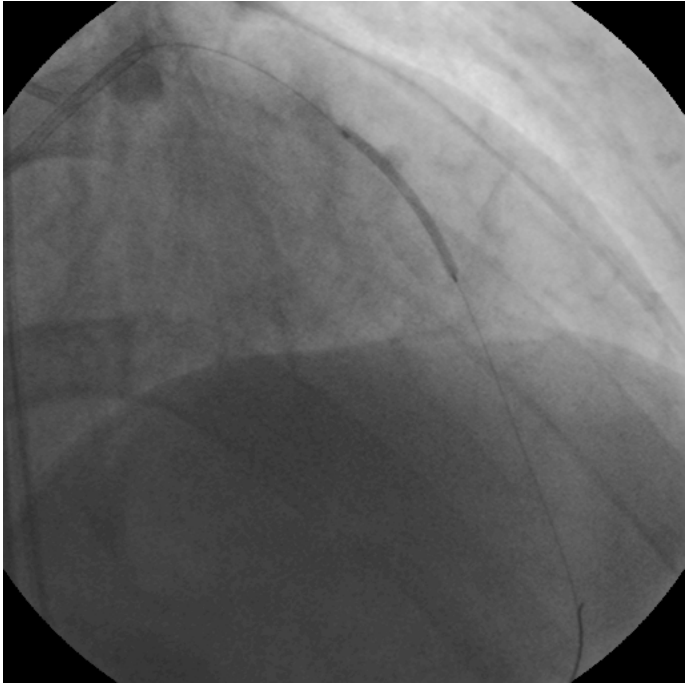


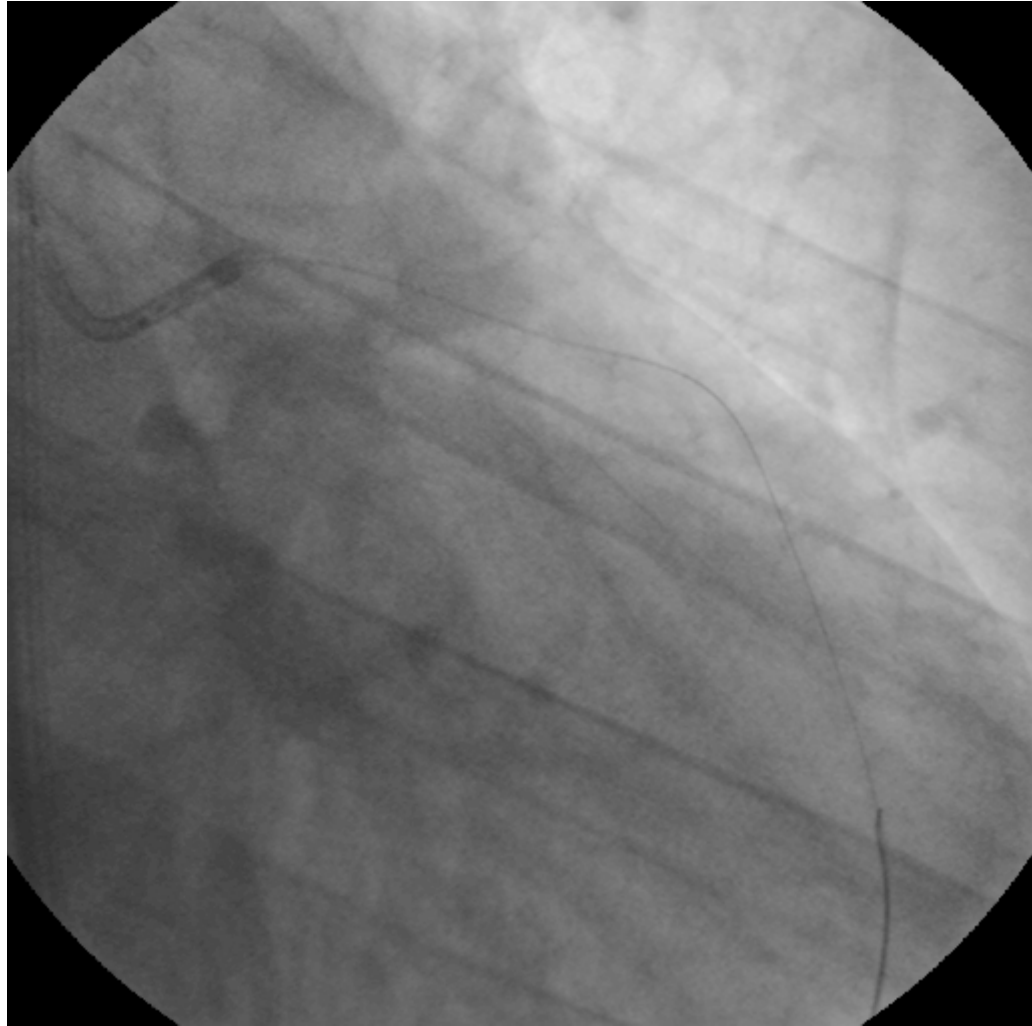Miracle 4.5

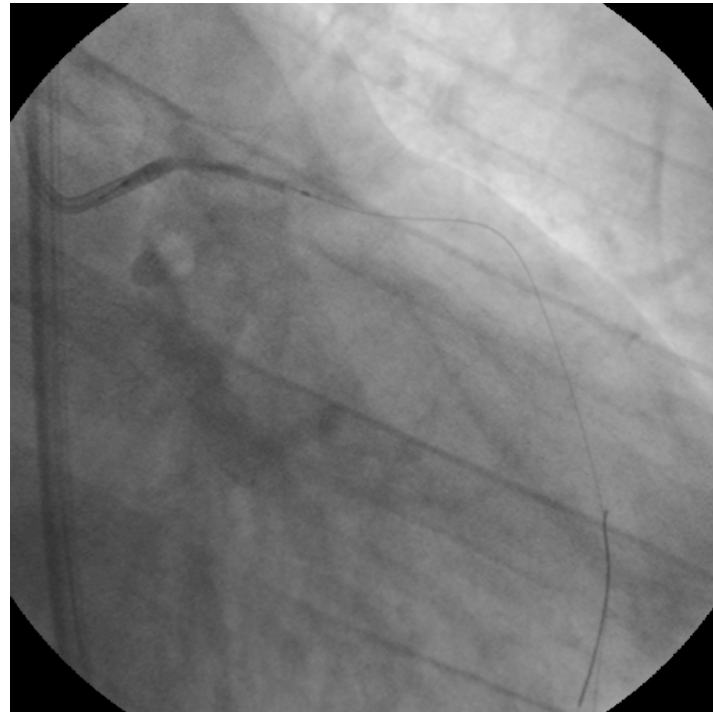
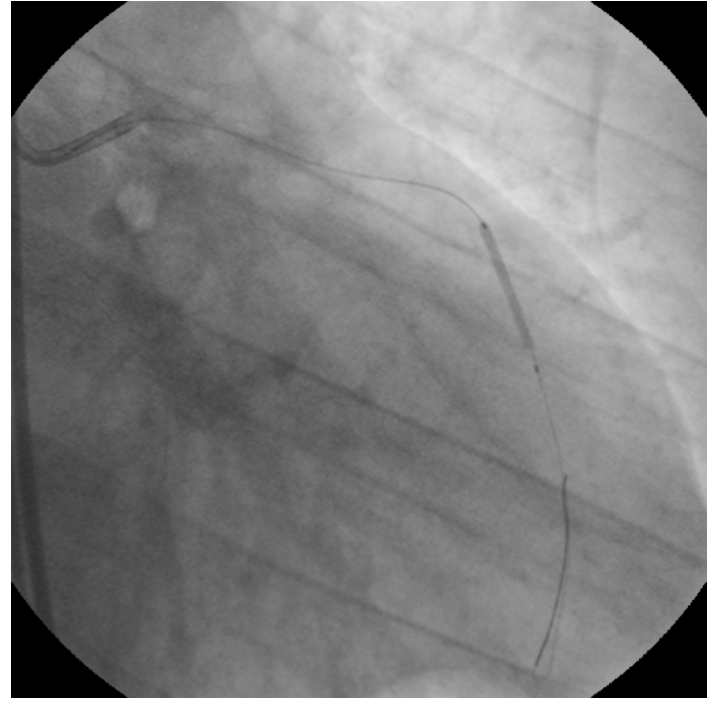
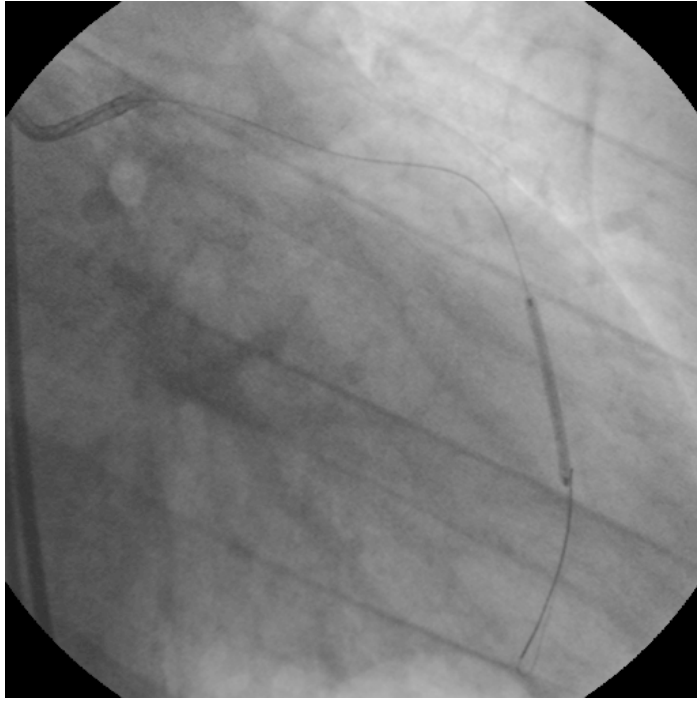




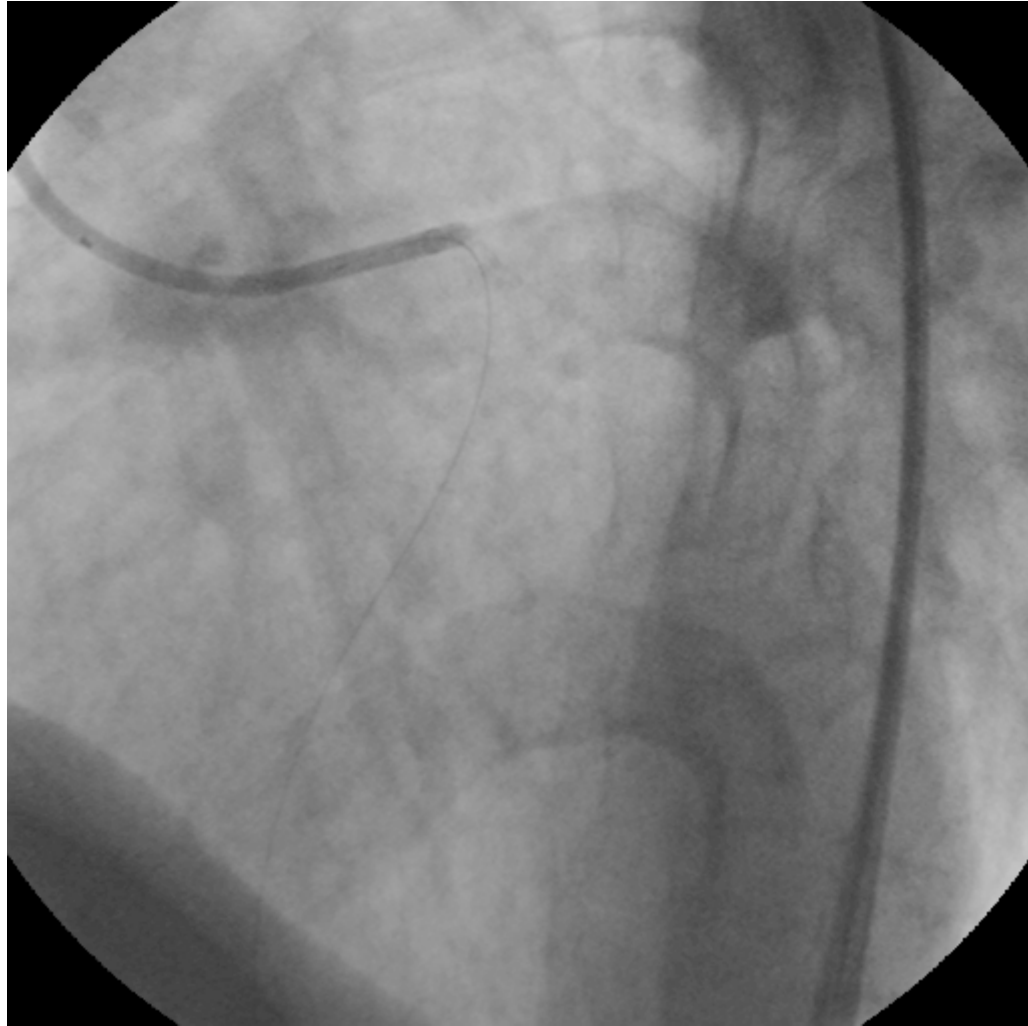
Miracle 4.5

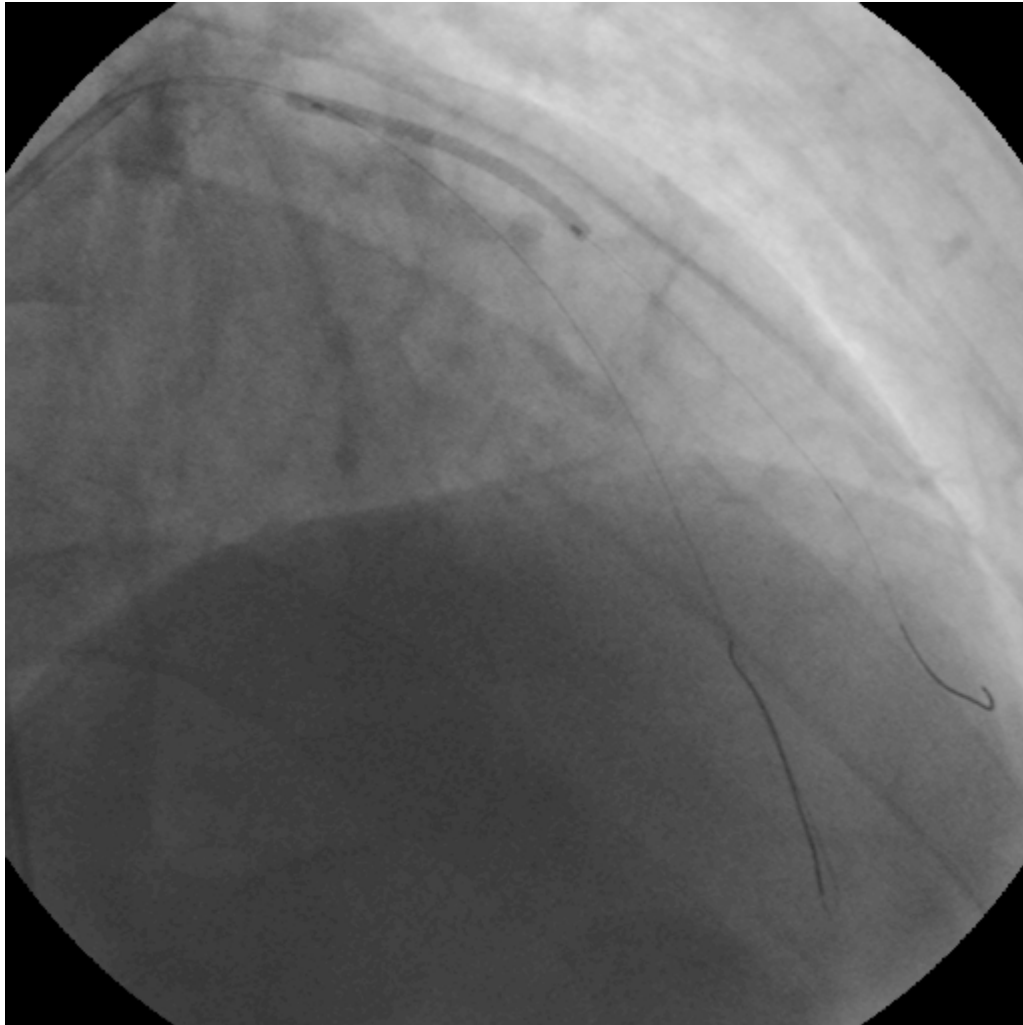




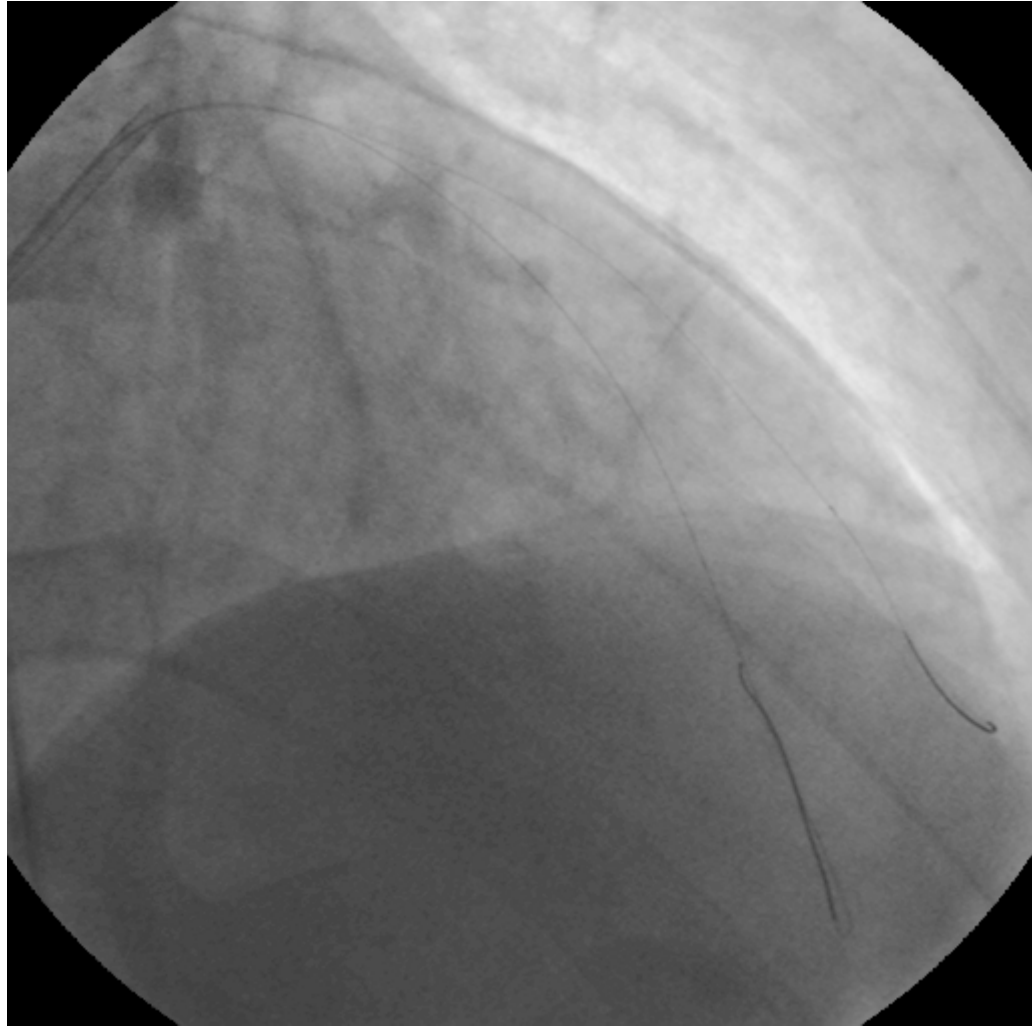


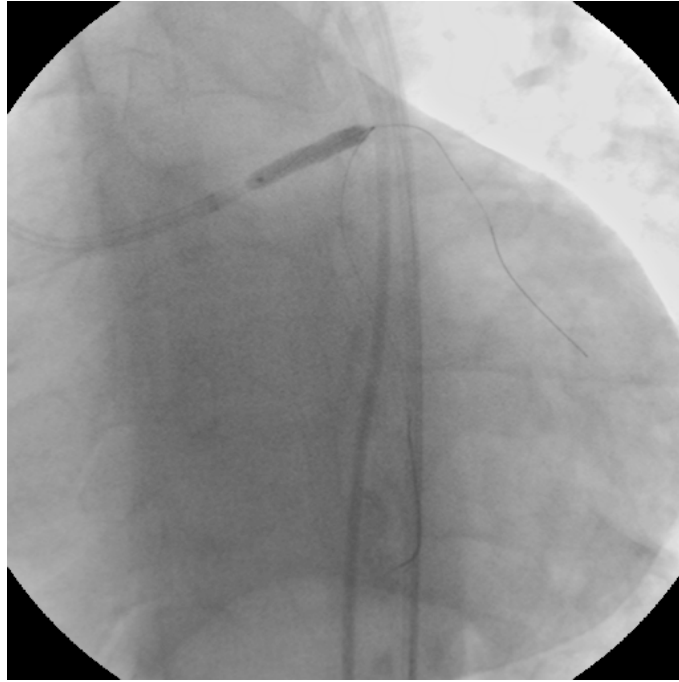
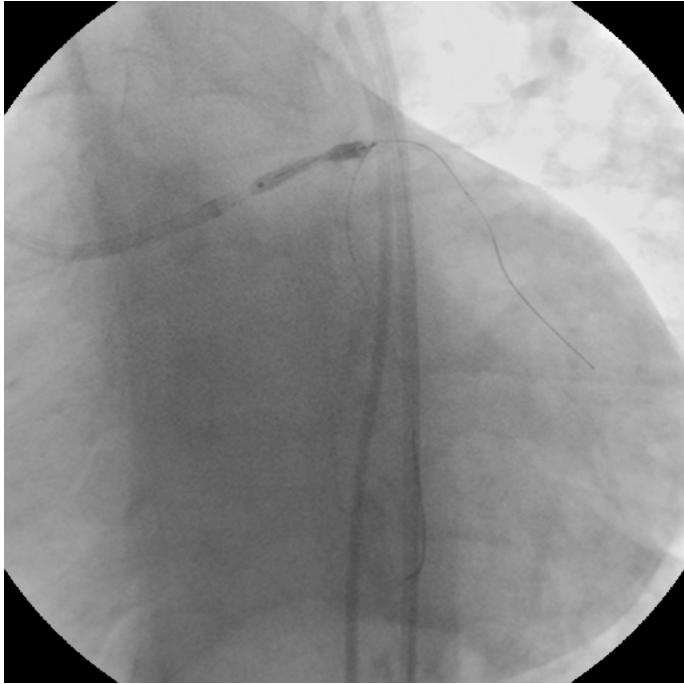
LAD'ye balon
2.0X30 mm



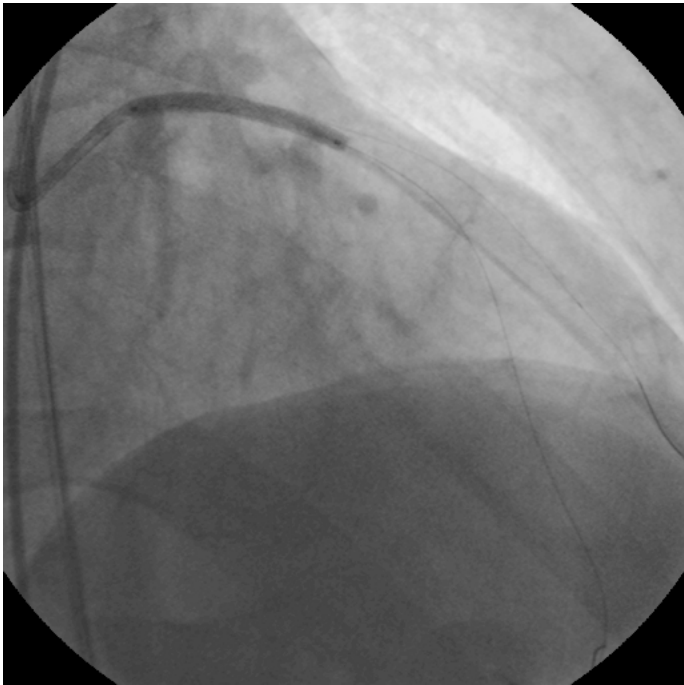


Diagonal'e balon
2.0x30 mm

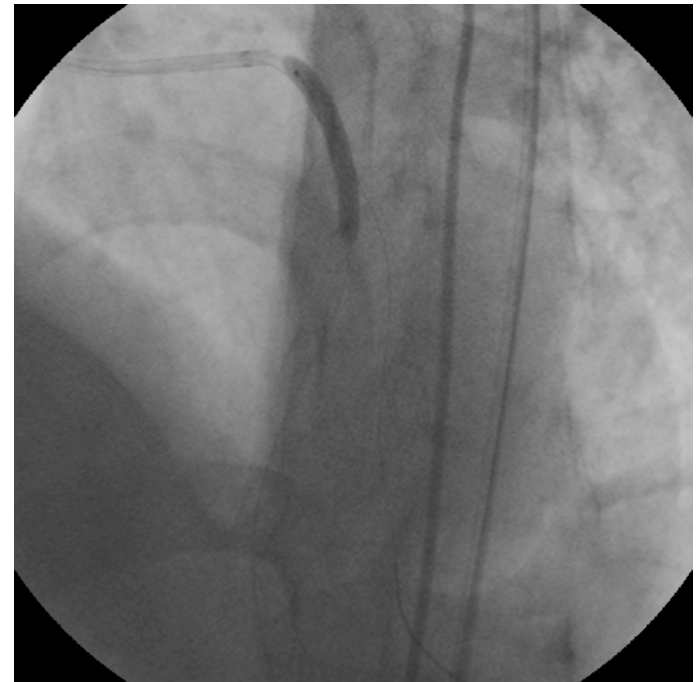




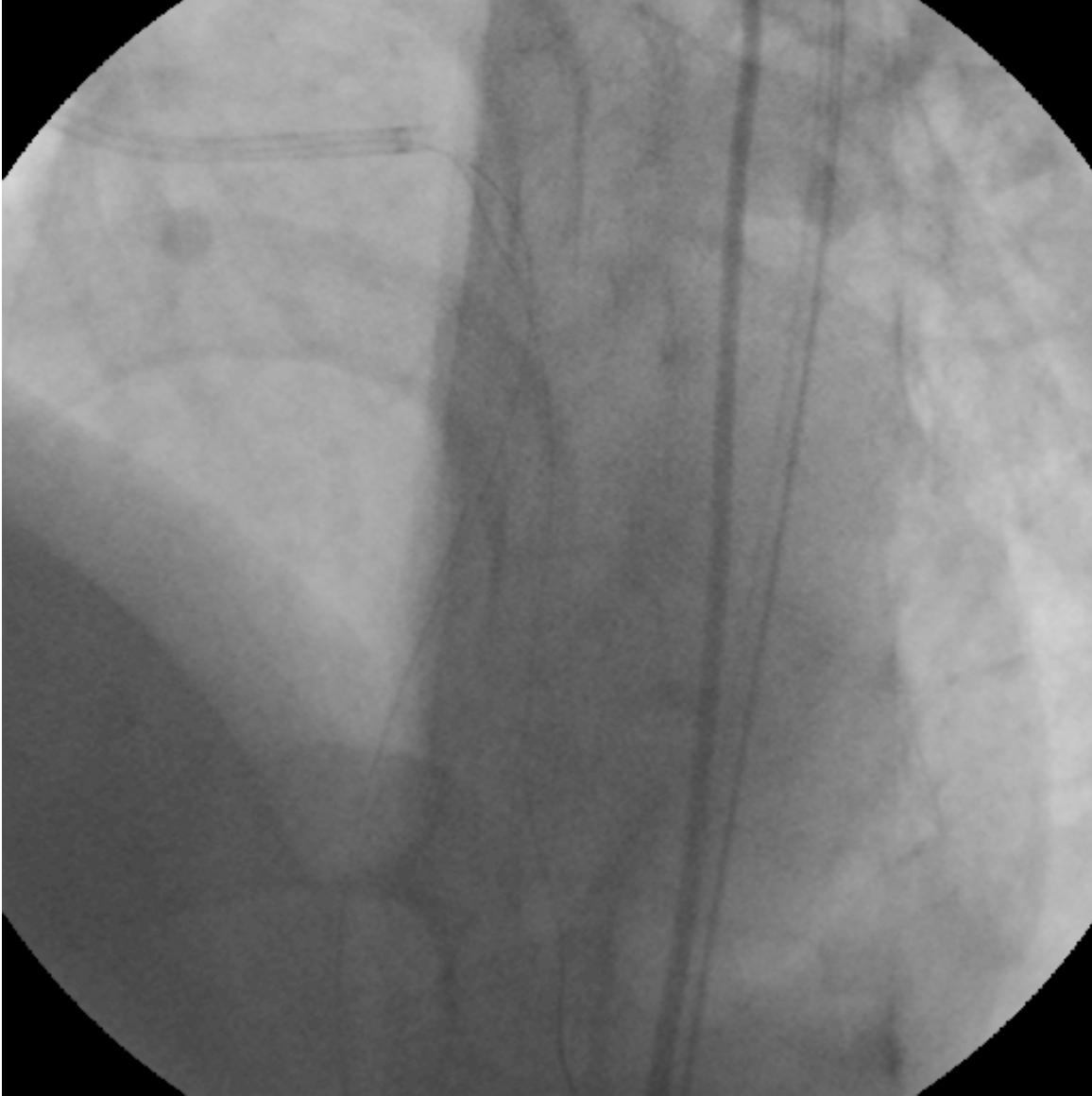
LAD'ye stent
2.75x30 mm
Endeavor



postdilatasyon



Sonuç



Diagonal ince, TIMI III akım
mevcut, stent düşünülmedi

Total opak miktarı 600 cc