

Kronik total oklüzyonda retrograd yaklaşım



DOÇ.DR. MUHSİN TÜRKMEN
UZM.DR. VEFİK YAZICIOĞLU
UZM.DR.MÜSLÜM ŞAHİN

Vaka-2

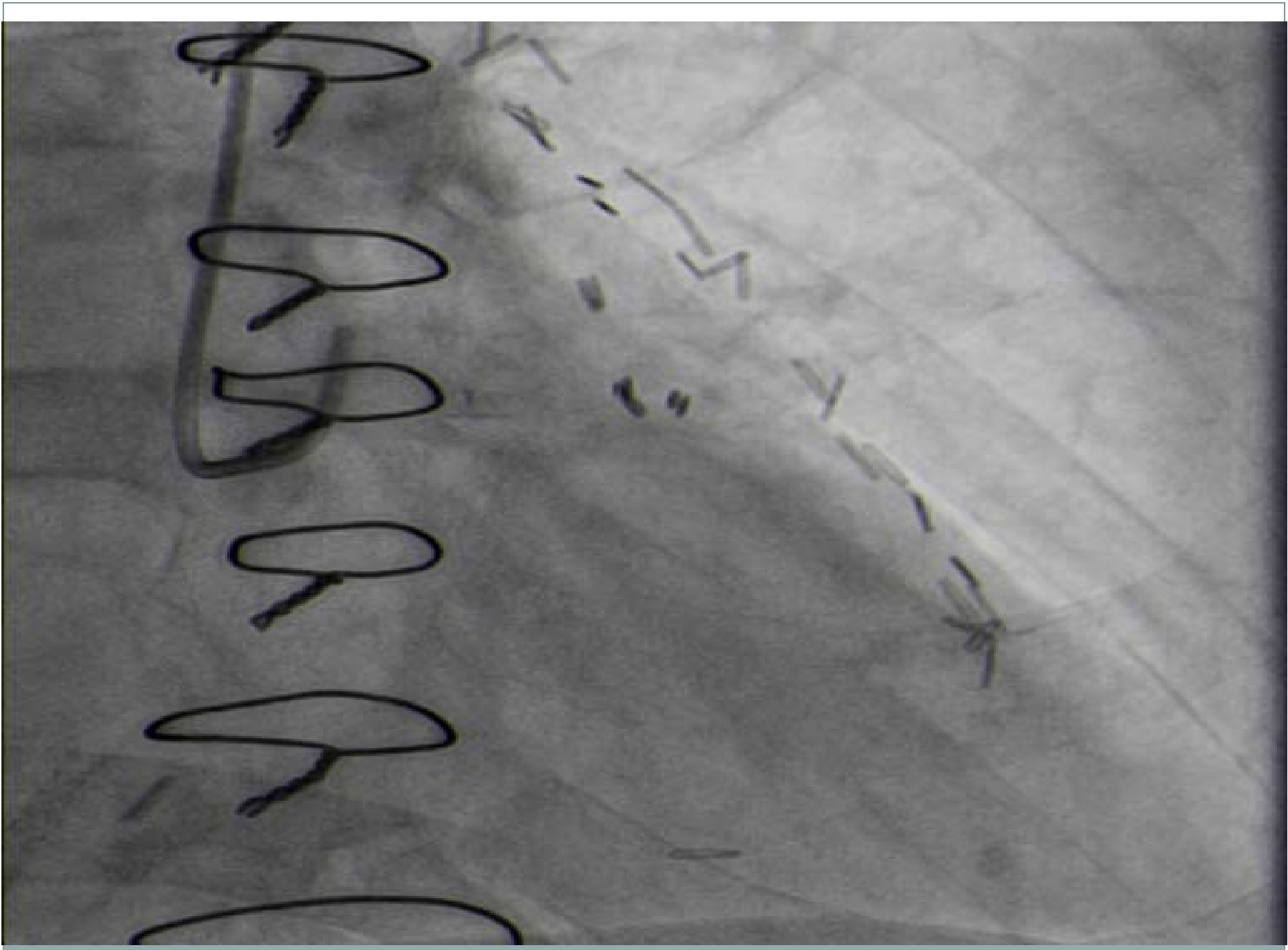


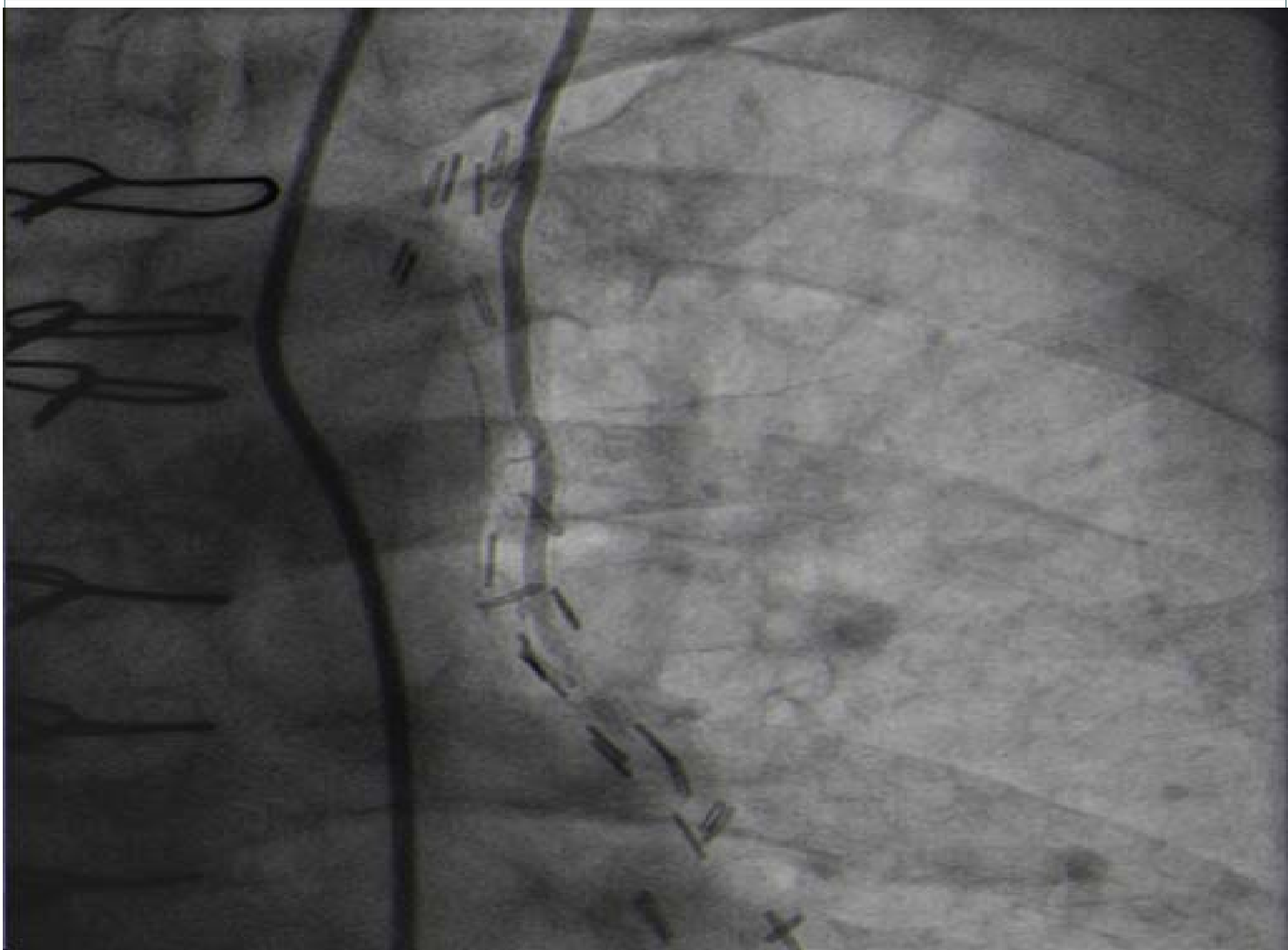
- 65 yaşında erkek hasta
- Son 4 aydır class-II dispne
- 2008 de RCA ve Cx'e stent implantasyonu, 2010 da CABGx3(Lima-LAD, Ao-Cx, Ao-RCA) uygulanmış.
- HT(+), HL(+), DM(-), Sigara(-)

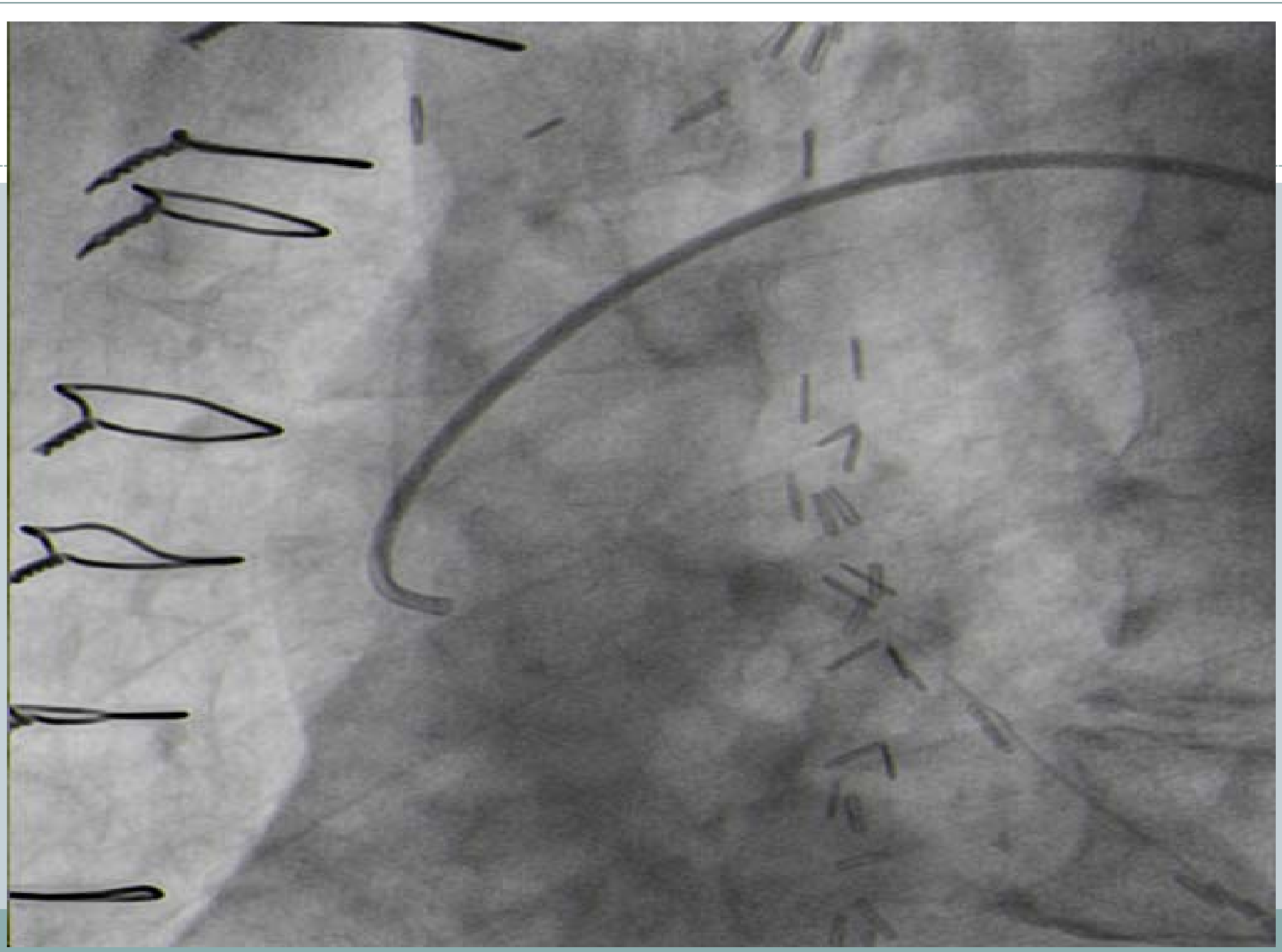
Vaka-2

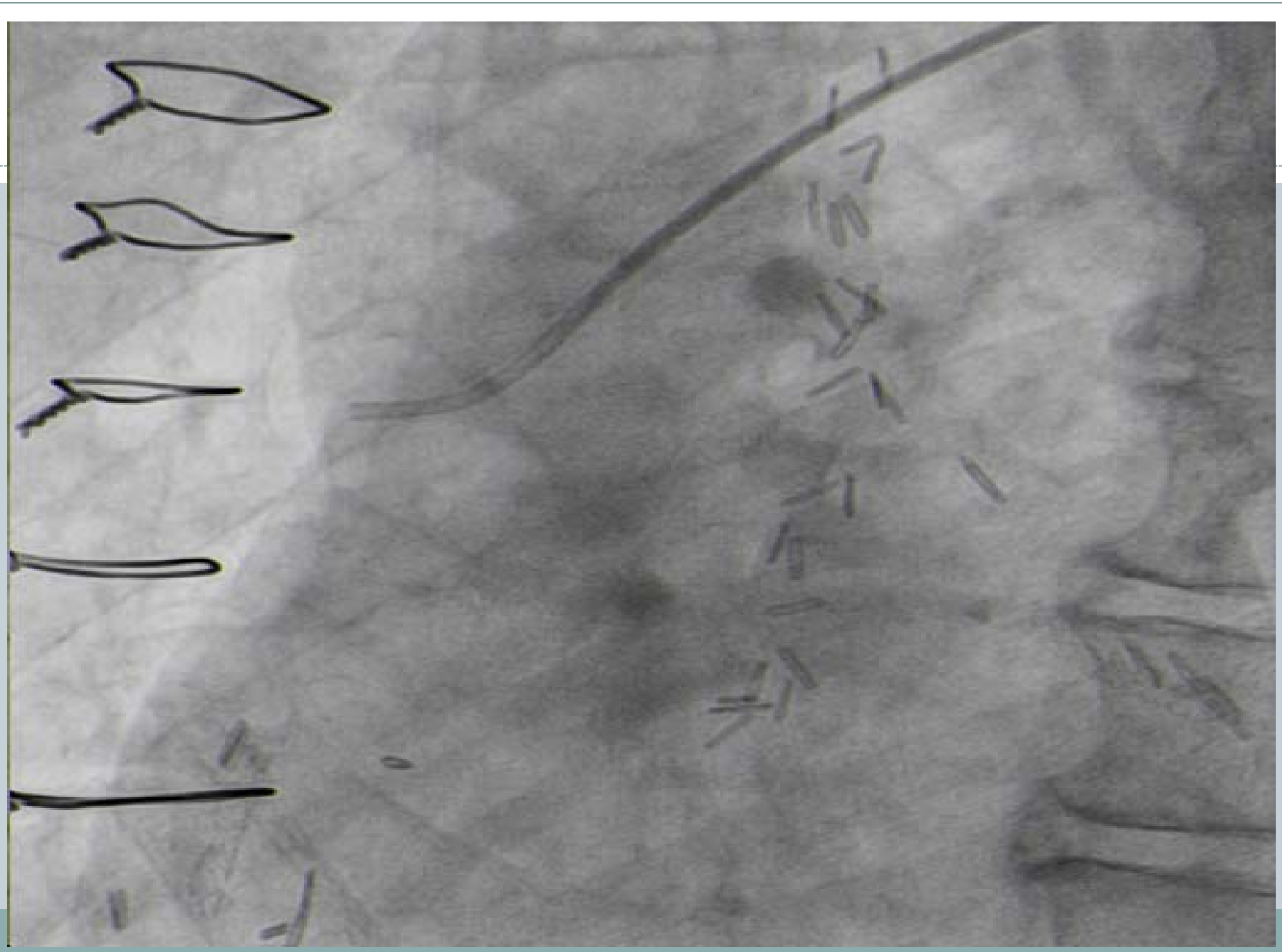


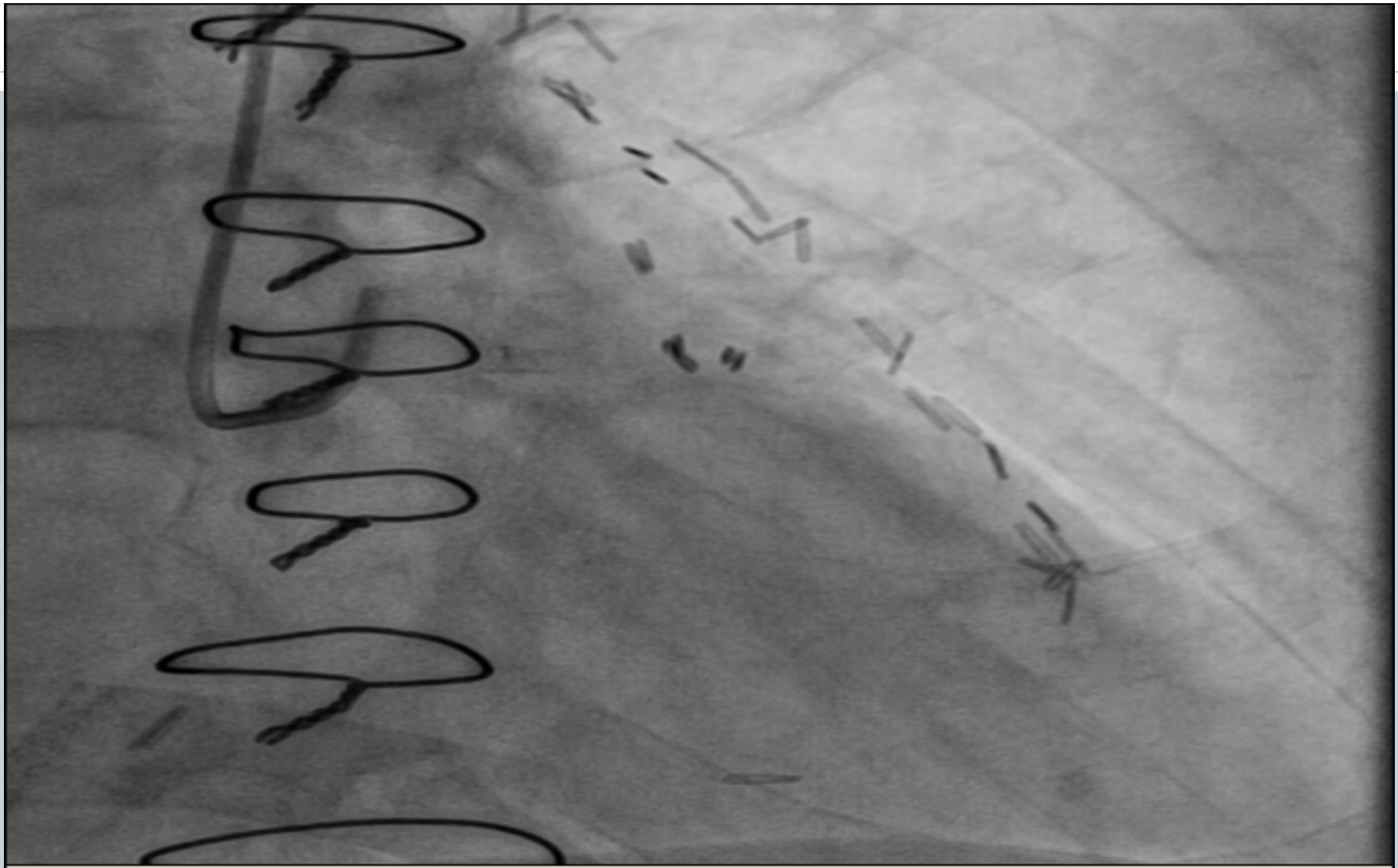
- EKO: LVEF:%45, hafif MY, LVDD
- MPS: inferior duvarda periinfarkt iskemi
- Wbc: 3.5, hgb: 13.4, plt: 135, üre: 23, kre: 0.79 ldl: 41
- ASA, metoprolol, statin



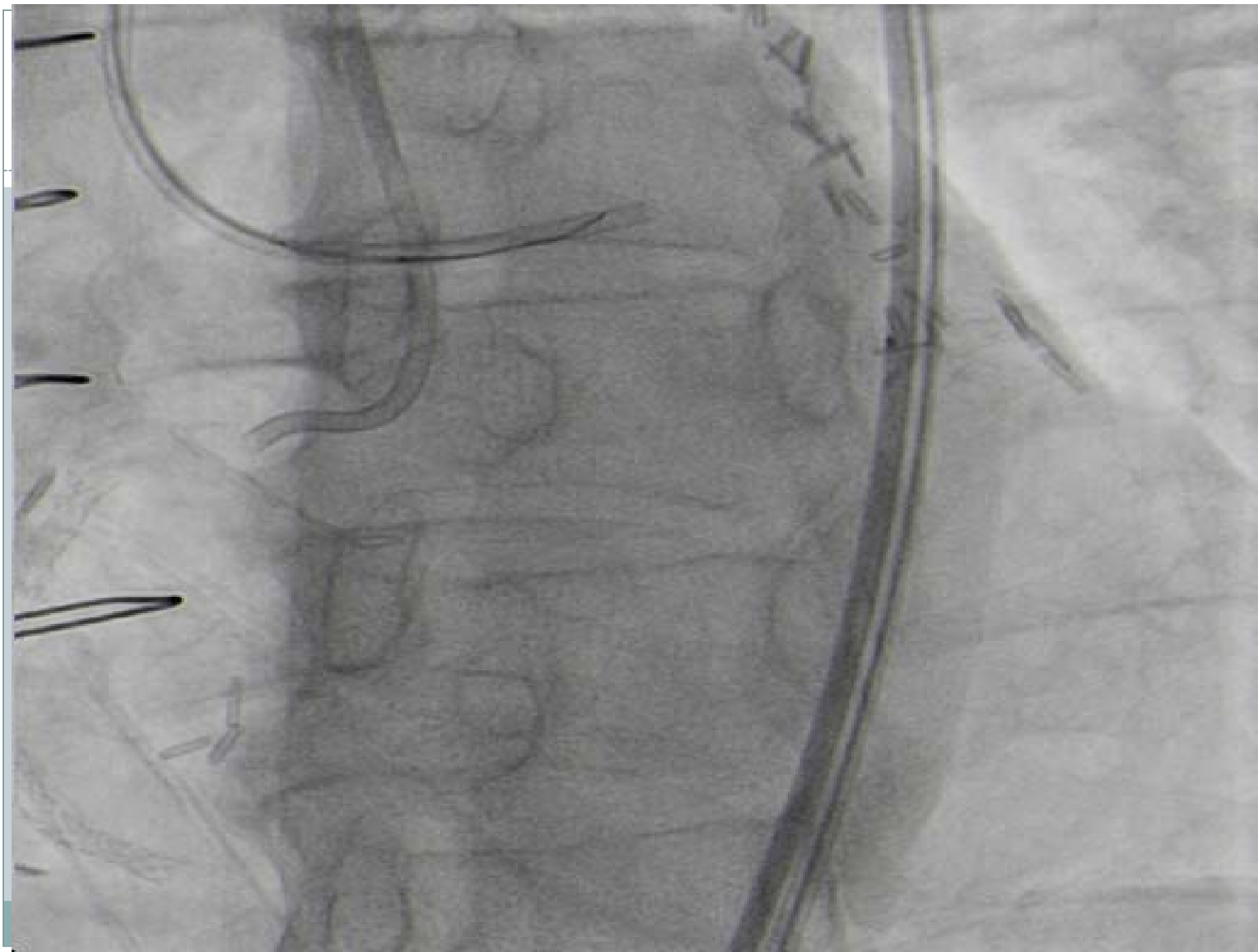

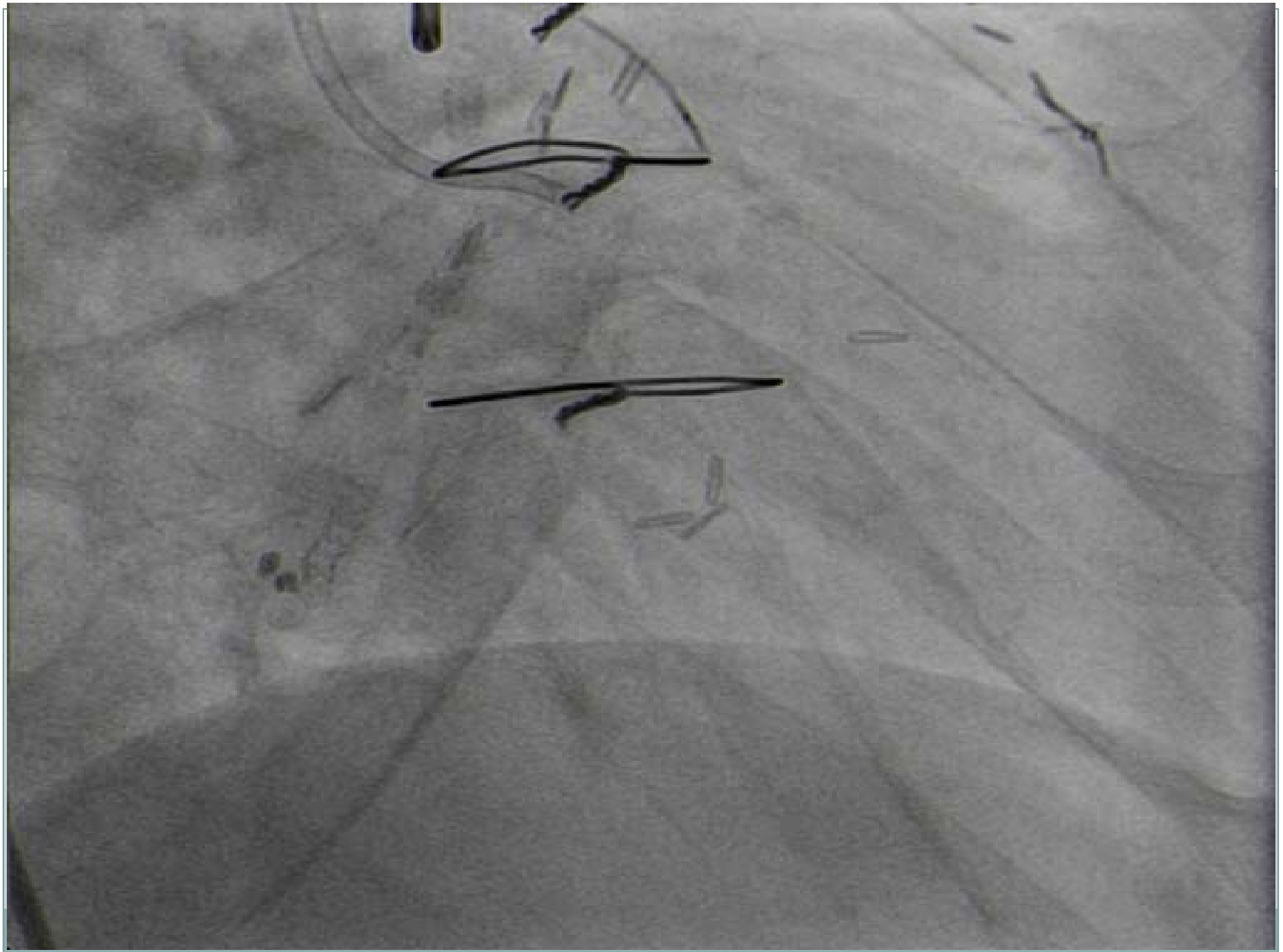



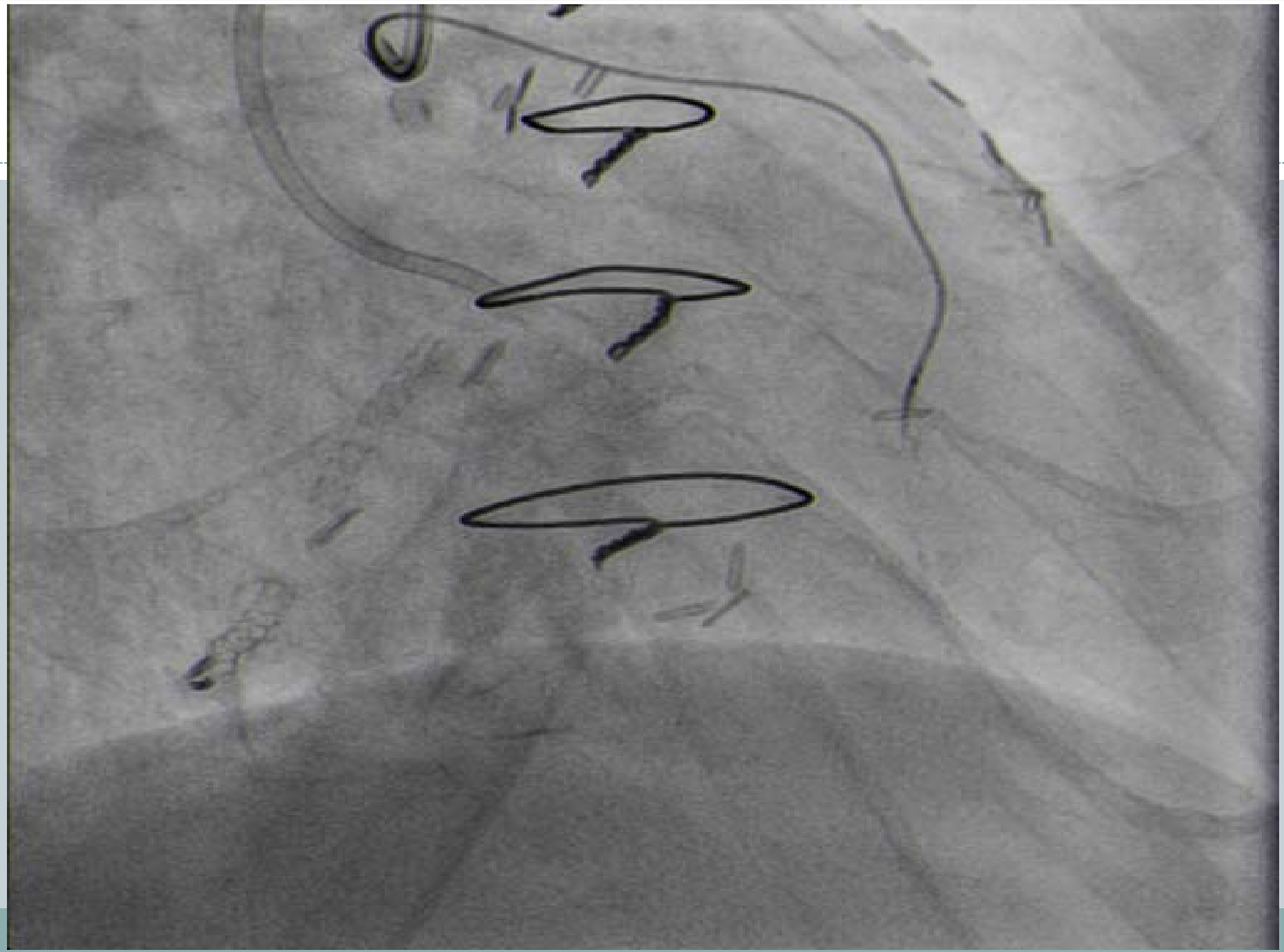
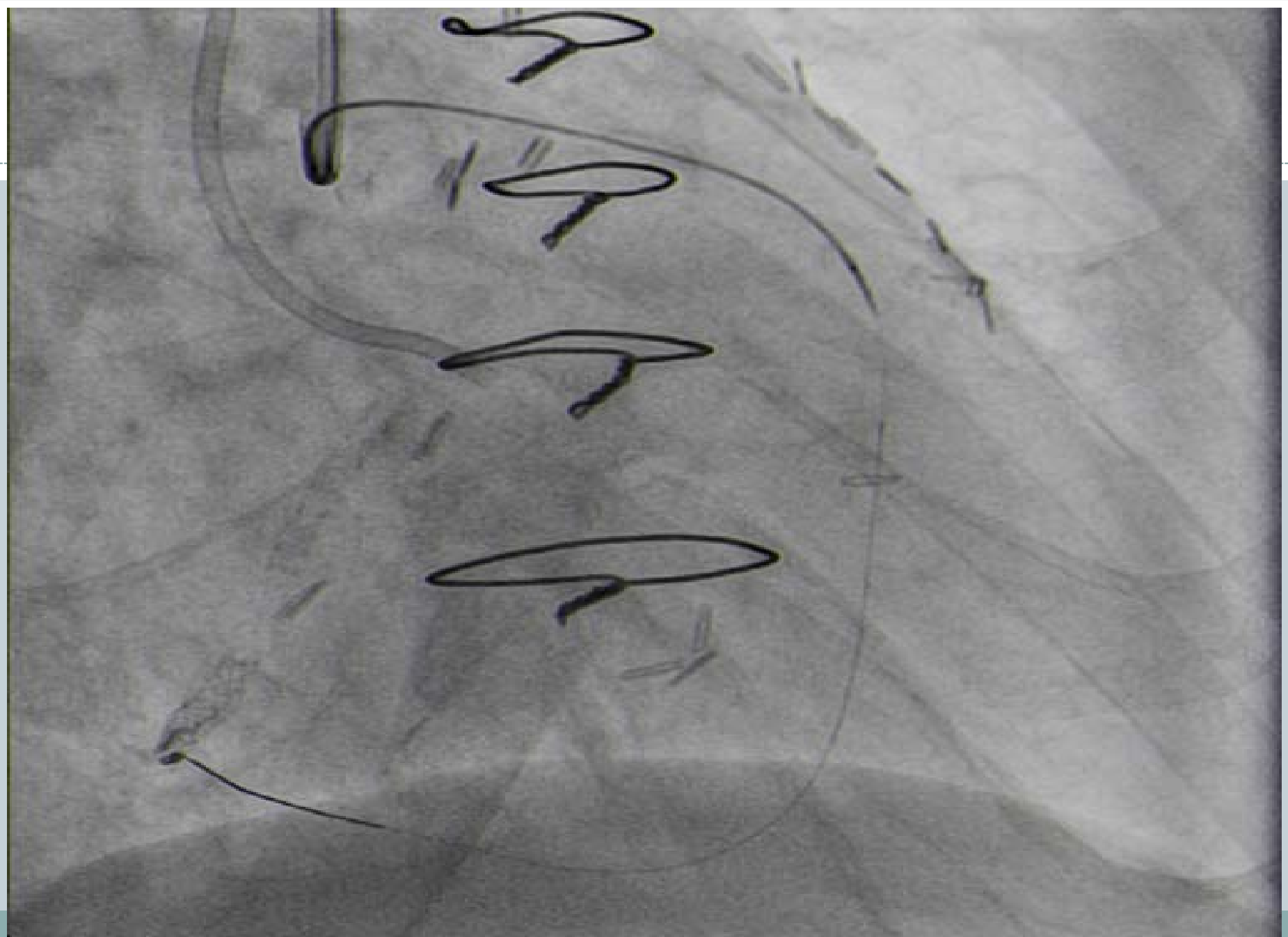


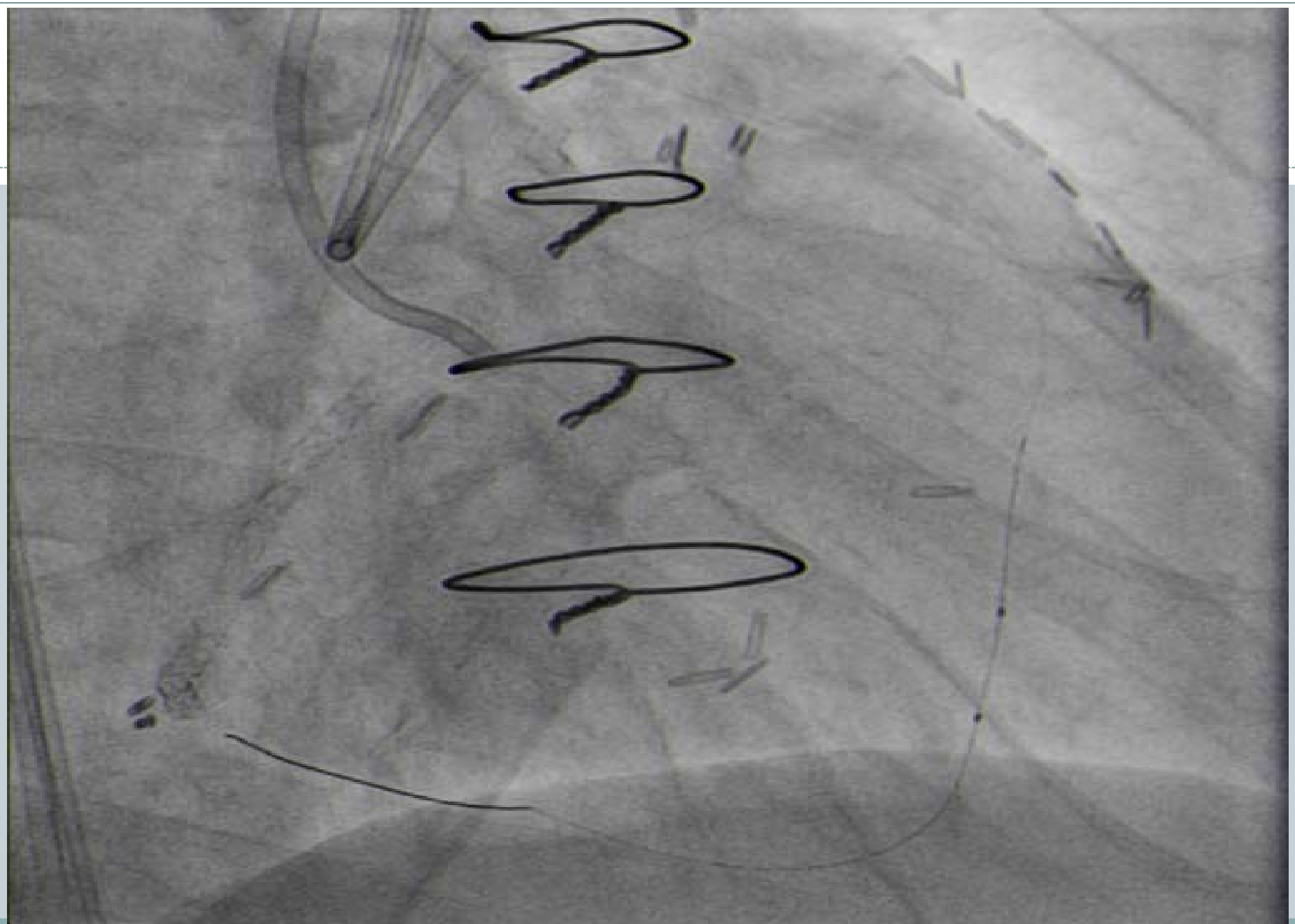
anjio14-3-42

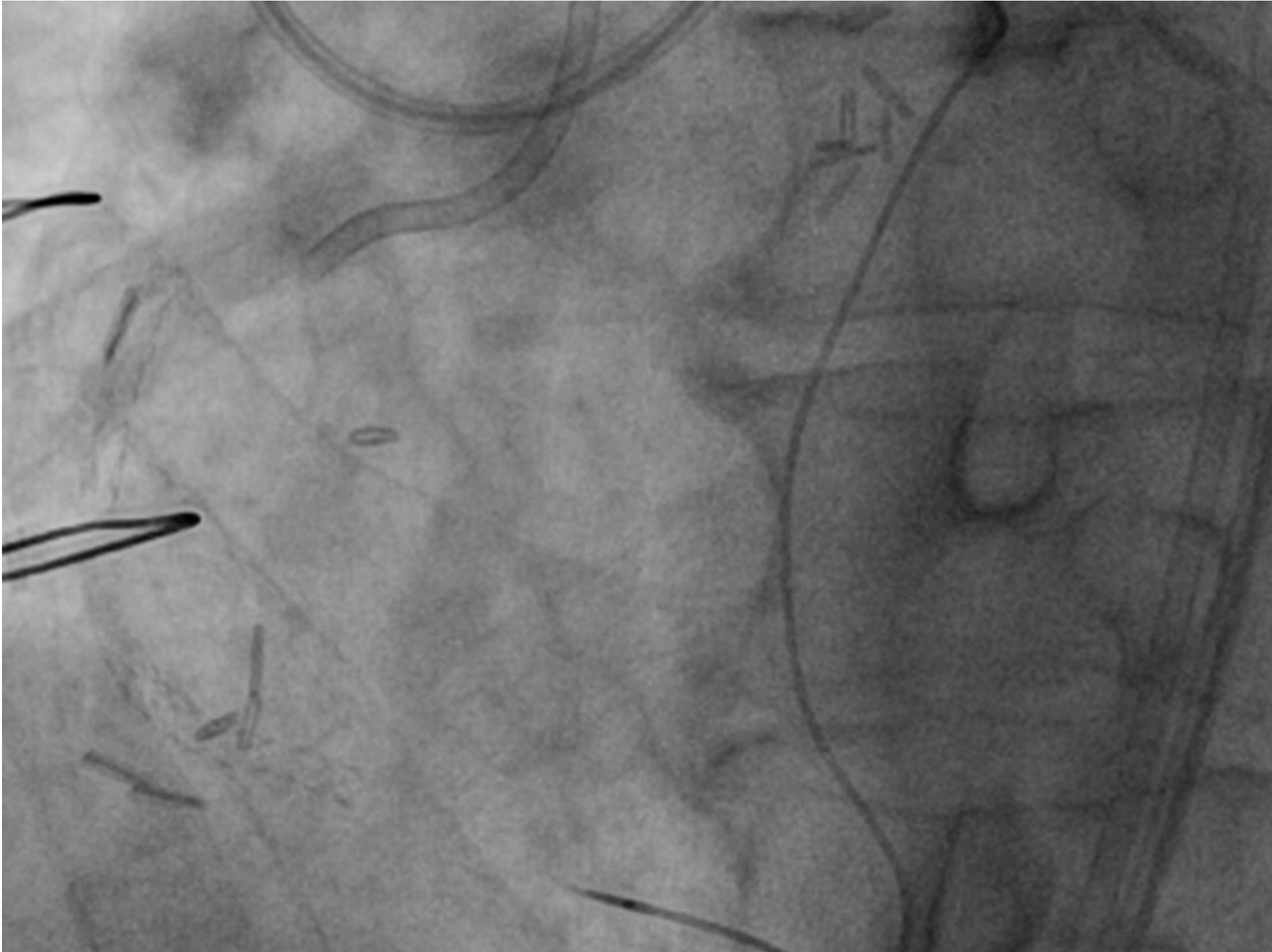

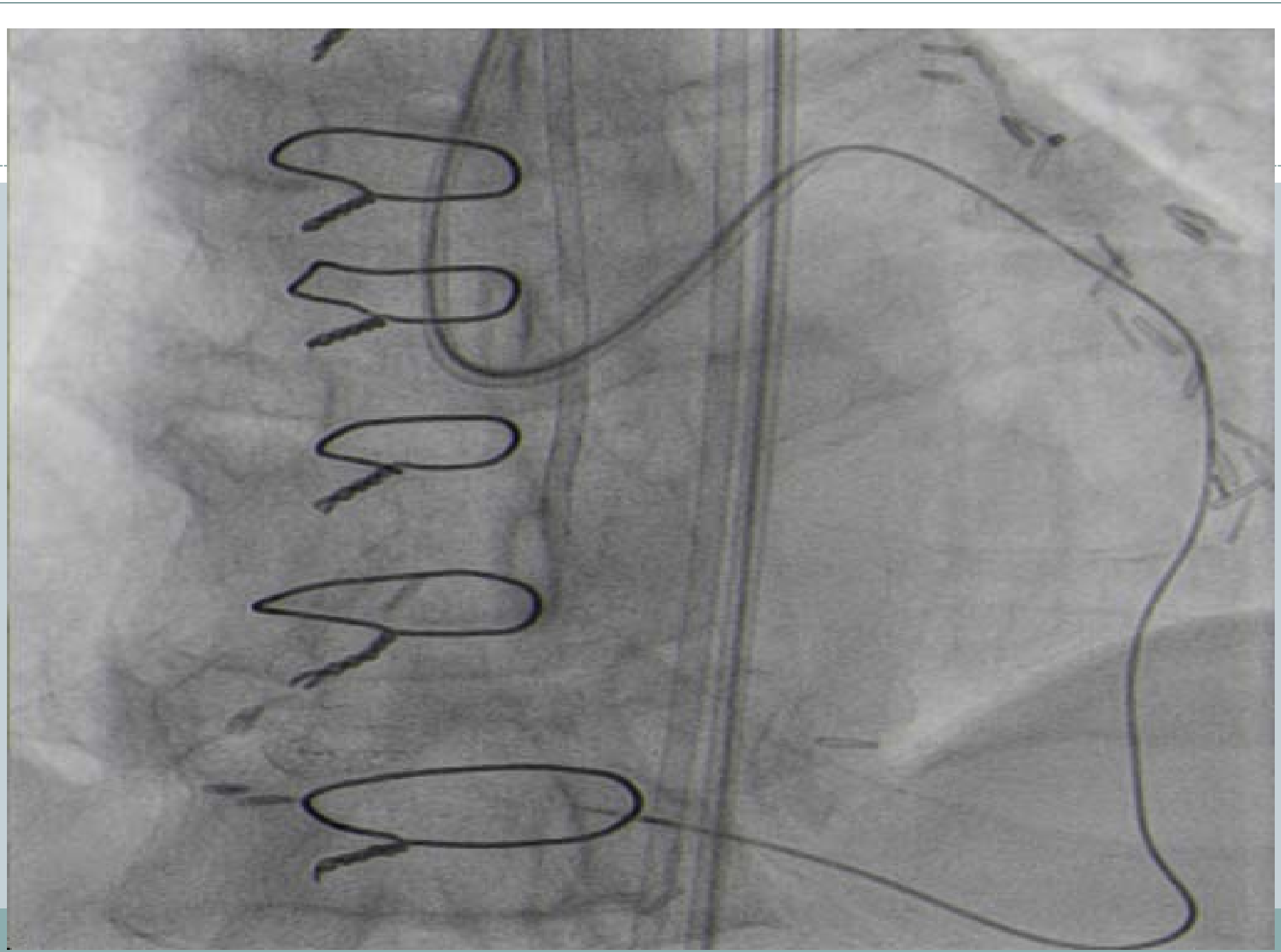


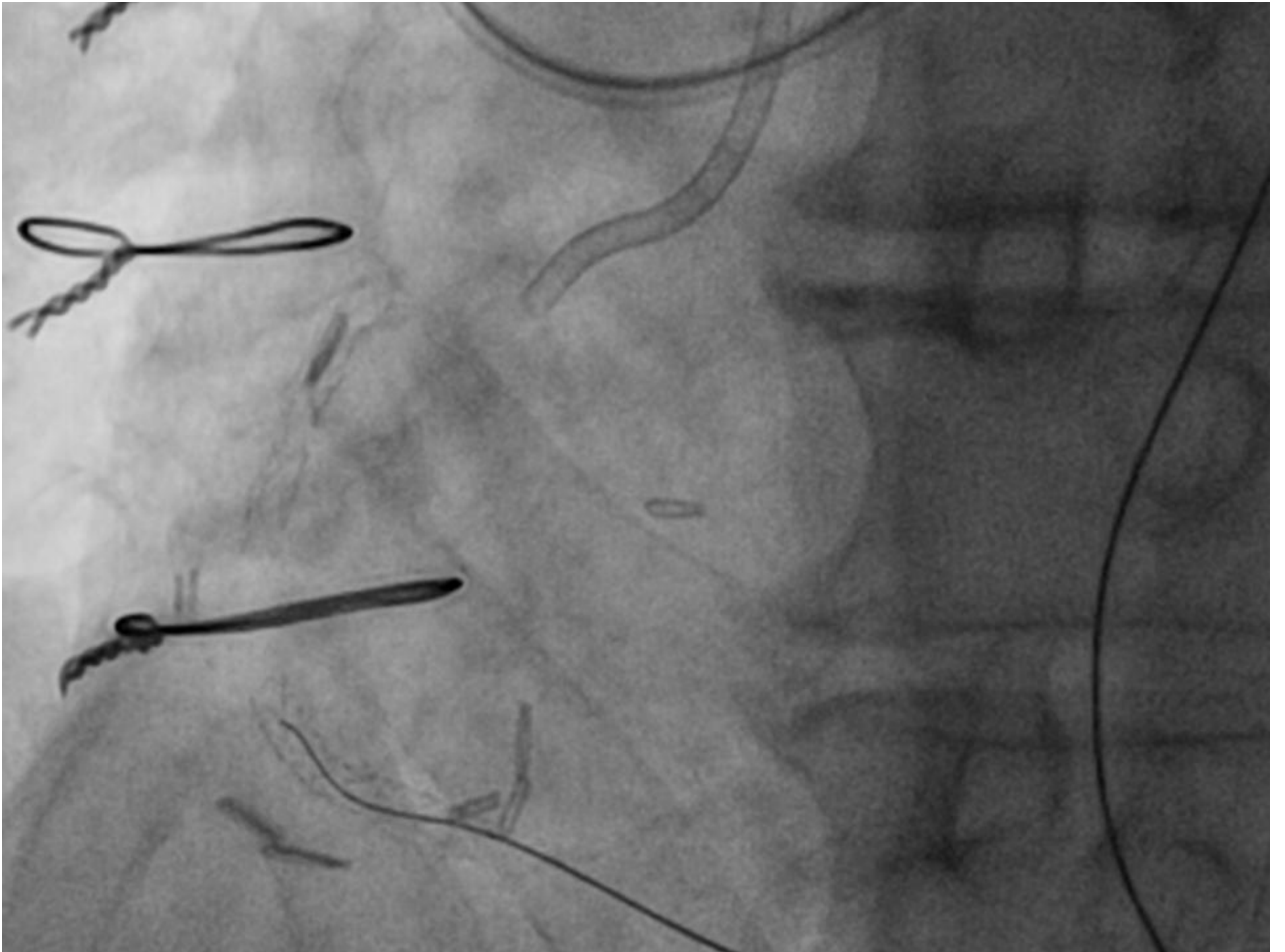


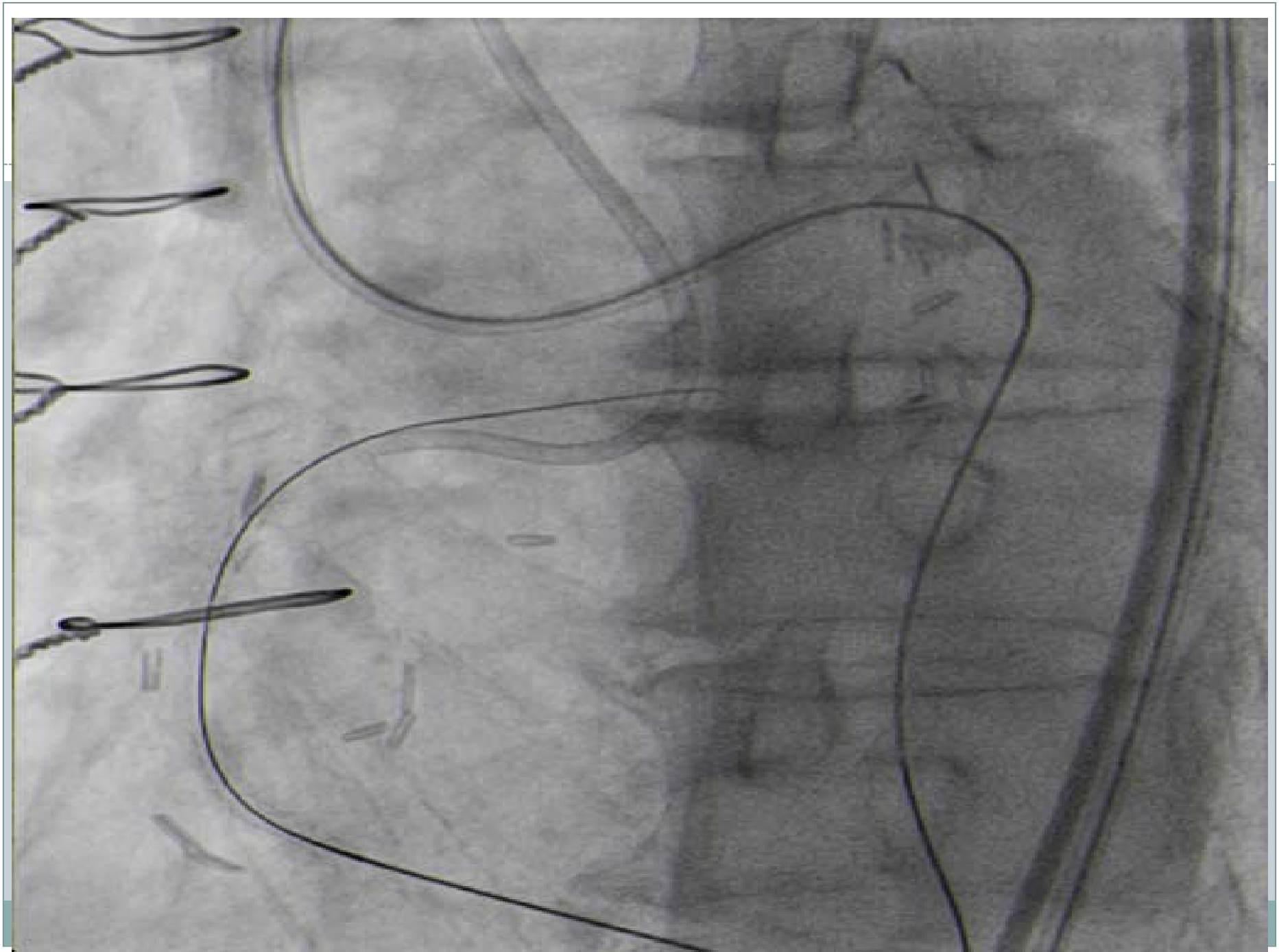


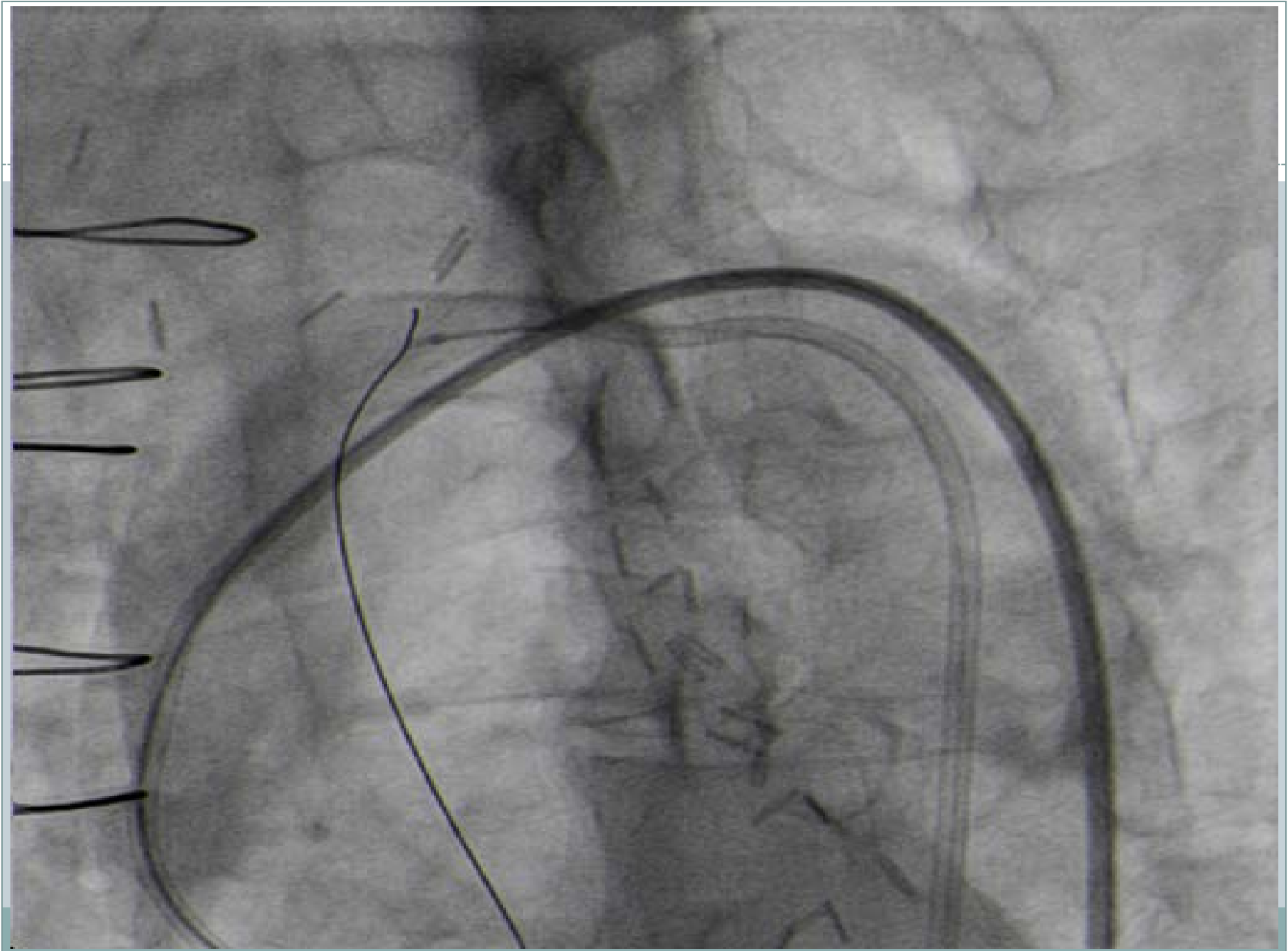


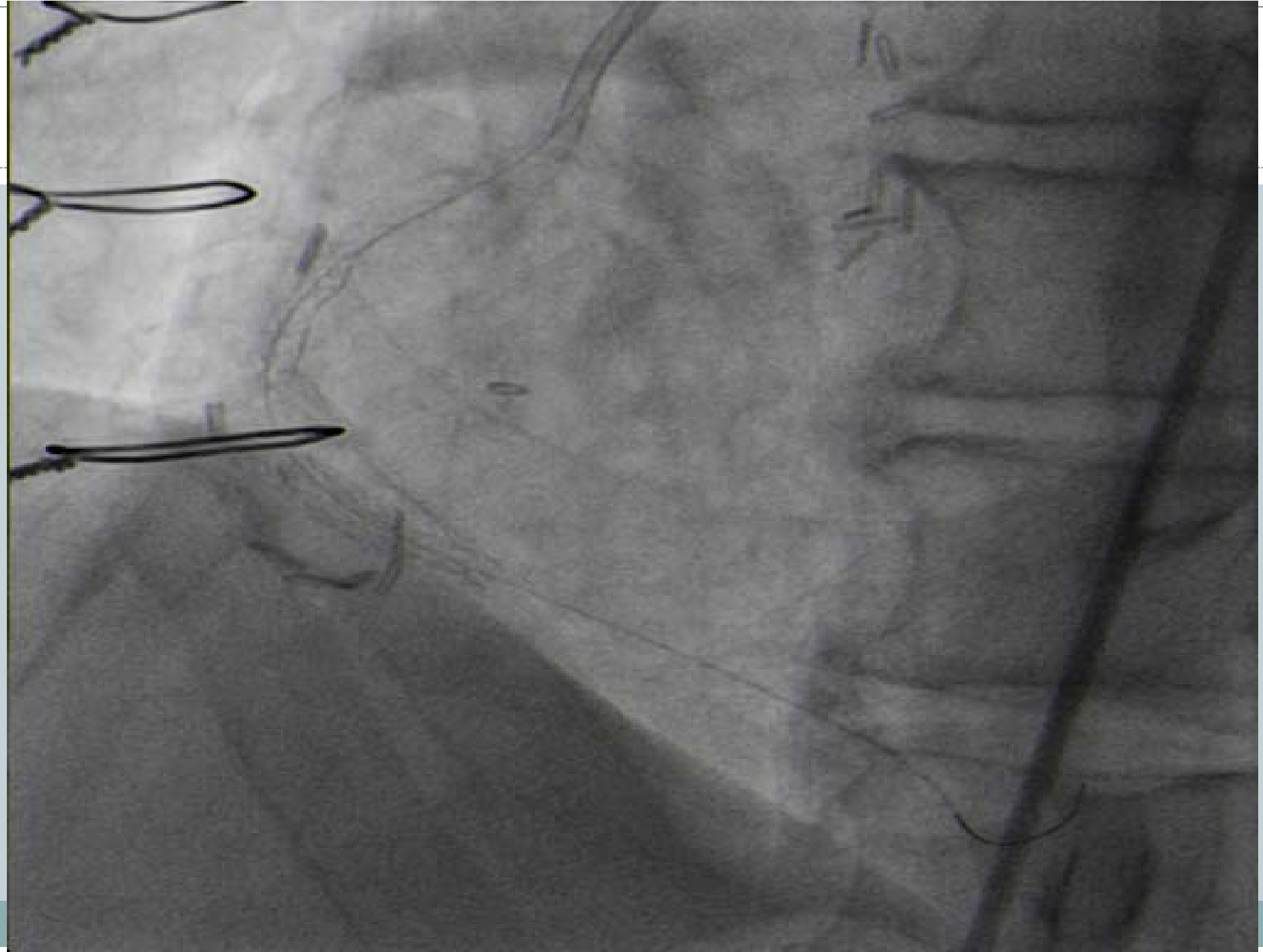


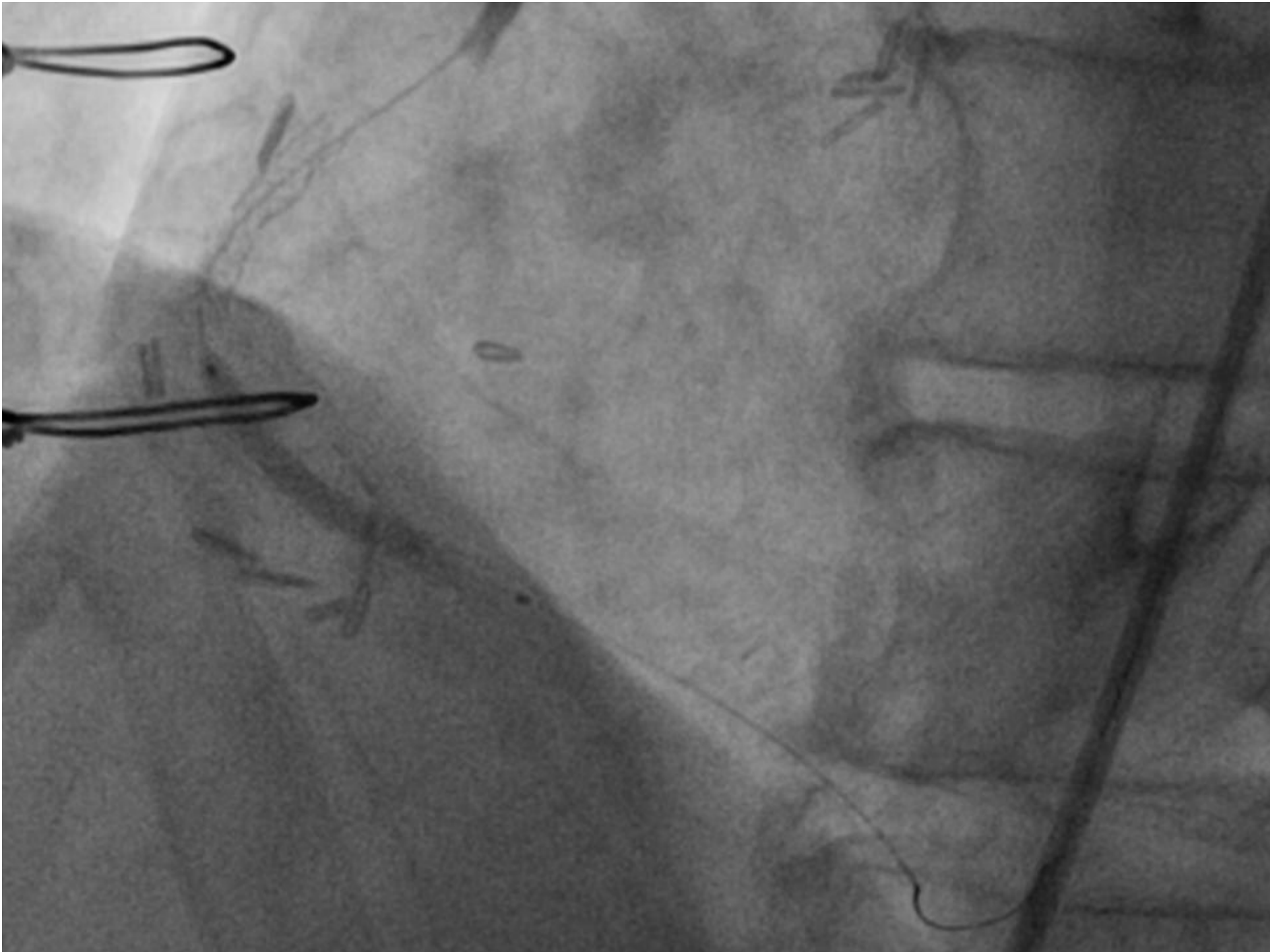


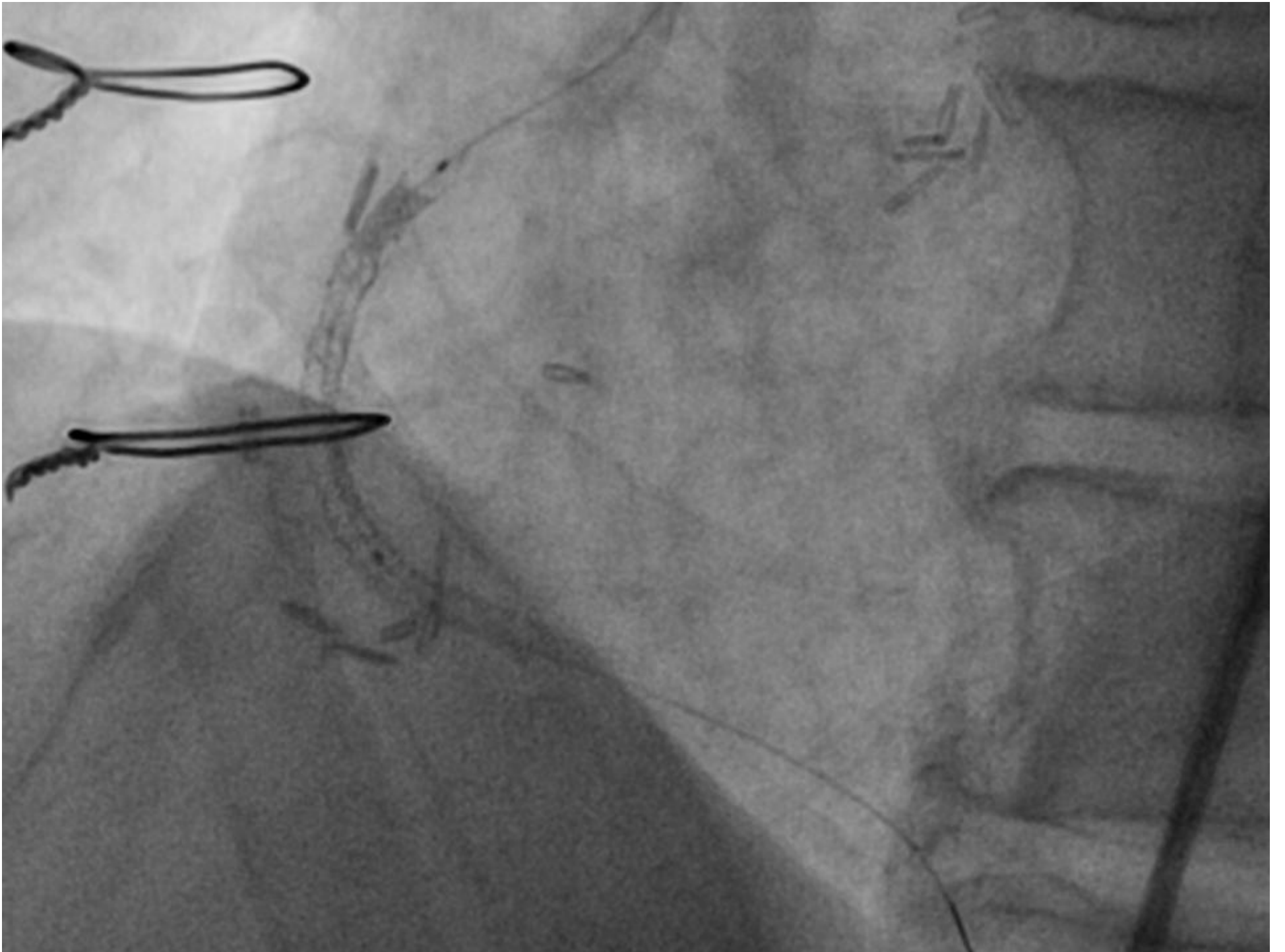


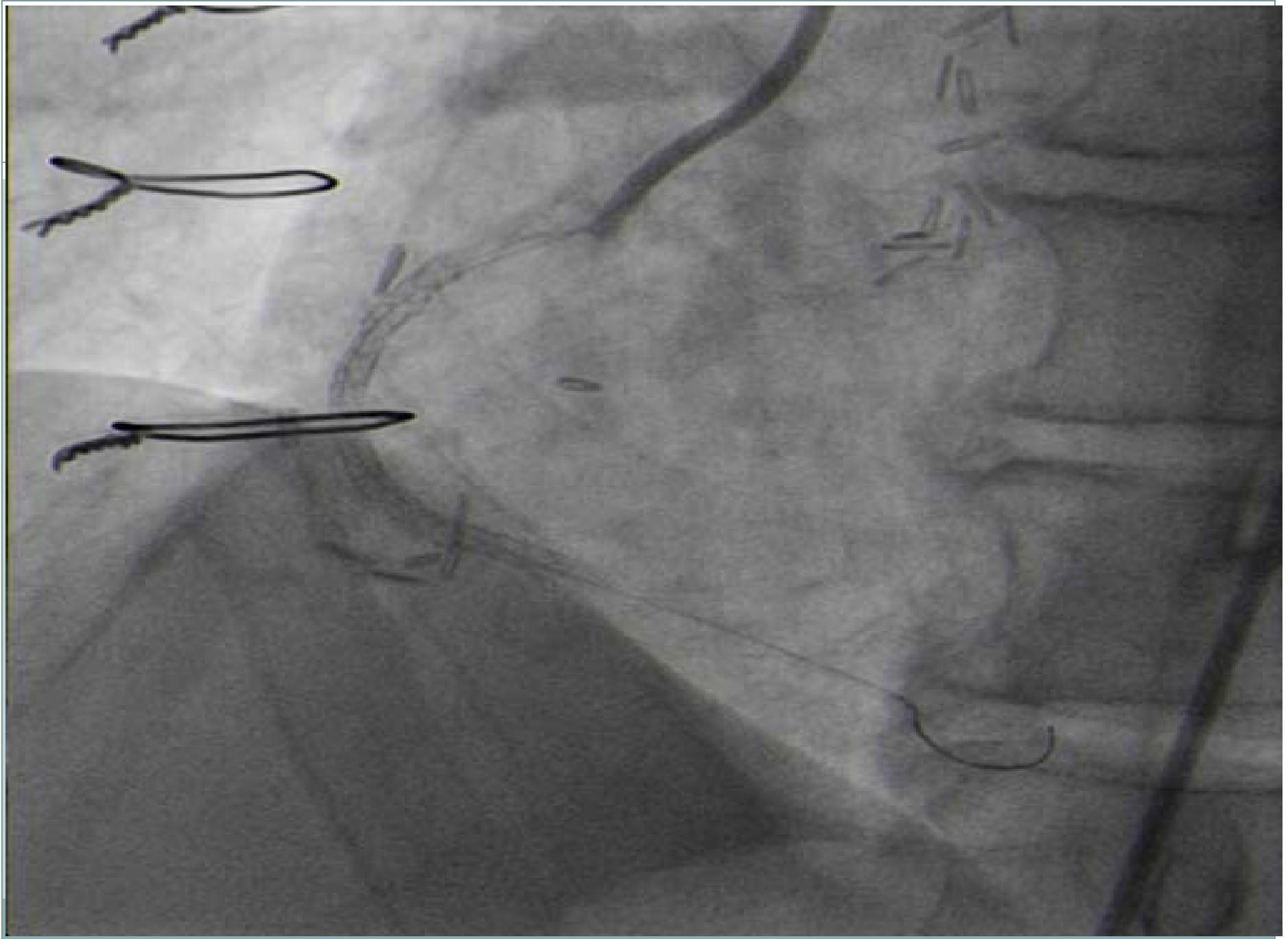


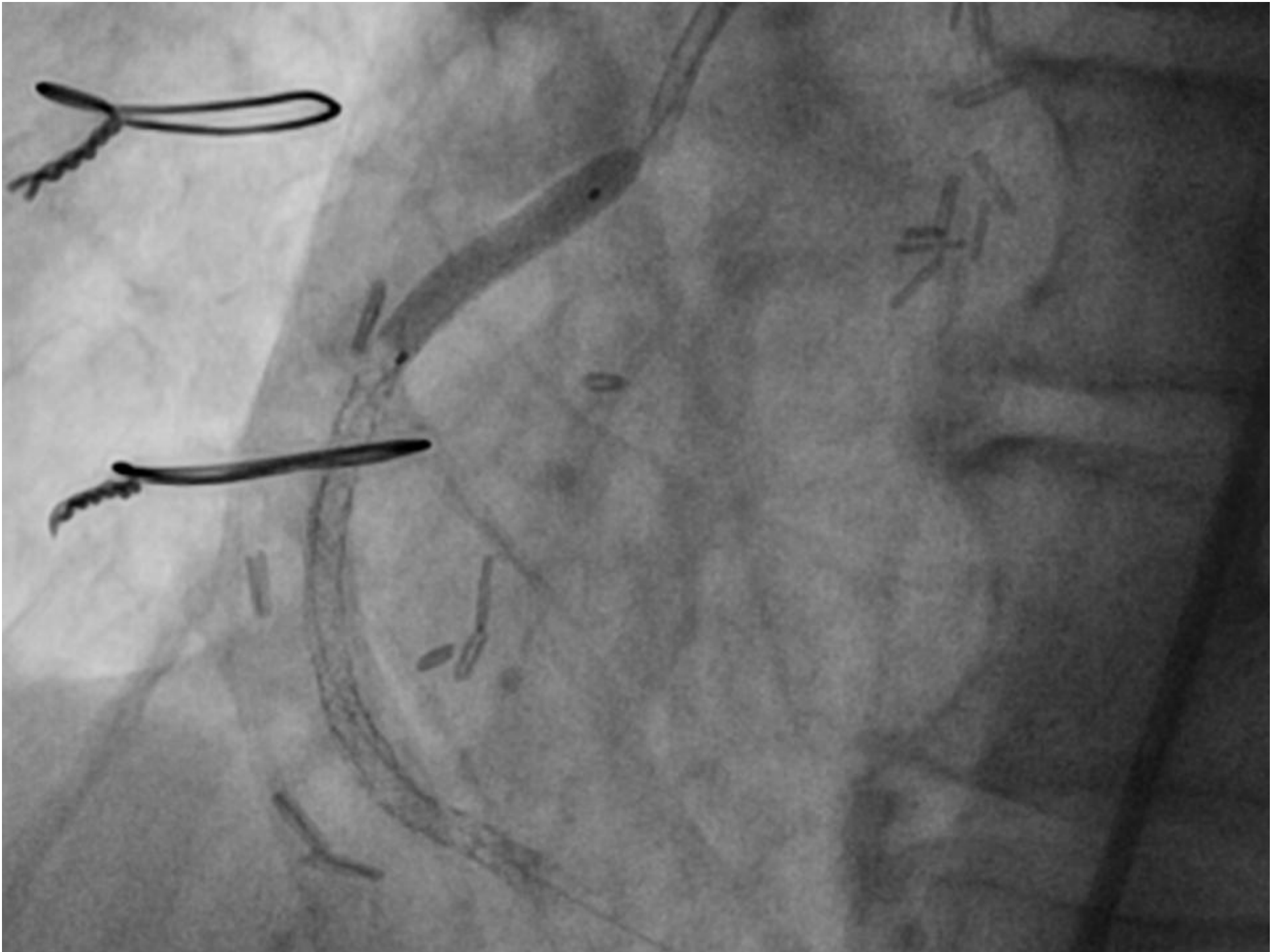


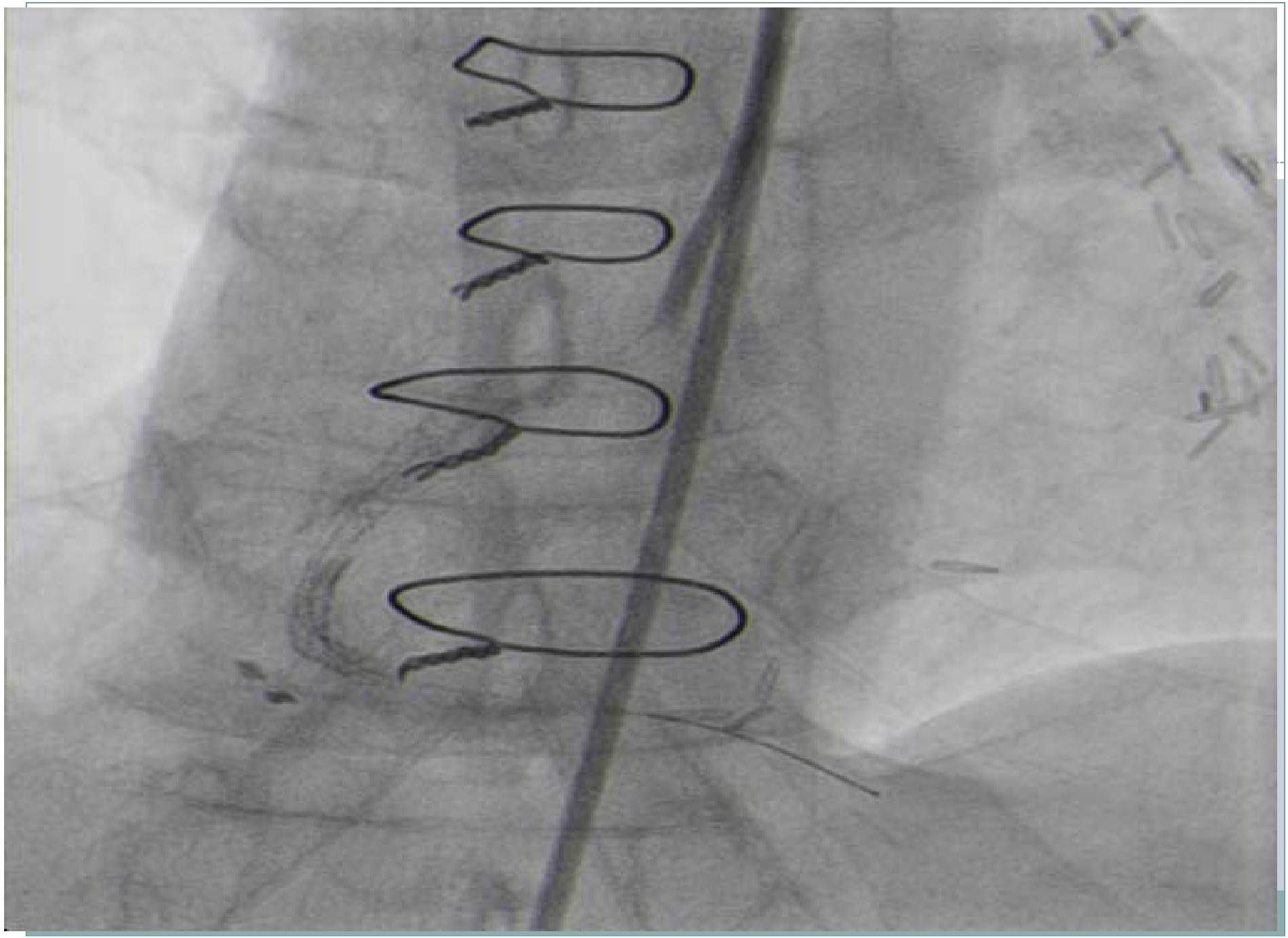




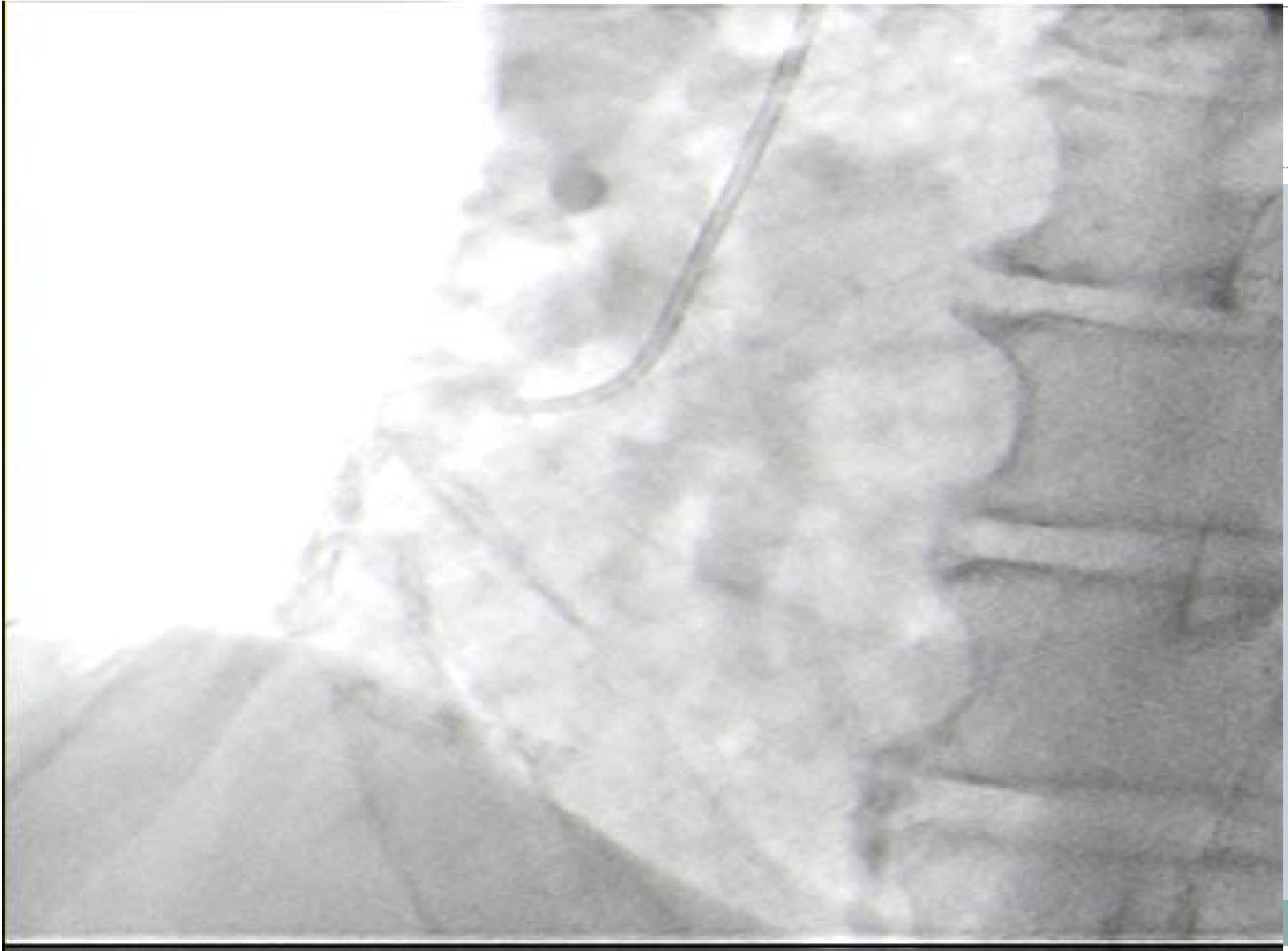








ROROR





TEŞEKKÜRLER...