

# CTO Olgu sunumu

Prof. Dr. Ömer Göktekin

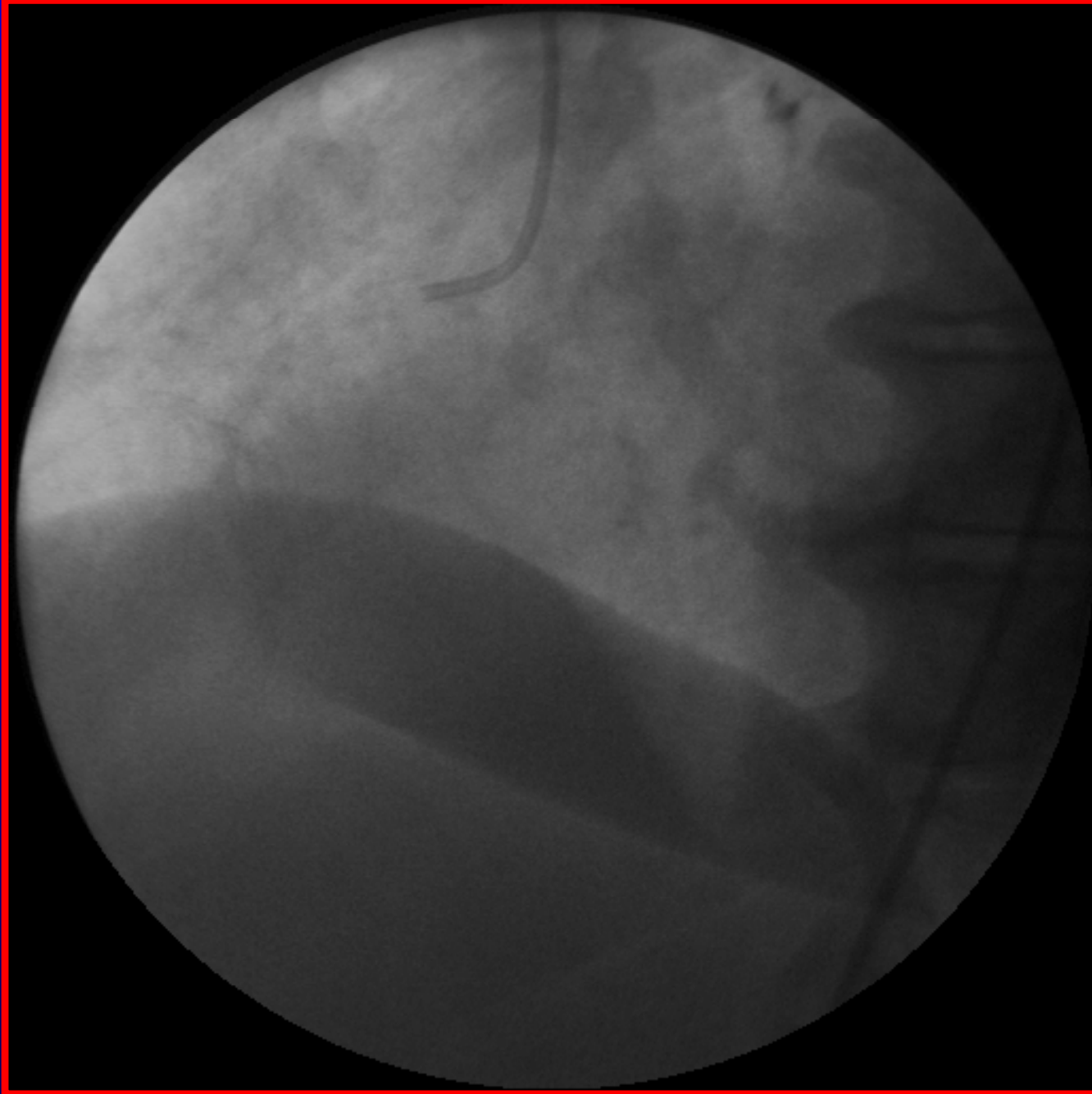
Bezmialem Vakıf Üniversitesi Tıp  
Fakültesi, İstanbul

Mehmet Akif Ersoy Kalp Damar  
Araştırma Merkezi, İstanbul

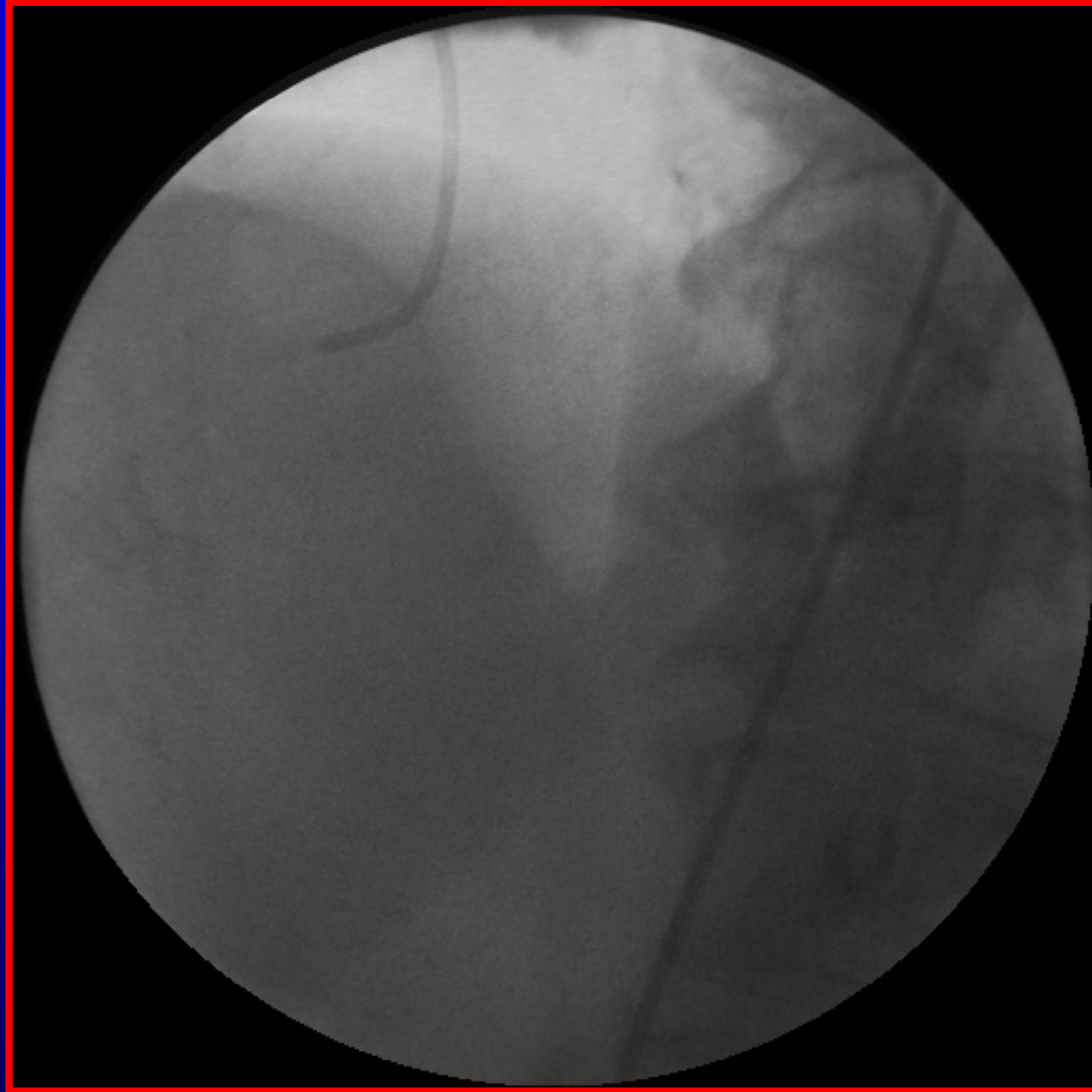
Kalp

- 71 YAŞINDA BAYAN HASTA
- 1 YILDIR FOR ANGINALARI
- DM + , HT + , HİPERLİPİDEMİ +
- EKO = LVEF =66 , LVH (+), MY (MİN), TY (MİN)
- DAHA ÖNCE İKİ AYRI MERKEZDE 3 KEZ RCA CTO DENENMİŞ
- İLAÇLARI = CONCOR , ASA , GLUKOFEN , NORVASC , AYRA PLUS

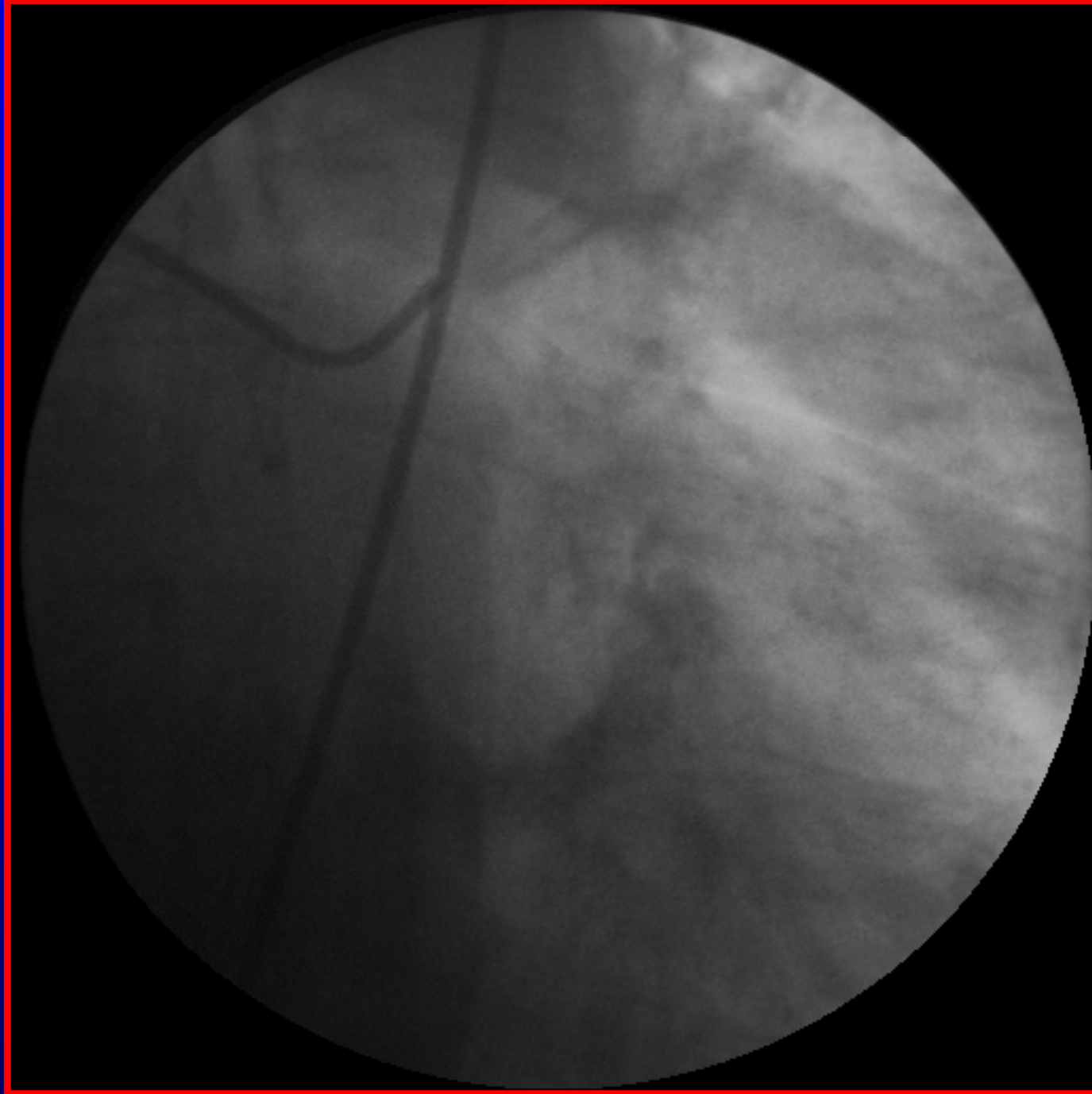
# İşlem öncesi



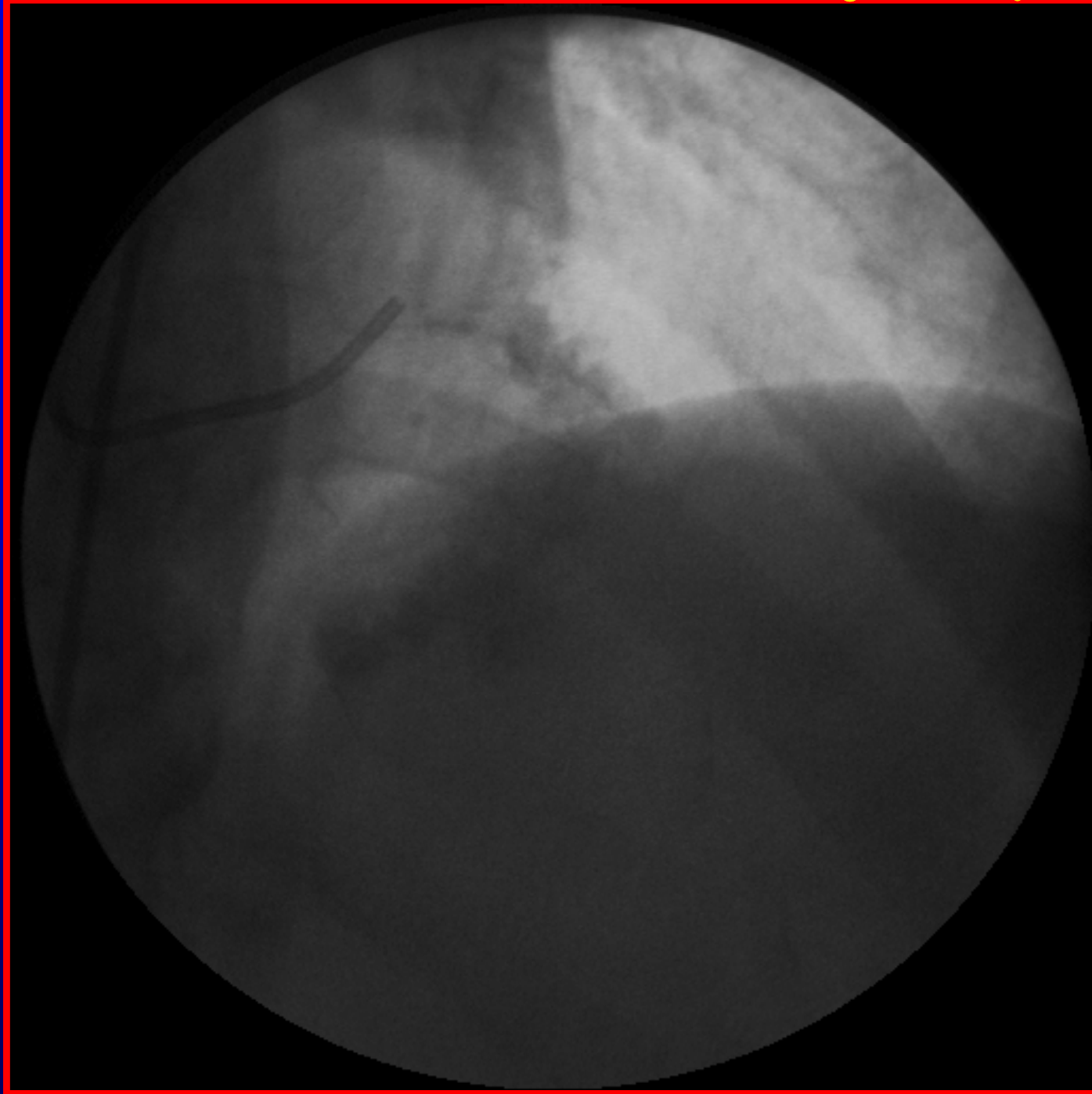# İşlem öncesi



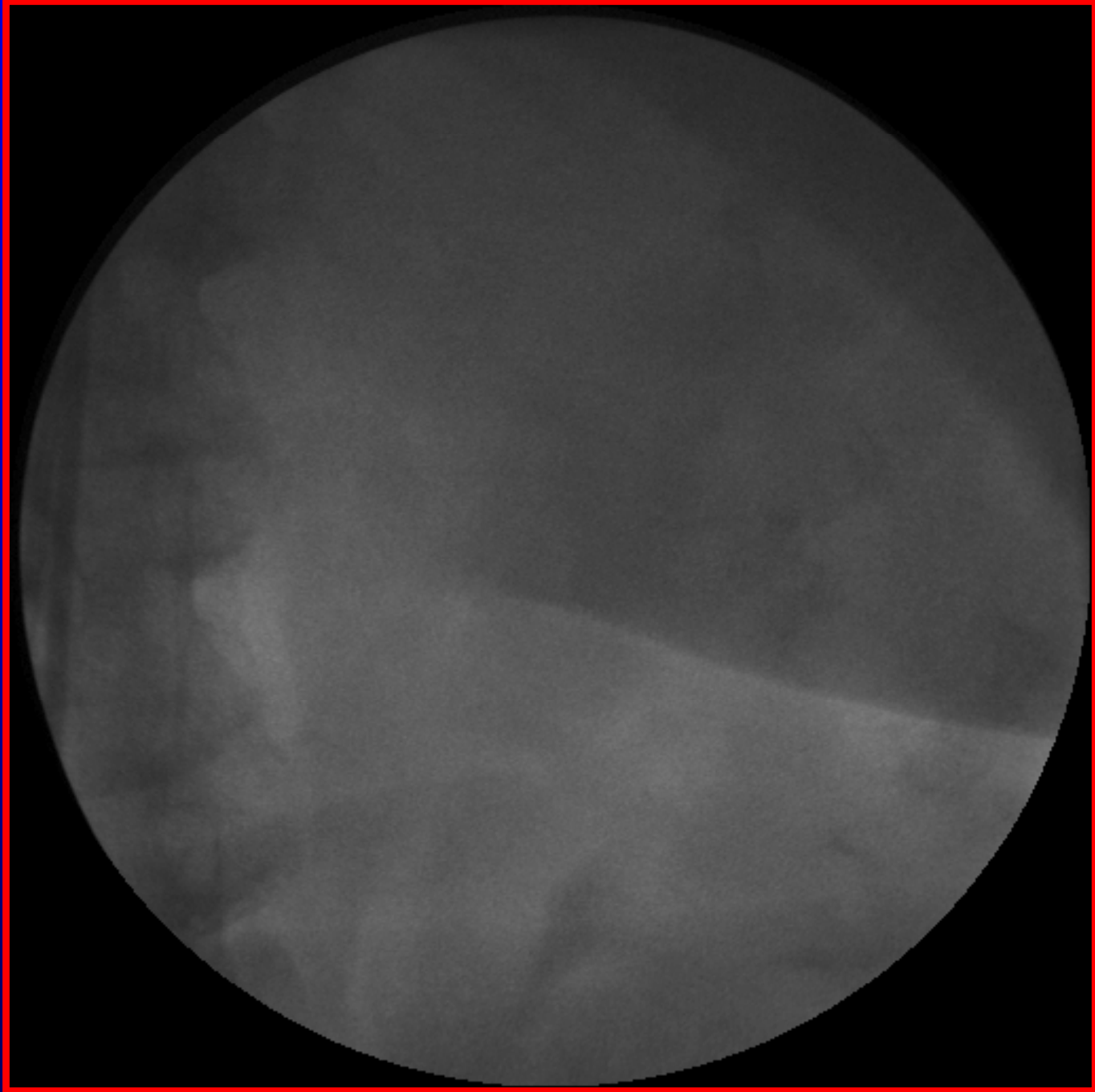
# İşlem öncesi sol koroner injeksiyonu



# İşlem öncesi sol koroner injeksiyonu

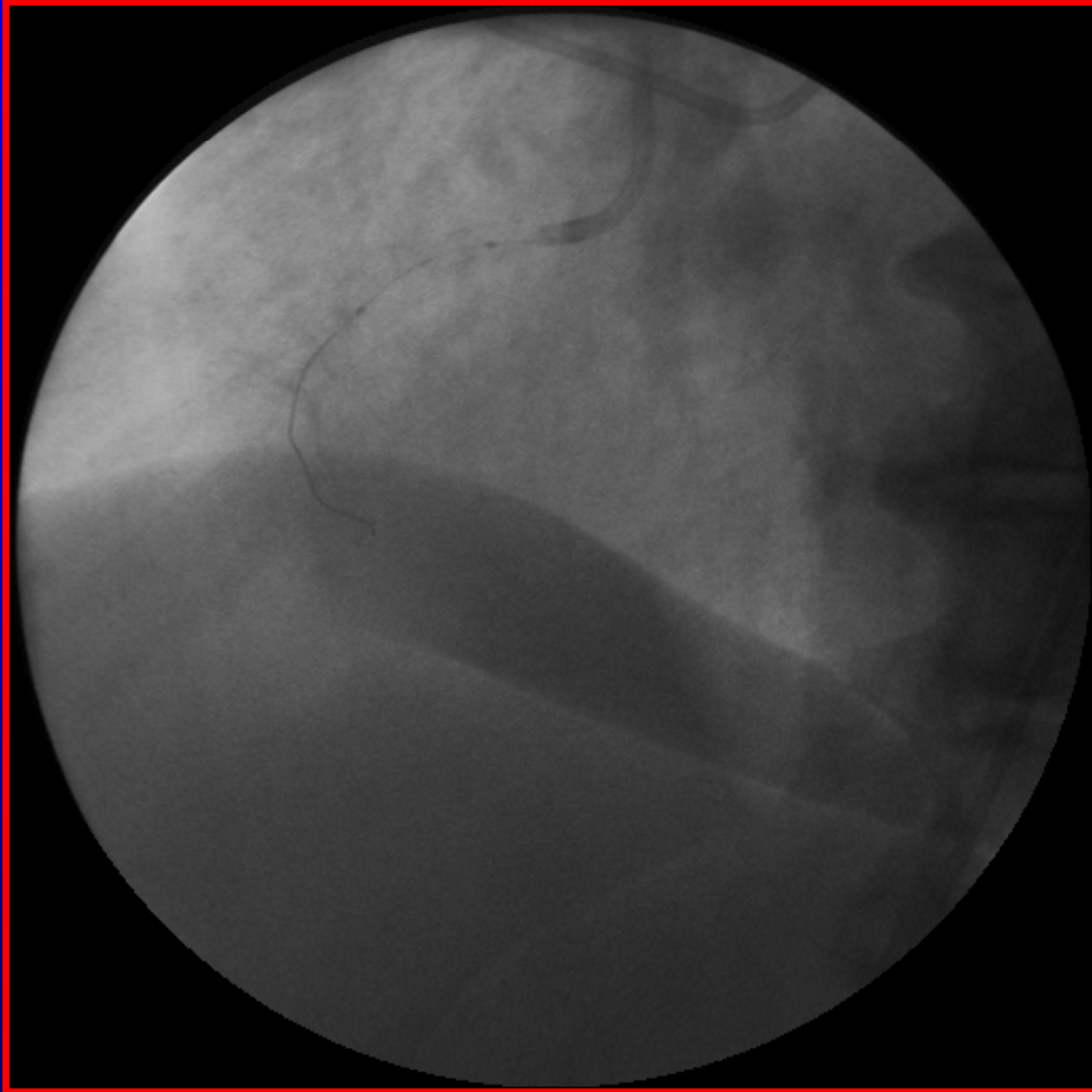


# İşlem öncesi bilateral injeksiyon

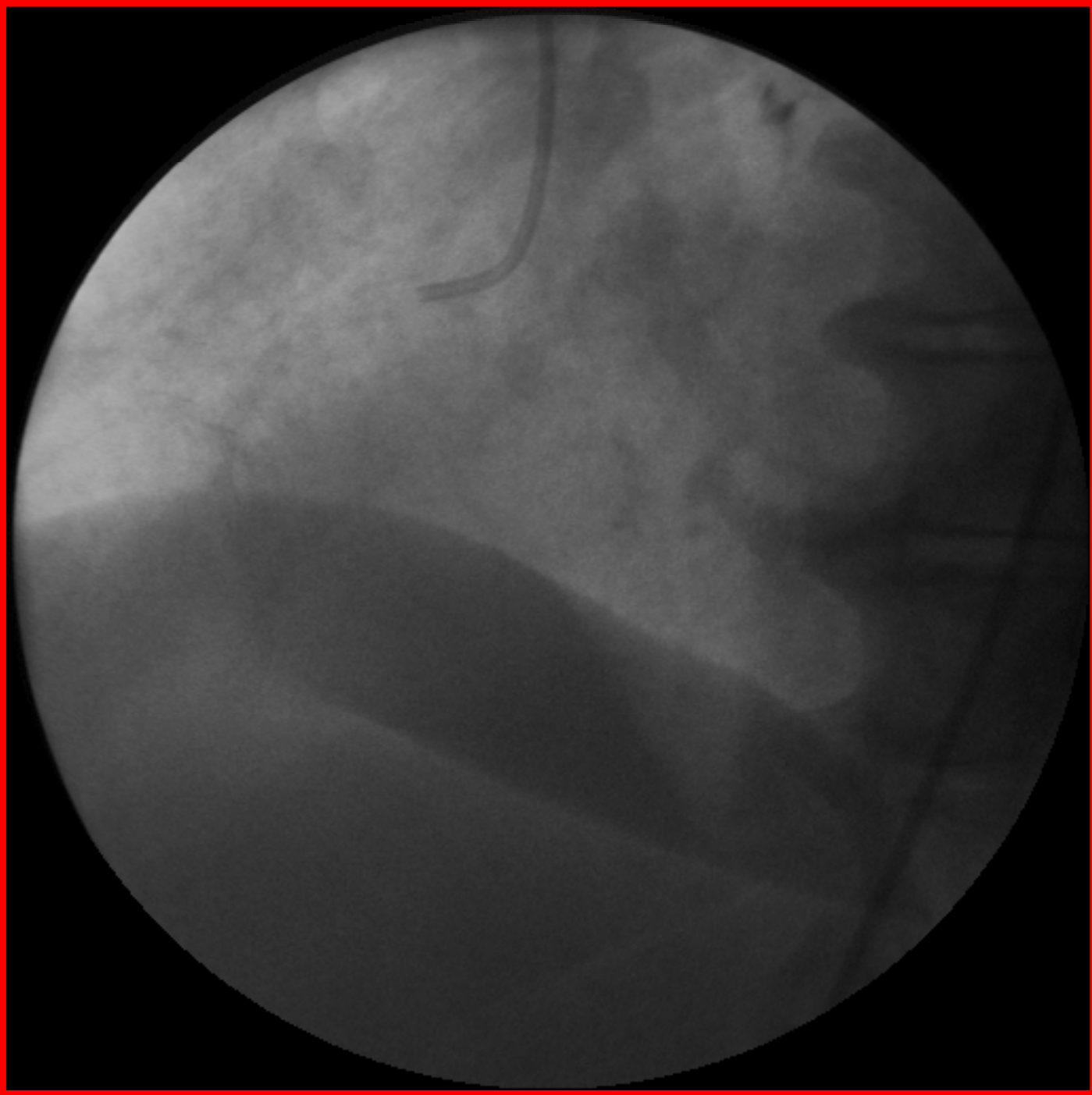


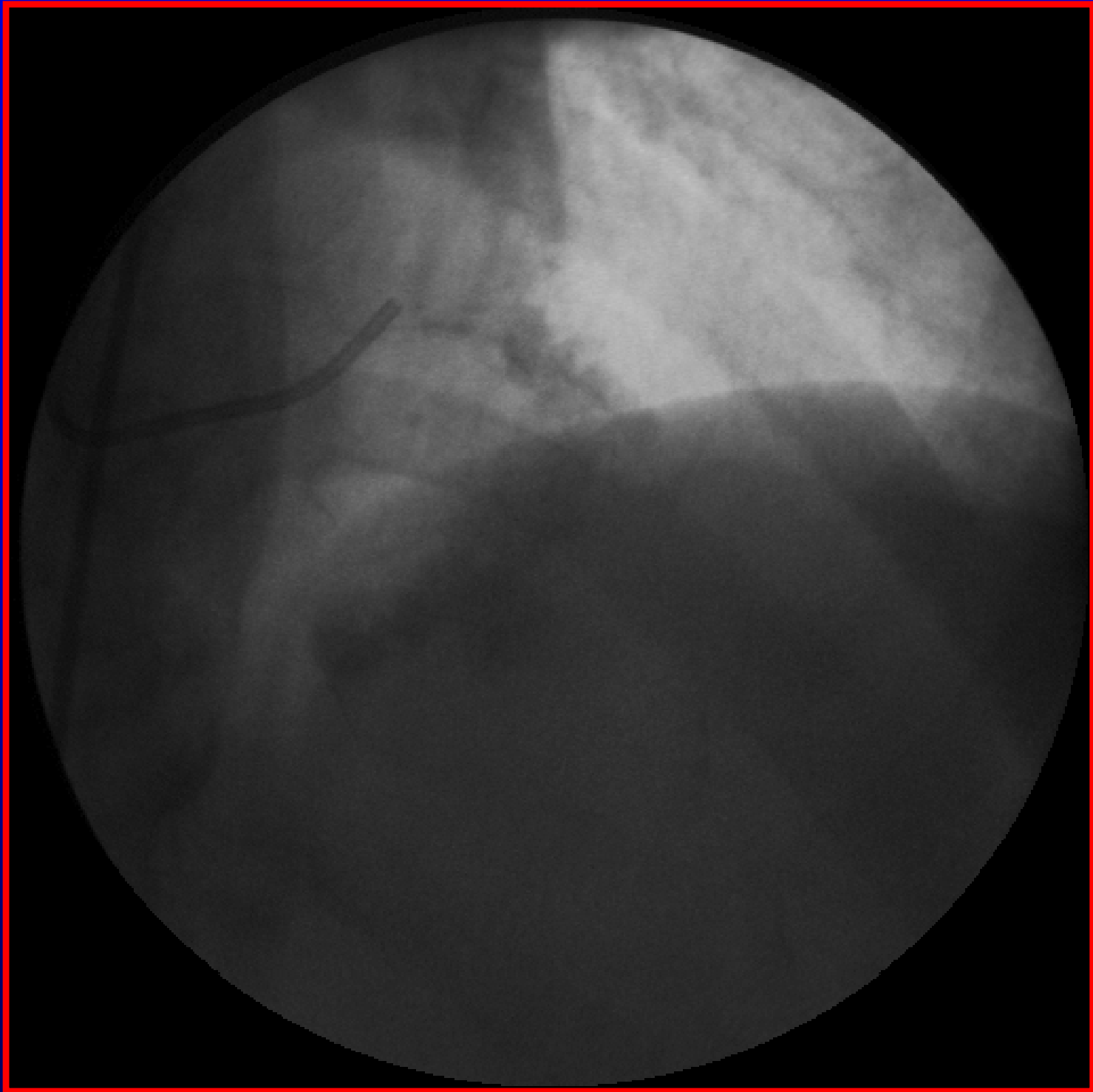

# Monorail balon destekli flopy tel

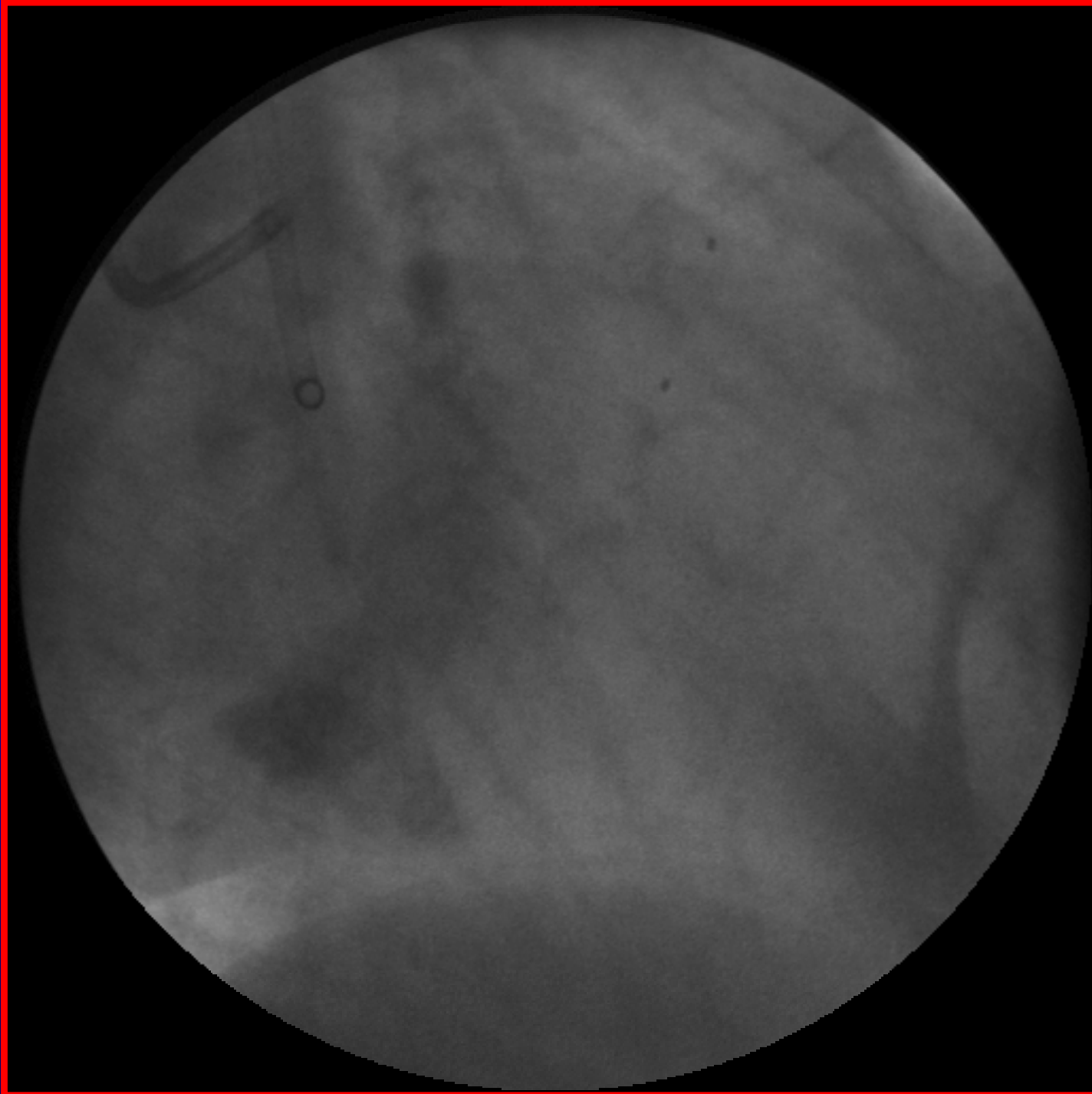




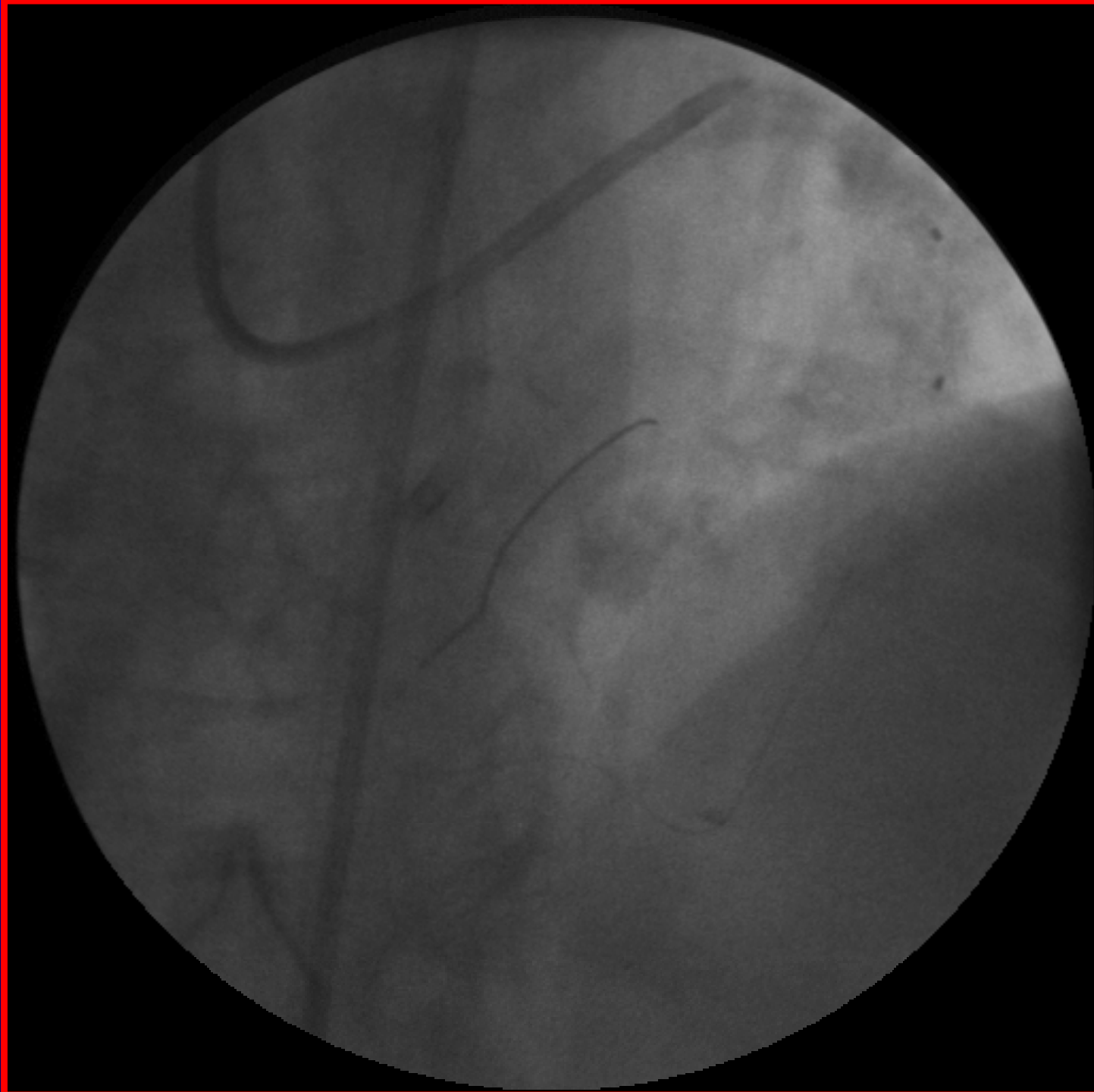




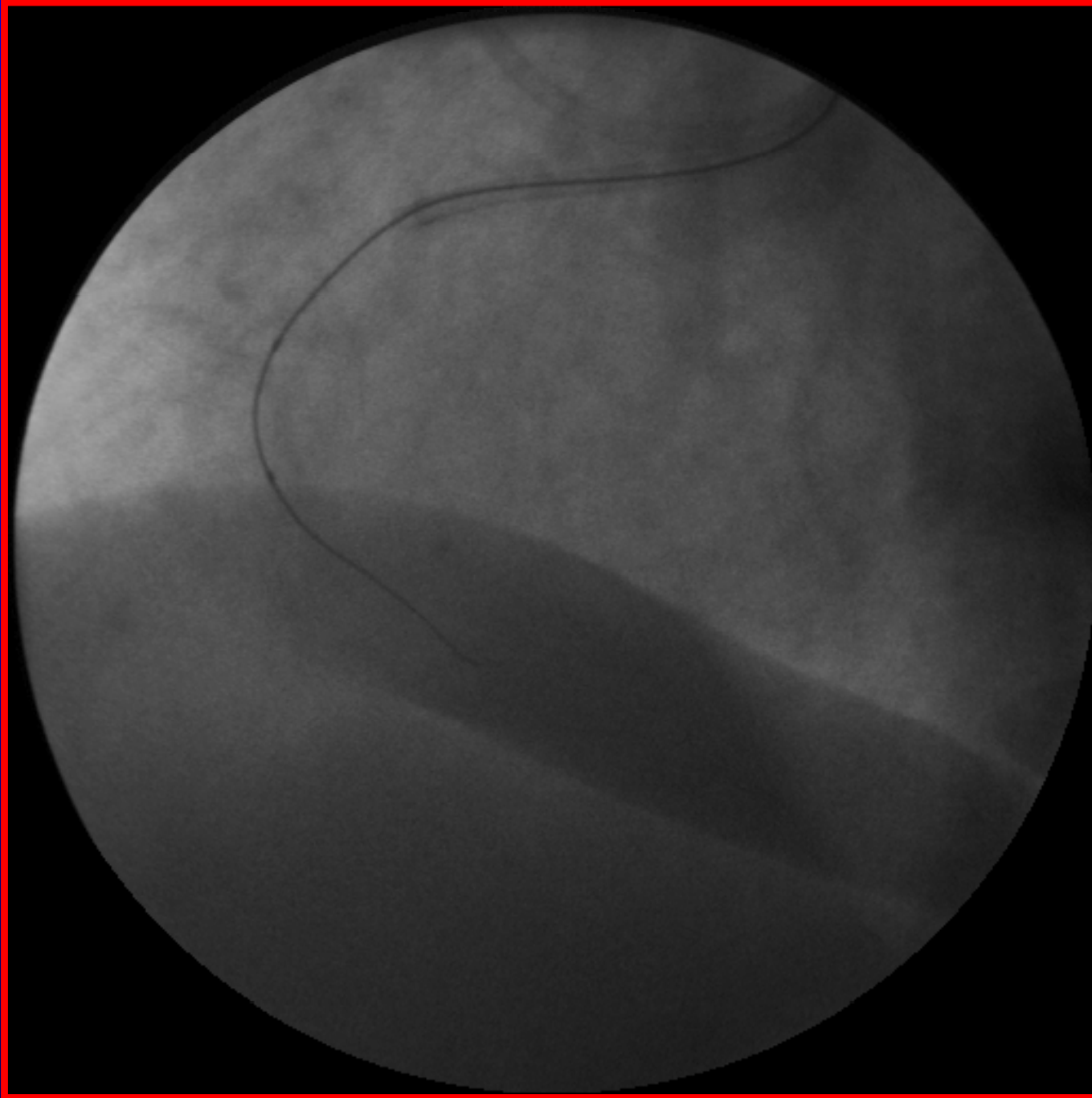
# Septal injeksiyon



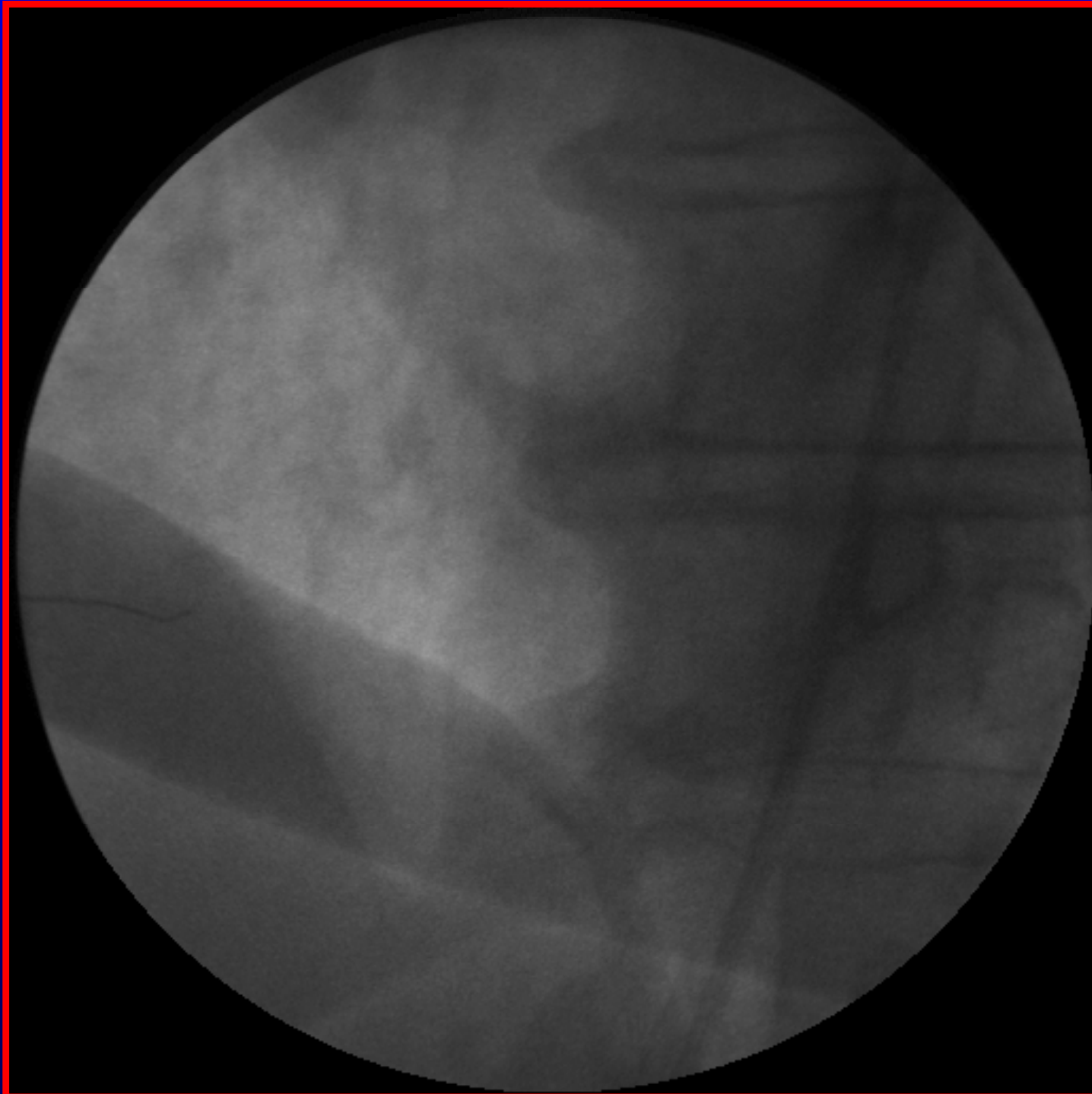
# Retrograd Fielder FC



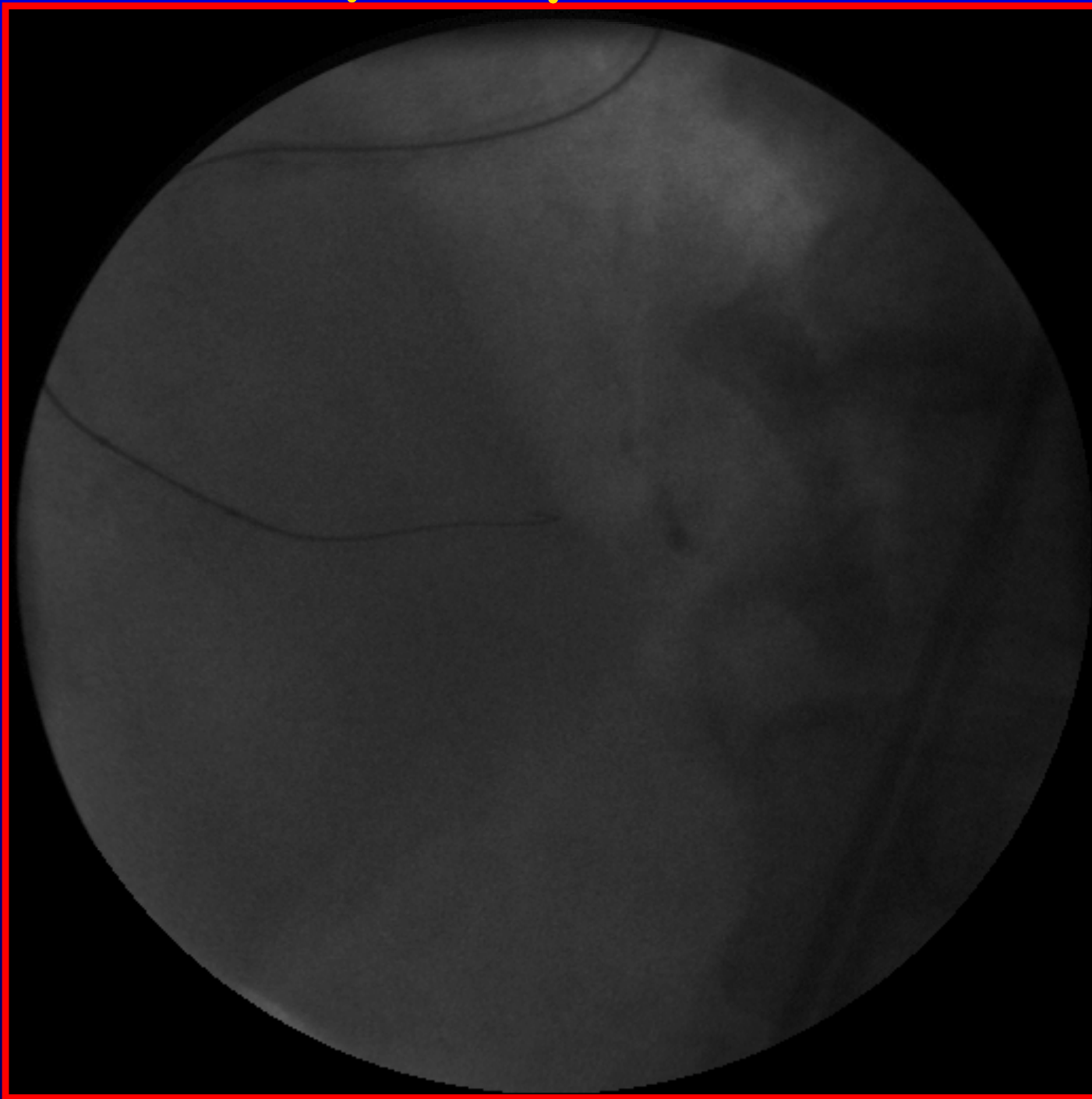# OTW balon, Fielder XT



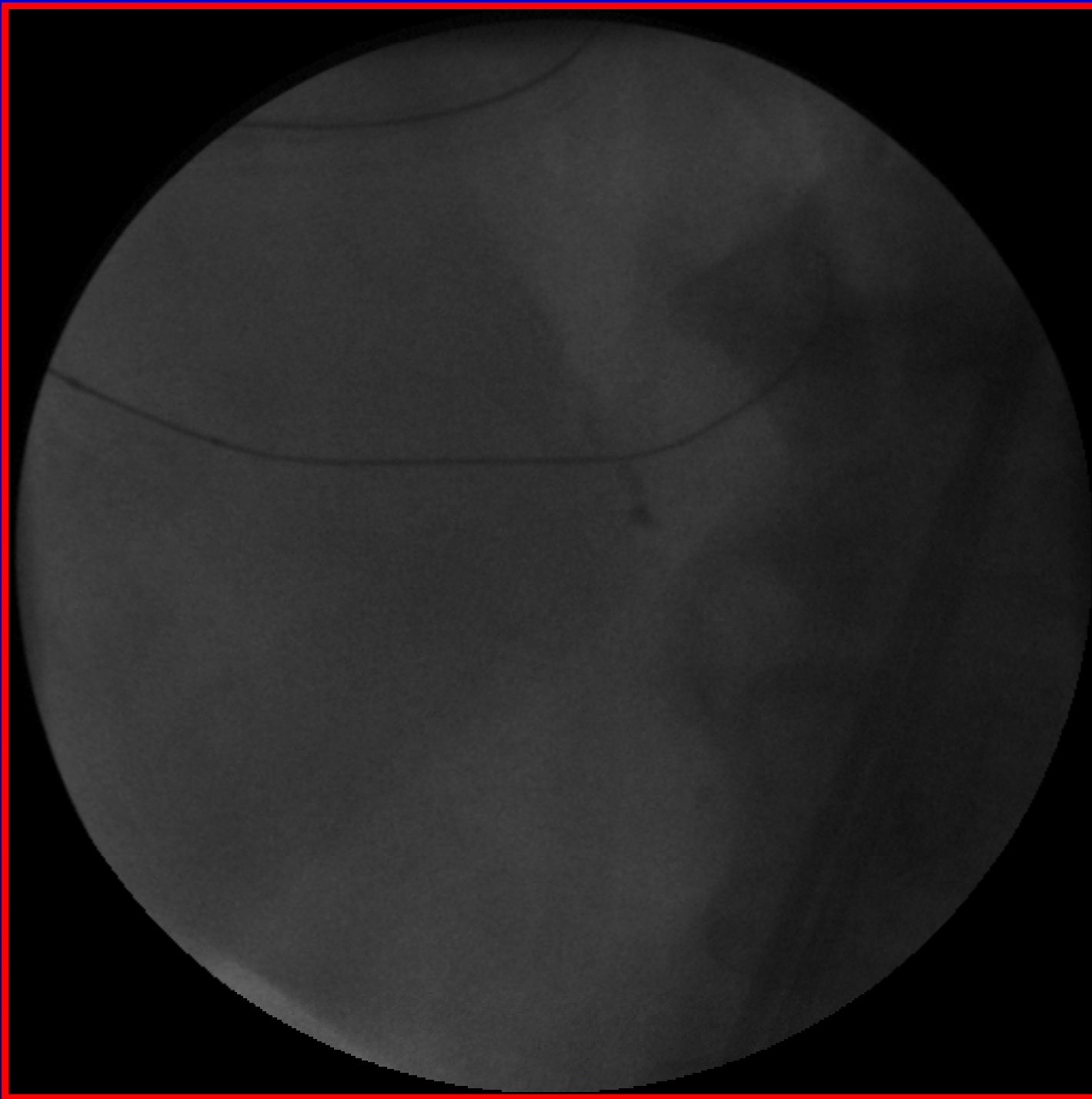
# Conquest pro 12

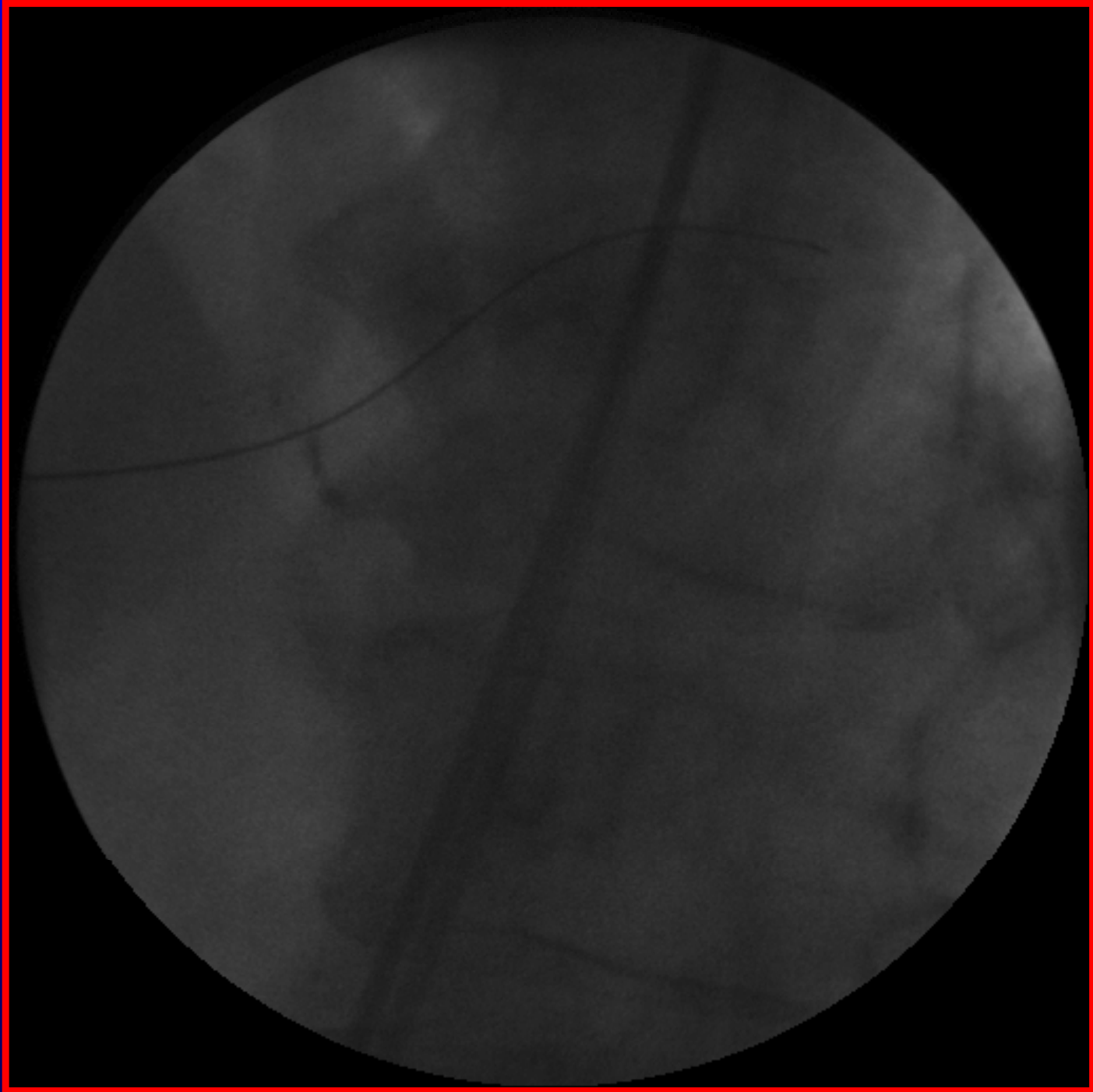

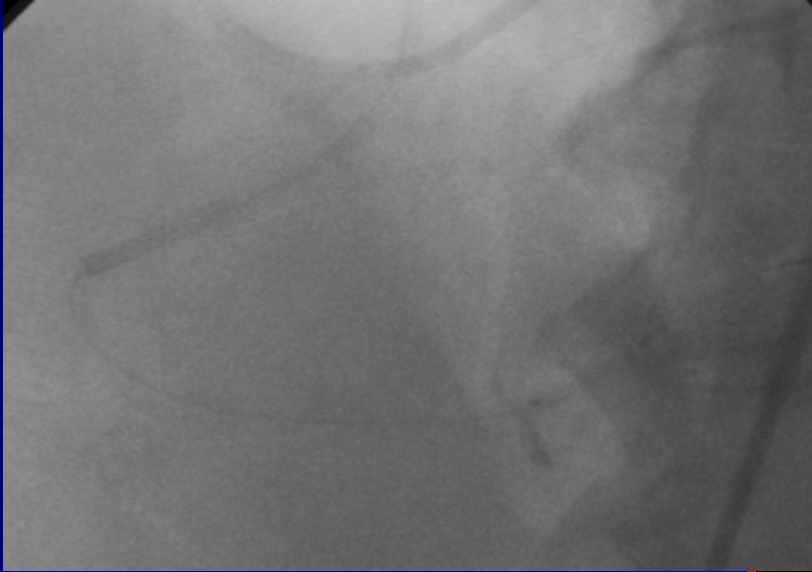
# Conquest pro 12



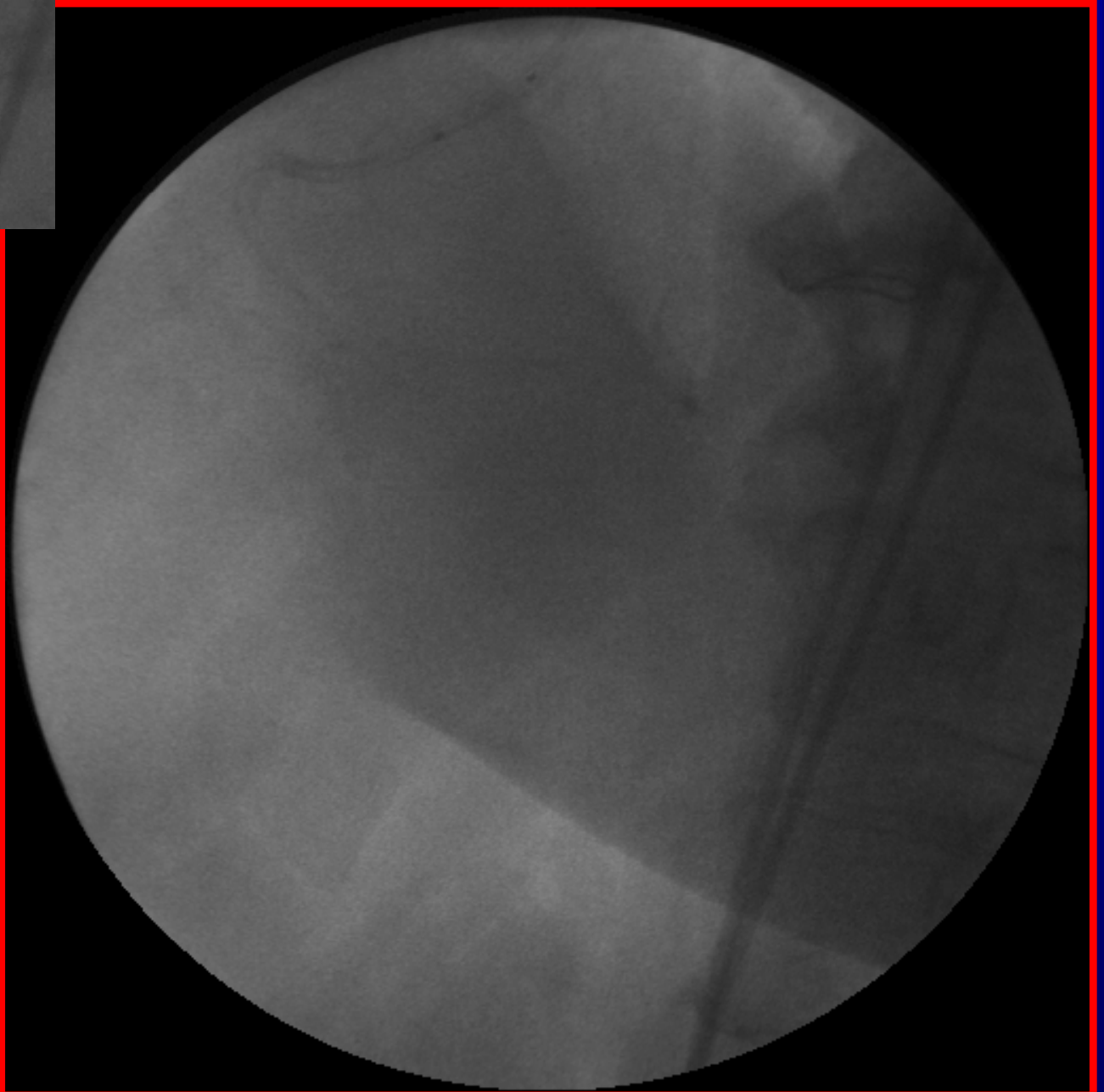


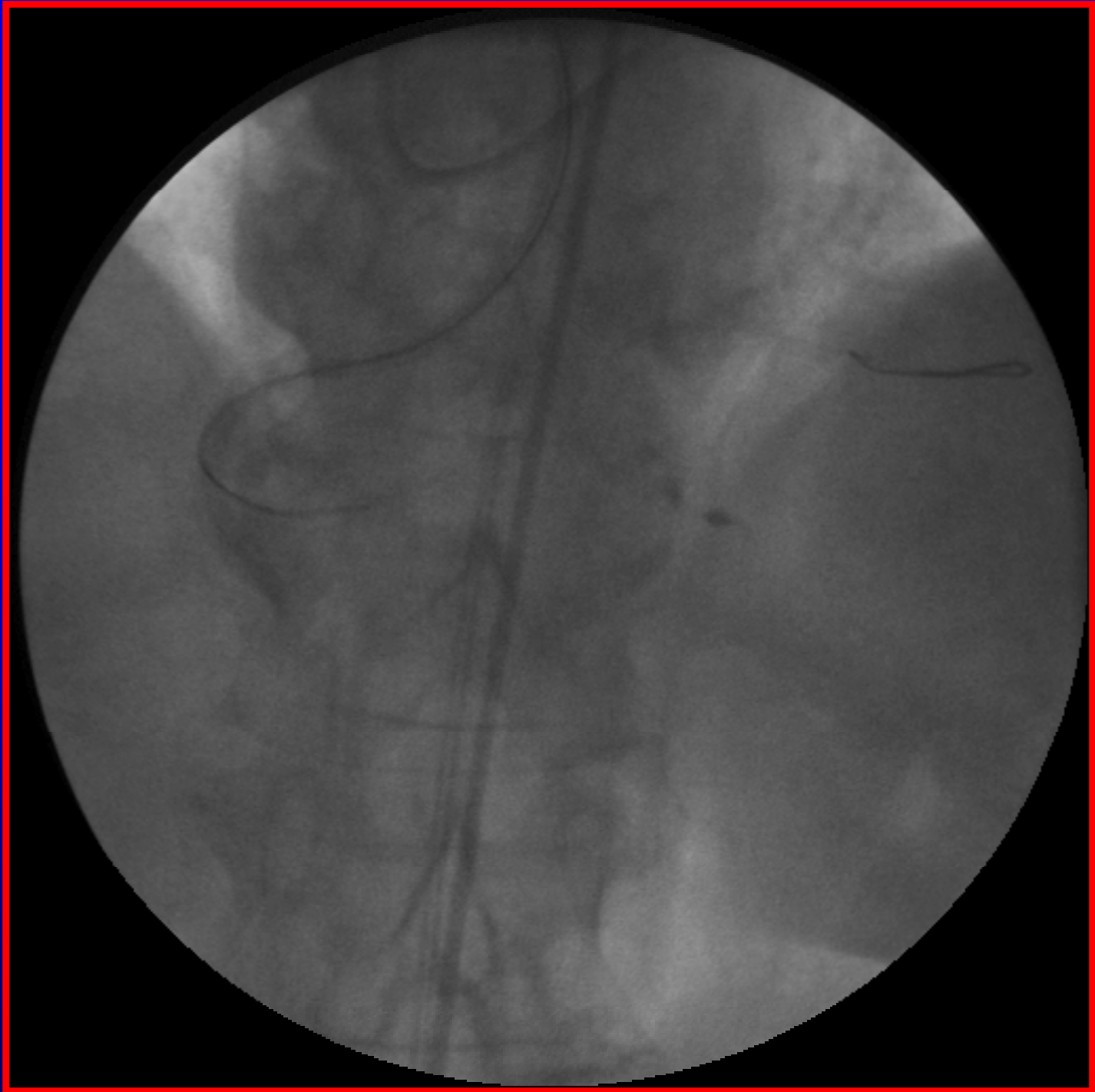


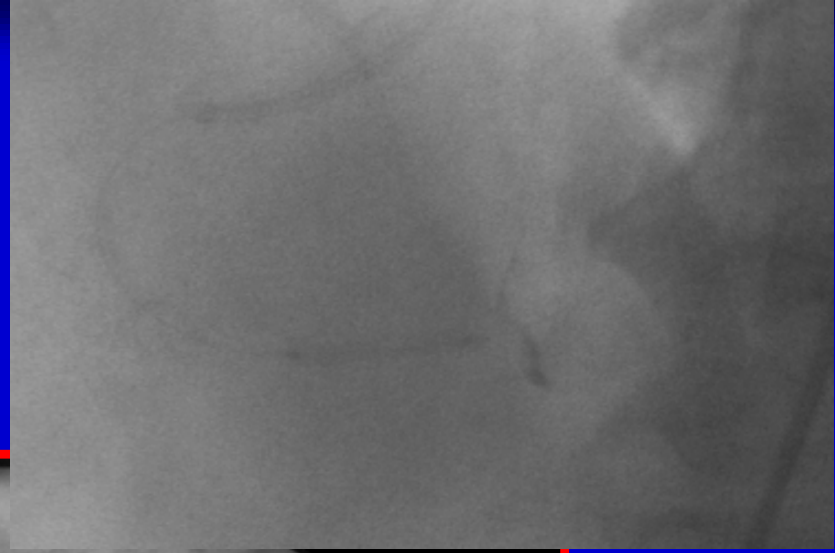
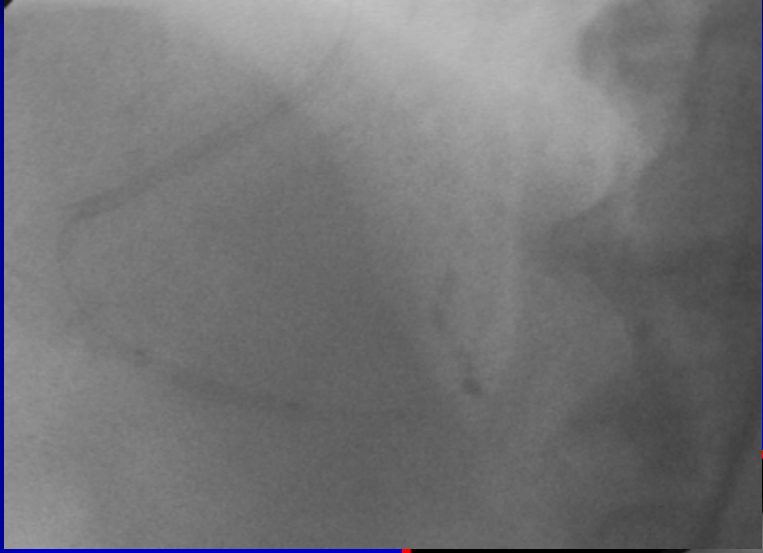



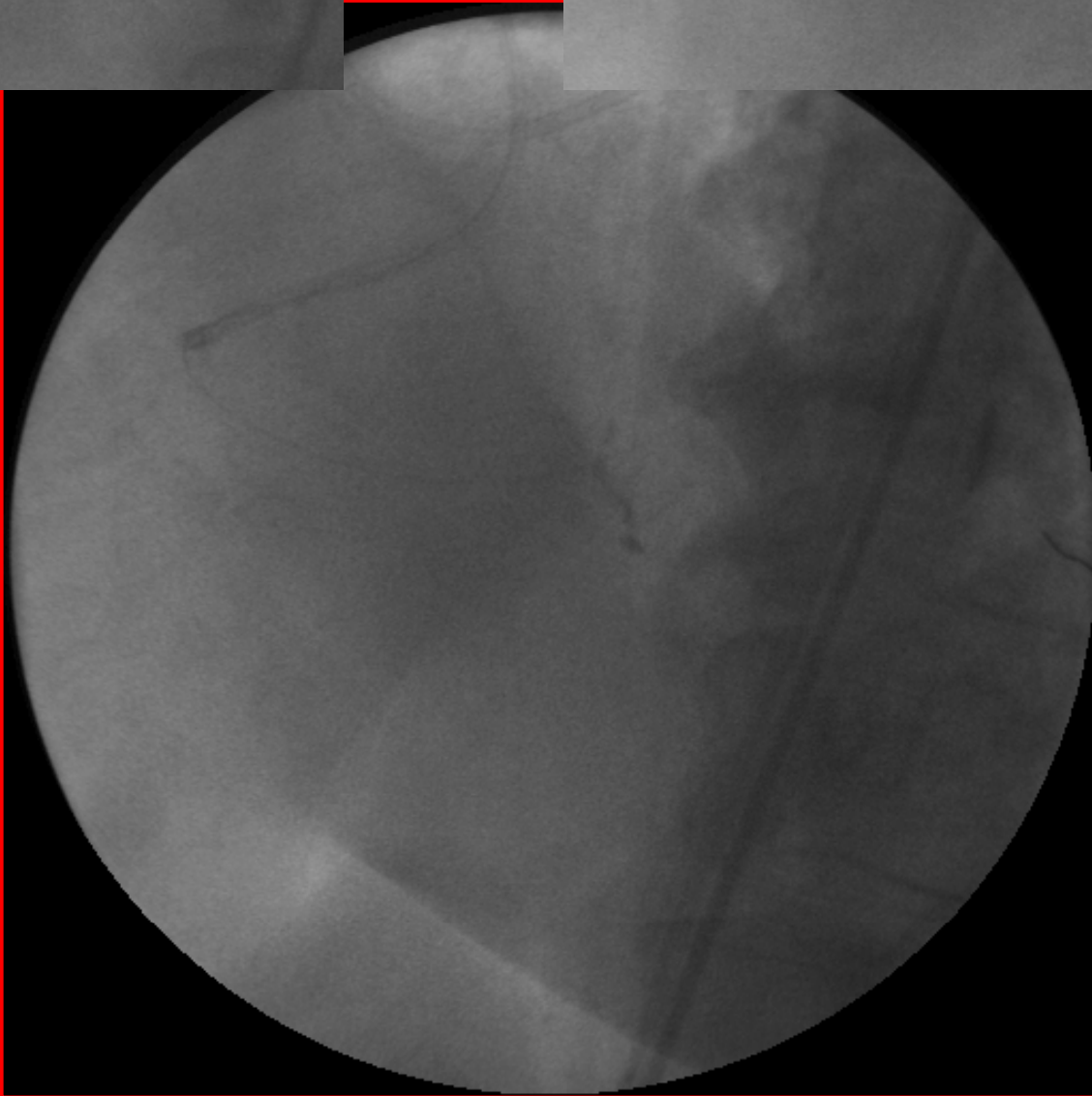
1.25 mm 14 Falcon OTW

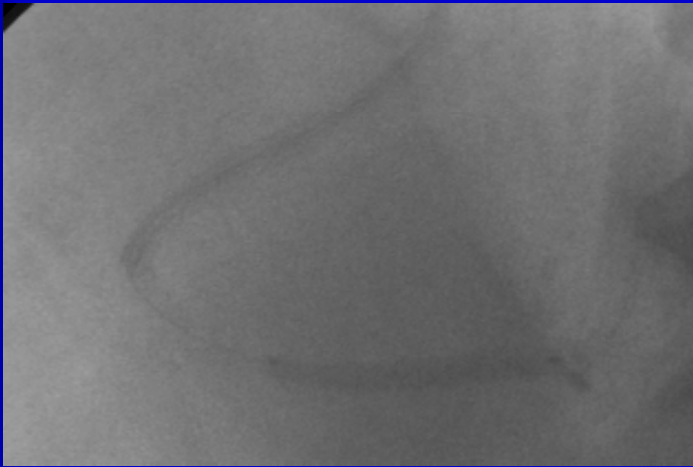




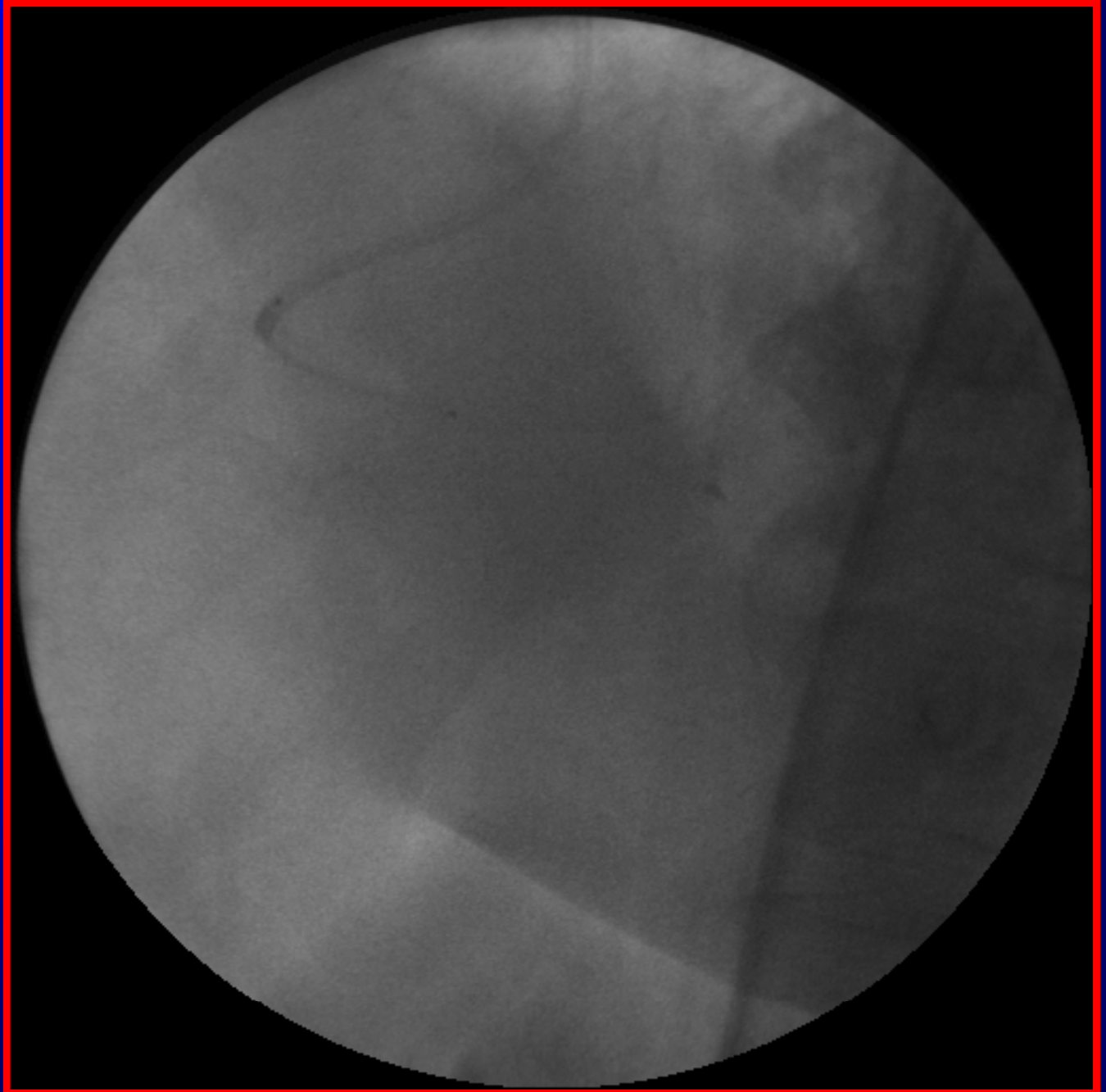


2.0X12 mm balon

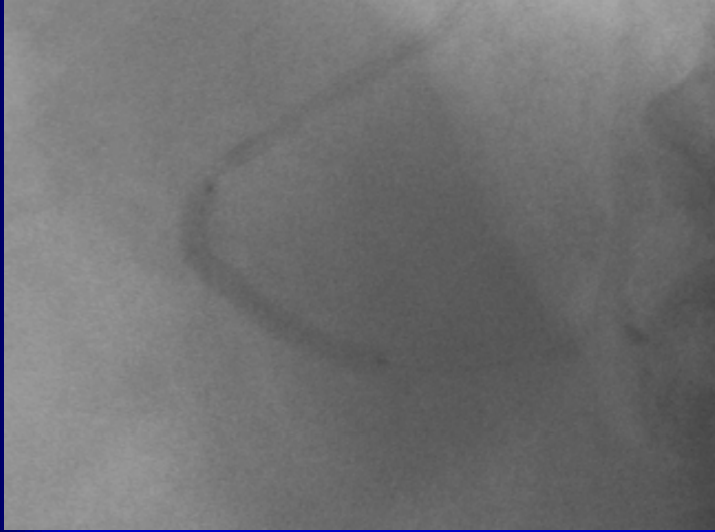




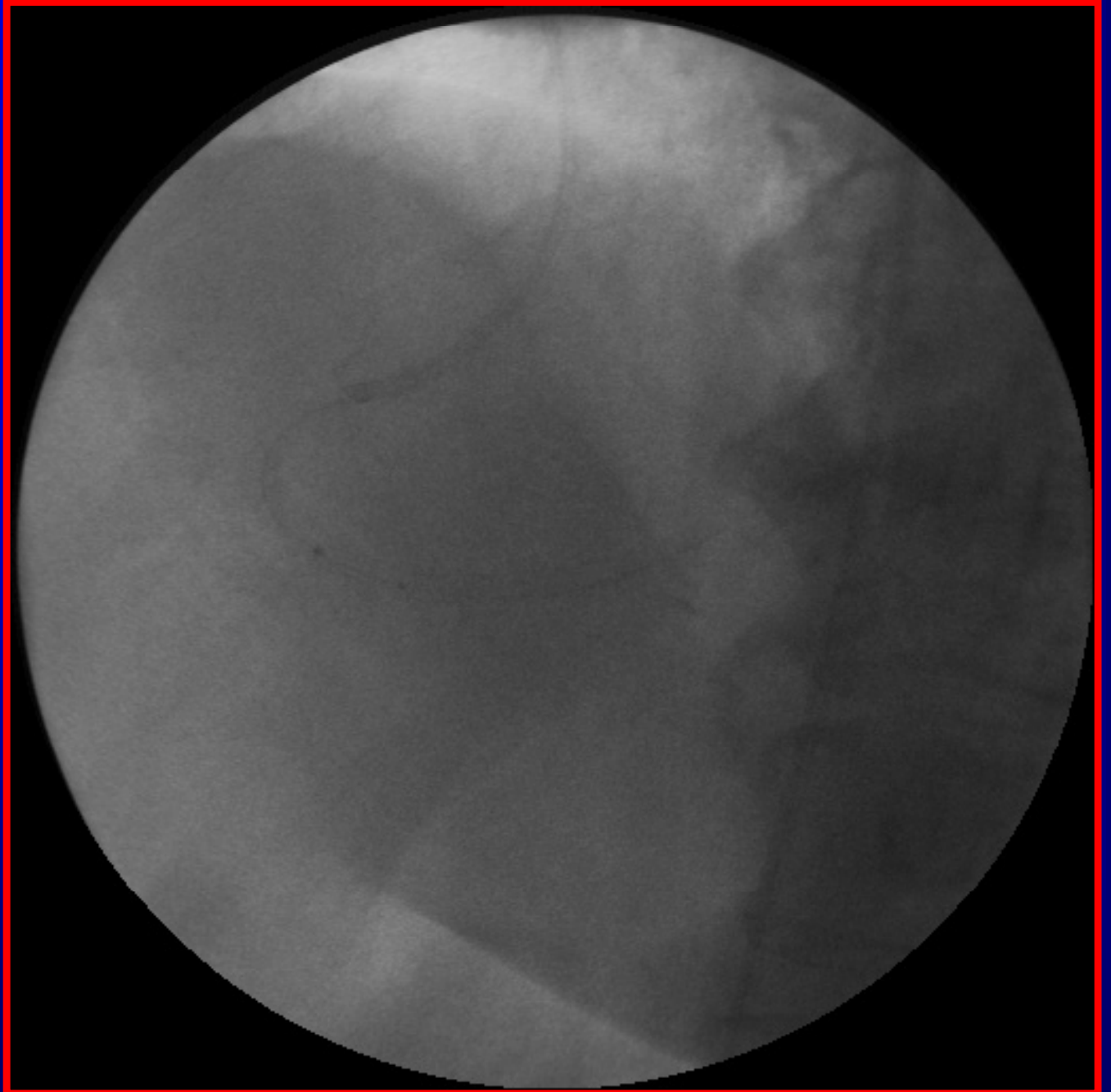**3.0X28 mm Biomatrix**



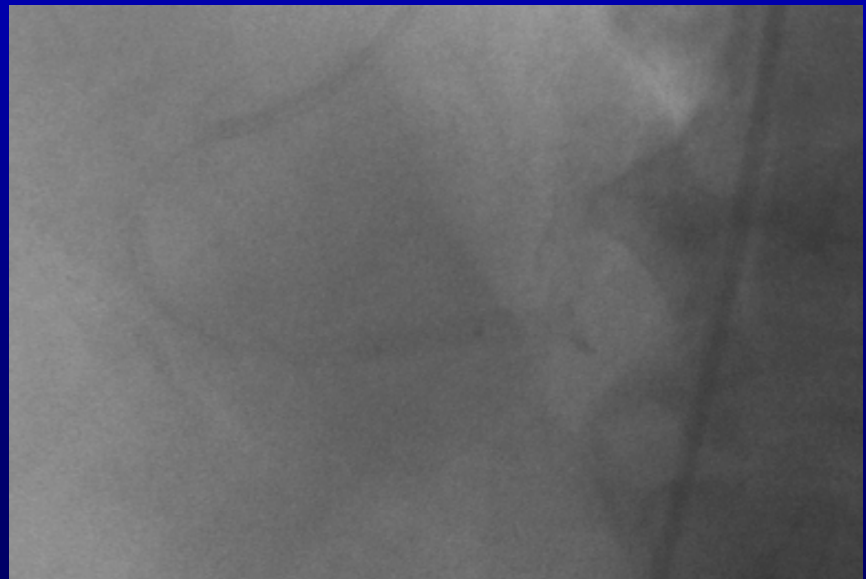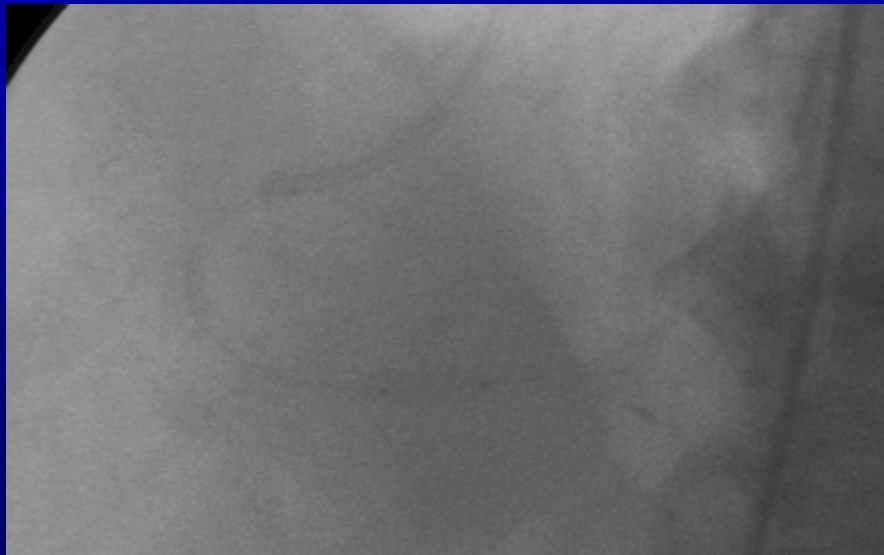
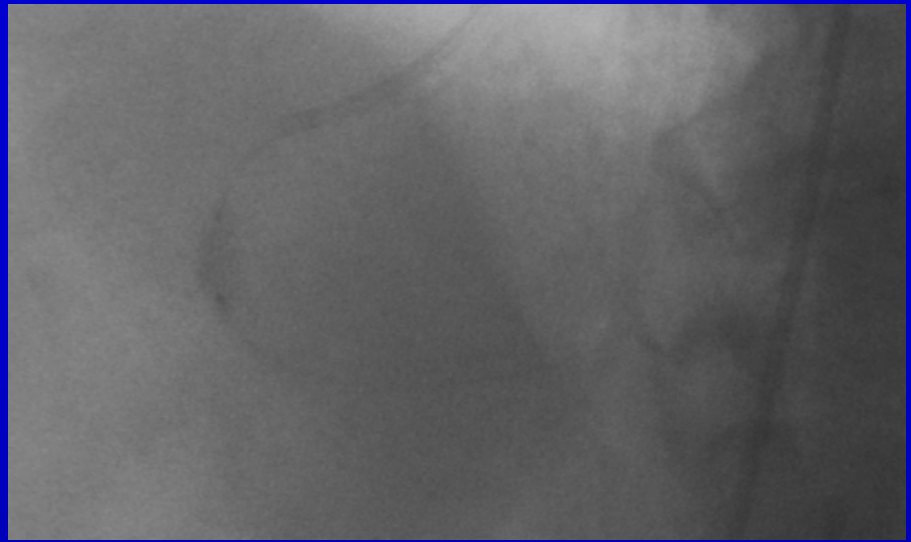
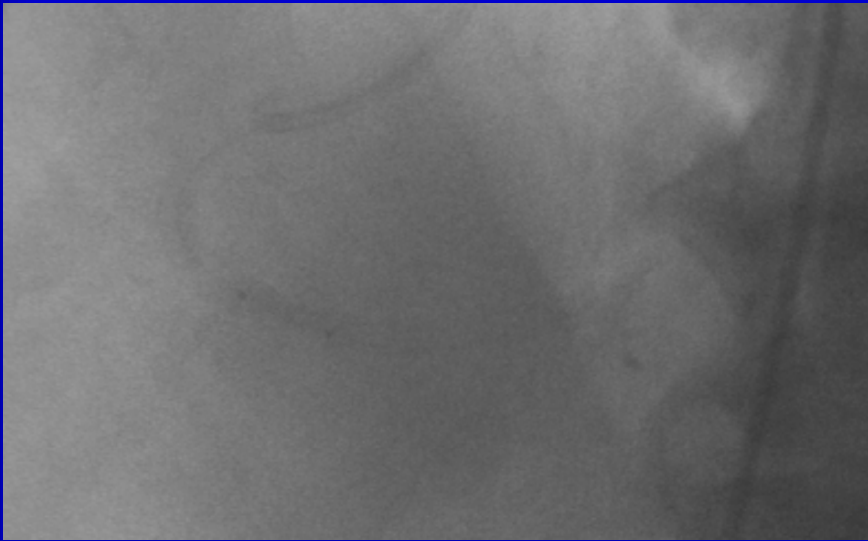




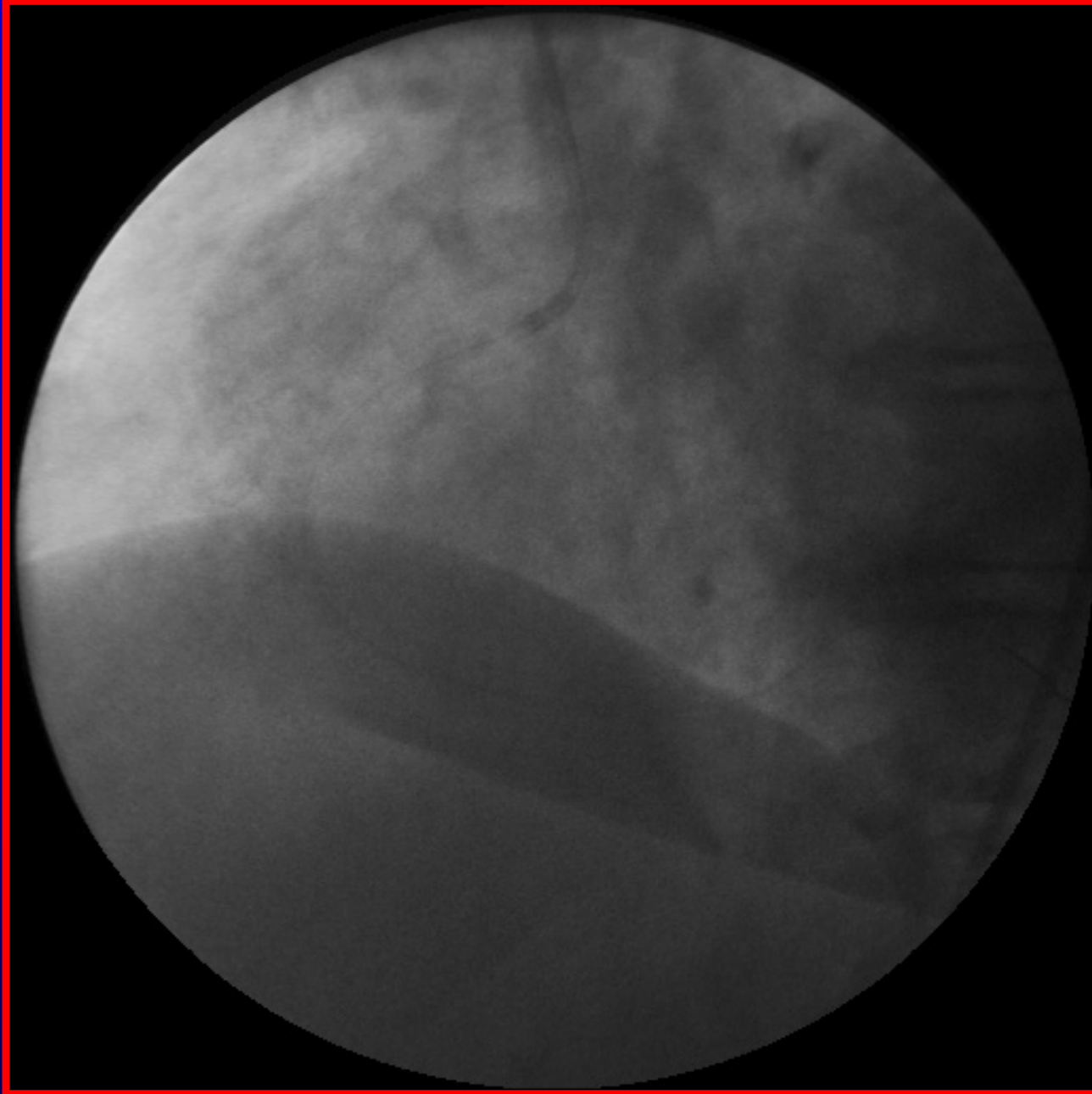
**3.0X36 mm Biomatrix**







İşlem sonu



**İşlem sonu**

